

OCT & OPTIC NERVE

Pr. Jean-Philippe Nordmann

Glaucoma Centre - Hôpital des Quinze-Vingts, Paris



Contents

Introduction	Page 13
Principles of OCT	Page 16
General principles	Page 18
What does OCT really show?	Page 20
Analysis methods of ocular structures with OCT	Page 22
- Optic nerve	Page 22
- Optical fibres around the papilla	Page 23
- Complex of macular ganglion cells	Page 24
Error sources with OCT	Page 26
- Signal receiving errors	Page 26
- Errors related to the positioning of the head	Page 26
- Errors related to the optics of the eye	Page 29
- Errors related to ghost images	Page 30
Presentation of the results in OCT	Page 32
Cirrus™ HD-OCT (Carl Zeiss)	Page 34
- Presentation “head of optic nerve and retinal nerve fibre analysis” (RNFL and ONH: Optic Disc Cube)	Page 34
- Presentation “Analysis of macular ganglion cells: Macular Cube”	Page 37
OCT Optovue (RTVue)	Page 38
- Presentation “Layer of parapapillary retinal nerve fibres and optic nerve”	Page 38
- General presentation “Macular ganglion cells and layer of retinal parapapillary nerve fibres”	Page 39
Glaucoma	Page 40
The three structures to be analysed by OCT in glaucoma	Page 42
- Optic nerve	Page 42
- Retinal nerve fibres (RNFL)	Page 42
- Complex of macular ganglion cells	Page 44
- Optic nerve or retinal nerve fibres: that look first in glaucoma?	Page 45
- What if there is an isolated optic nerve damage?	Page 46
Preperimetric glaucoma	Page 48
- Preperimetric glaucoma: impairment isolated from the OCT	Page 48
- Preperimetric glaucoma: impairment of the RNFL layer and the FDT Matrix visual field	Page 50
- Preperimetric glaucoma: impairment of the RNFL layer, macula and the FDT Matrix visual field	Page 52
- Preperimetric glaucoma: impairment of the FDT Matrix, OCT at the limit of normal	Page 54

Early open-angle glaucoma	Page 56
- Glaucoma with incipient open angle: location of the impairment matches between OCT and the visual field	Page 56
- Early open-angle glaucoma: depth of the impairment matches between OCT and the visual field	Page 58
- Early open-angle glaucoma: primary impairment in the OCT	Page 60
- Early open-angle glaucoma: primary impairment of the optic nerve without impairment in the optical fibres	Page 62
- Early open-angle glaucoma: comparison between OCT “Time Domain” and “Spectral Domain”	Page 64
Moderate open-angle glaucoma moderate	Page 66
- Glaucoma with moderate open angle: impairment matches in the OCT and the visual field	Page 66
- Moderate open-angle glaucoma: primary disease in the OCT	Page 68
Advanced open-angle glaucoma	Page 70
- Glaucoma with advanced open angle: impairment matches in the OCT and the visual field	Page 70
- Advanced open-angle glaucoma: primary impairment in the visual field	Page 72
- Advanced open-angle glaucoma: impairment does not match between OCT and the visual field	Page 74
Normal pressure glaucoma	Page 76
- Normal-pressure glaucoma: isolated fascicular deficit	Page 76
- Early normal pressure glaucoma	Page 78
- Moderate normal pressure glaucoma	Page 80
Angle-closure glaucoma or sequelae of acute hypertension	Page 82
Follow-up of open-angle glaucoma	Page 84
- Can OCT improve in glaucoma?	Page 87
- Comparison between “Spectral Domain” OCTs in glaucoma	Page 87
- OCT and analysis of the cribriform lamina	Page 87
Non-glaucomatous optic neuropathies	Page 88
Multiple sclerosis	Page 91
- Acute neuropathy and MS	Page 91
- Correlation between OCT and visual field in MS	Page 92
- Location of impairment by OCT in MS	Page 93
- Major sequela of neuropathy in MS	Page 94
- Can we detect subclinical MS neuropathy through OCT?	Page 96
Acute optic neuropathy unrelated to MS	Page 98
Toxic optic neuropathy	Page 100
- Toxic optic neuropathy without apparent papillary impairment	Page 100
- Toxic optic neuropathy with papillary and macular impairment	Page 102
Anterior ischemic neuropathy	Page 104

Optic neuropathy and uveo-papillitis	Page 106
Papillary oedema	Page 107
- Isolated oedema of the papilla without retinal diffusion	Page 108
- Oedema of the optic disc with subretinal oedema	Page 110
Compression of the optic nerve	Page 112
Chiasma impairment	Page 114
Amblyopia	Page 116
Perinatal impairment of the central nervous system	Page 118
Impairment of the central nervous system in adults	Page 120
Determination of the organic character of visual impairment	Page 122
Non ophthalmological neurodegenerative pathologies	Page 124
Atypical appearances of the optic nerve that may show optic neuropathy in OCT	Page 126
Myopia	Page 128
Dysversion the optic disc	Page 130
Physiological excavation	Page 132
Papillary coloboma	Page 134
Atypical appearances of the retina that may show optic neuropathy in OCT	Page 136
Vein occlusion sequelae	Page 138
Pigmentary retinopathy	Page 140
Conclusion	Page 143
References	Page 145

OCT (Optical Coherence Tomography) is a relatively new technique that allows images of biological tissue to be obtained by measuring the reflection of light from the structure in question. Depending on the wavelength used, the discernible details are in the range of 1 to 15 μm , i.e. at least twice as thin as is possible with the highest-performance conventional methods such as MRI or high-resolution ultrasound echography. Its main limitation is the need to analyse structures allowing sufficient light to pass through to obtain a reflected image.

The eye is clearly an “ideal” organ in this sense, because a very large number of ocular structures are mainly or partially transparent: cornea, lens, vitreous humour, neurosensory retina, as well as the front layers of the iris. Other highly reflective surface structures such as the pigment epithelium of the retina can be studied.

In 10 years, OCT has developed a key role in the diagnosis and follow-up of retinal and particularly macular impairments. This is due to the very descriptive nature of OCT images that seem to reproduce an almost histological appearance of the lesions observed. The latest generations of OCT, by multiplying the measurements, can not only reproduce this descriptive aspect, but can also perform a quantitative analysis of structures: thickness of the retina and each of its components such as the ganglion cell layer, analysis of the neuroretinal rim, etc.

Retinal imaging by OCT has thus emerged as a crucial element for the analysis of glaucomatous disease, since it is now possible to quantify the thickness of the nerve fibre layer (called either optical fibre layer or retinal nerve fibre layer, RNFL), a structure that is predominantly affected by this impairment. The optic nerve has also benefited from this quantification (surface of the neuroretinal rim, cavity volume, etc.), so that all parts of the eye that are potentially altered in glaucoma have become accessible with OCT. Obtaining quantitative values and comparing them with the standards allows us to determine the existence and severity of glaucomatous disease and allows for follow-up.

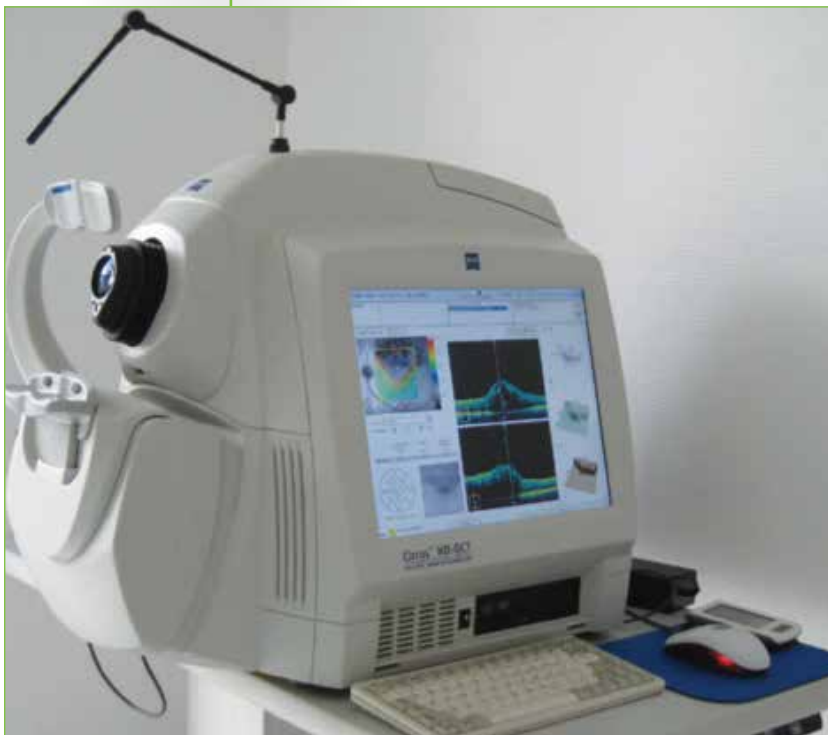It is also possible to analyse the iridocorneal angle, but in a less precise way, especially because what happens at the back of the pigment epithelium of the iris remains inaccessible to OCT.

Glaucoma is one of a range of optic neuropathies, and OCT also appears useful in the analysis of all diseases of the optic nerve and, to some extent, the central nervous system when ocular impacts are present.

However, as with any new technology, analysis of the results of OCT requires careful interpretation because the method of data acquisition is complex and does not involve simple photography of the structures studied. It is always desirable to examine the quality of the results, not only in an overview, but also in closer detail when a zone appears suspect.

Once these pitfalls have been avoided, a new field of exploration and in particular investigations opens up. What is the clinical meaning of one impairment or another? How should a worsening of the impairment of the optical fibres be interpreted if all other exams are stable? How can we explain, on the contrary, that a particular structure is no longer changing in the OCT when the glaucoma is indisputably worsening?

OCT is advancing so quickly that it is impossible to clearly define its use profile, and any document is certain to become obsolete quite quickly. Currently indispensable for analysing the retina, it is becoming so for glaucoma and other optic neuropathies. This little book aims to simply give an update on OCT in glaucoma and pathologies of the optic nerve. The first chapter concerns the principles and interpretation of OCT and has a purely practical function, to help the reader understand the results. Glaucoma is obviously an important part of this book, but one part is devoted to other eye diseases and especially neuro-ophthalmological diseases, because they can mimic glaucoma or be a source of confusion if they are also present. Regardless of this facet of differential diagnosis, OCT has acquired its place in the evaluation of the optic nerve in general.



Cirrus™ HD-OCT (Carl Zeiss)

Principles of OCT

OCT works by analysing the light reflected by zones crossed by an incident light generated by a laser with a wavelength in the infrared range around 840 nm. Logically, when a beam of light passes through a structure, one part of the light will continue its path (especially if the structure is quite transparent), one part will be absorbed by the structure, one part will be reflected in all directions and the final part will be reflected towards the emission zone.

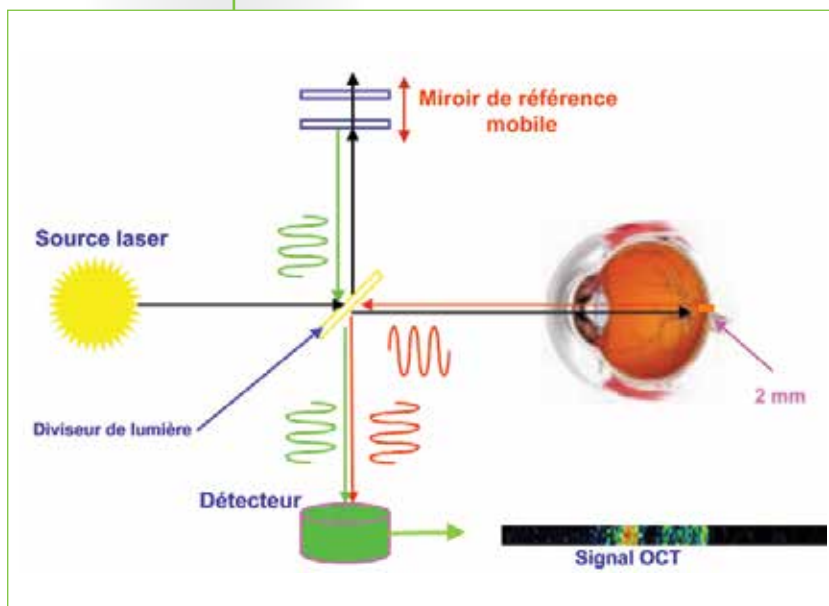
It is this last part of the light that is analysed in OCT. It corresponds to between one-billionth and one-millionth of the incident light, so it is very weak.

General principles

Sound waves propagate relatively slowly (300m/sec in air) and it is possible to record the return time of this wave directly, as with UBM. However, the high propagation speed of light waves (300,000 km/sec) does not allow this time to be recorded, which is in the order of 30 femtoseconds (30×10^{-15} sec).

OCT uses the principle of interferometry to analyse this delay. An incident wave is divided into two, one part being projected onto a plane mirror and the other onto the eye. The two waves thus created are reflected; the wave sent to the mirror returns as a single echo; the wave sent to the eye returns as multiple echoes depending on the structure it has passed through. These waves are compared by an interferometer which measures the coherence between them (hence the term OCT, Optical Coherence Tomography). This allows us to deduce the thickness of the structure passed through by the wave sent to the eye.

This simple measurement at a given point and a given depth is called an A-scan. With “Time Domain” technology, the mirror moves repeatedly at different depths to analyse the different layers of the retina.

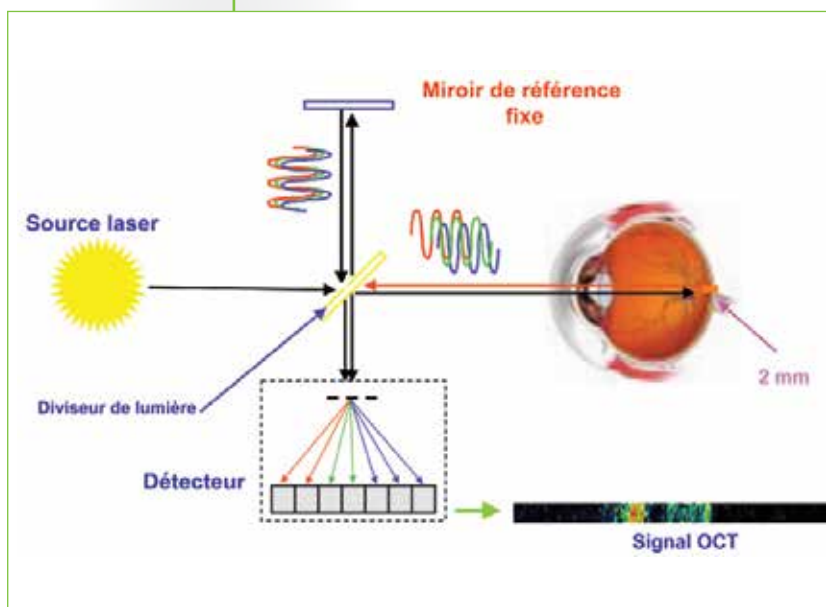


Acquisition of an A-scan: Time Domain

*“Time Domain” OCT technology:
a reference mirror moves to
successively study the different
depths of the retina.*

The fastest devices in Time Domain allow the measurement of 17,000 A-scans per second. These measurements in one dimension are then reassembled into 2 dimensions to obtain a slice of the retina at a given place (B-scan). Time Domain technology is limited by these movement of the mirrors, since an examination cannot reasonably take more than a few seconds when it is necessary for the eye to remain relatively fixed.

A very different technology that has led to a dramatic improvement in the quality of OCT images is “Spectral Domain” technology. Instead of using the coherence between two waves, it uses the interference spectrum between the two reflected beams of broad-spectrum waves. This interference is studied by mathematical analysis using the Fourier transform. The great advantage of this “Spectral/Fourier Domain” technology is that it is possible to analyse the reflected ray not successively at each depth, but at the same time. The reference mirror therefore no longer has to move and this allows the process to become 50 to 100 times faster.



*Acquisition of an A-scan:
Spectral Domain*

*“Spectral Domain”
OCT technology: the reference
mirror is fixed and the different
depths of the retina are analysed
at the same time.*

It is thus possible to make much more precise measurements (around $2\ \mu\text{m}$) during a reasonable examination time. Nevertheless, the examination itself is not instantaneous like a single photograph, and the quality of the results may be affected by an eye movement. It is not instantaneous because if the different depths of the retina can be studied at the same time, it is necessary for the laser beam to successively scan the different regions of this retina.

What does OCT really show?

OCT shows the reflection of light in different eye structures. This reflection is particularly strong when there are sharp edges between two media having different refractive indices. This is particularly the case in the cornea, which is perfectly imaged in OCT. In addition, these reflections are sharper when the structure crossed is perpendicular to the incident light, rather a glass that partially reflects light. In general, reflection of light (only a part of which occurs towards the incident source) is a property of inhomogeneous structures responsible for microchanges in the refractive index, such as cell membranes, nuclei, cytoplasm, axons of cells, etc. The most reflective structures of the retina are the retinal nerve fibre layer (RNFL or optical fibres), the pigment epithelium and the interplexiform layers. The more reflective a structure is, the more red it appears, due to the colour code used in OCT.

Some structures contain melanin, which absorbs light strongly. At this level, reflection and absorption are responsible for an exponential reduction in the power of the incident beam, preventing it from exploring more distant areas. That is why OCT does not allow the precise study of structures beyond the pigment epithelium of the retina, which has the dual property of being highly reflective in the part first hit by light, and highly absorbent in the most basal area.

From this light reflection data, OCT measures the thickness of the layer studied in a calculation that considers the time that the incident beam takes to return and the known refractive index of the structure crossed.

It is therefore very important to note that OCT images are not direct images of the retina, but rather a reconstruction based on mathematical calculations transposed subsequently into images of the ocular fundus. You can understand this quite easily by looking for example at the changes in the appearance of the optical fibres in the optic nerve when these fibres change direction to exit the eye. The reflection of light on the layer of the optical fibres appears in red. When these fibres change direction when moving towards the optic nerve, this colour changes. OCT is therefore not an anatomical slice of the retina.