


**A MODERN
APPROACH TO**



PROFESSOR BÉATRICE COCHENER
PROFESSOR JOSÉ MANUEL BENÍTEZ DEL CASTILLO

**DRY EYE
DISEASE**

**AND OPHTHALMIC
SURGERY**



Preface

The ocular surface, a recent and complex anatomical entity that includes the cornea, limbus, conjunctiva, eyelids and, above all, the tear film, has become a major focus of interest for the medical community, which has measured its importance in terms of patient comfort and visual performance. Dry eye, which represents the main pathology of the ocular surface, is recognized as the main postoperative complaint and as a public health issue, justifying all the efforts of the industry to develop diagnostic tools and targeted treatments.

We are delighted to provide the latest knowledge regarding Dry Eye Disease (DED) in different ocular surgeries.

The incidence of Dry Eye pre- intra- and post- corneal refractive surgery, cataract surgery, glaucoma surgery and eyelid surgery – i.e. the most common procedures - was reviewed. This report provides an analyse of the current knowledge of pathogenic mechanisms and the impact of DED on clinical outcomes and patient satisfaction.

Then, we focused on the risk factors of DED after ocular surgery. As DED is relatively frequent in the general population, pre-existing DED may be exacerbated after ocular surgery.

Overall, the incidence of postoperative DED and the perception of dryness as a postoperative

complication can be reduced if appropriate clinical interventions combining detection, information, preparation, and treatment are given preoperatively, intraoperatively, and postoperatively. We are pleased to present practical tips to manage DED before and after ocular surgery, based on various algorithms published in the recent years in this book.

We hope this handbook will be useful in your practices.

Enjoy your reading!




Professor Béatrice Cochener

*Head of the Ophthalmology
Department in Brest
University Hospital (France)
President of EuCornea*



**Professor José Manuel
Benítez del Castillo**

*Director of the Ocular
Surface and Inflammation Unit
at the Hospital Universitario
San Carlos de Madrid and Clínica
Rementería (Spain)
General secretary of EuDES*



DED & surgeries

3	Ocular Surface and Ocular Surface Disorder (OSD)
4	CHAPTER 1: Dry Eye Disease (DED)
5	Prevalence of DED
6,7	Stages, Grading, Symptoms & Signs of DED
8	Risk factors associated with DED
9	Classification, Diagnosis & Pathophysiology Mechanisms of DED
12	Management of DED
18	CHAPTER 2: Refractive Surgery
19	The Key Clinical Symptoms and Signs of DED Following Laser Refractive Surgery (LASIK)
19	Risk factors associated with DED after LASIK
20	Pathogenic Mechanisms of DED Following Corneal Refractive Surgery
24	Management of DED pre-, intra- and post-operative LASIK
29	Incidence of DED Pre-, Intra- and Post Corneal Refractive Surgery
32	CHAPTER 3: Cataract Surgery
32	Signs & Symptoms of Cataract
34	Risk Factors
35	Risk Factors and Pathogenic Mechanisms of DED Following Cataract Surgery
39	Management of DED pre-, intra- and post-Cataract Surgery
42	Incidence and Prevalence of DED following Cataract Surgery
44	CHAPTER 4: Glaucoma Surgery
45	Ocular symptoms & signs of Glaucoma surgery
45	Risk factors for developing Glaucoma
46	Trabeculectomy
47	Pathogenic Mechanisms of DED Associated With Glaucoma Surgery
51	Management of DED pre-, intra- and post-Glaucoma Surgery
53	Incidence of DED in relation to Glaucoma Surgery
54	CHAPTER 5: Eyelid Surgery
55	Function of Eyelids and Relationship to Tear Film and Dry Eye
58	Complications of blepharoplasty surgery
58	Signs and symptoms of DED following blepharoplasty
59	Risk factors for DED following blepharoplasty
60	Pathogenic Mechanisms of DED Following Blepharoplasty
62	Management of DED pre-, intra- and post-Blepharoplasty
66	Incidence of DED Pre-, Intra- and Post Blepharoplasty
68	Conclusion/Summary
72	References

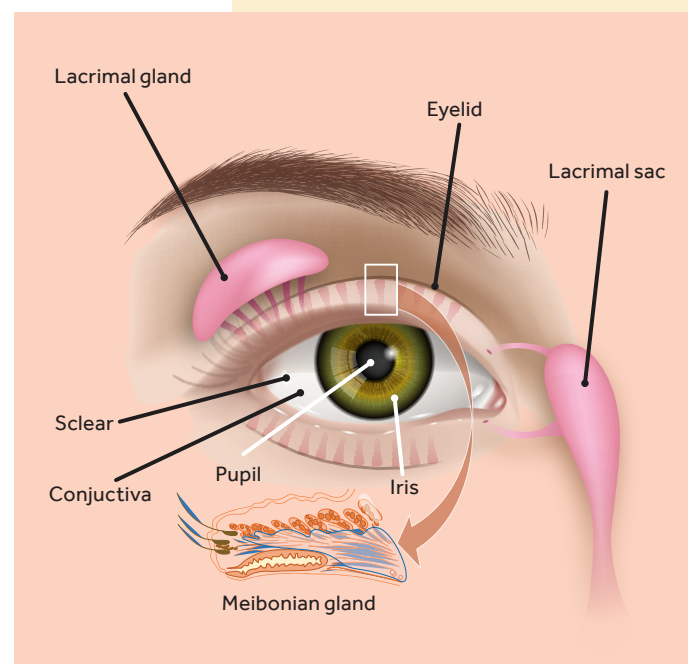
Ocular Surface and Ocular Surface Disorder (OSD)

Ocular surface includes the surface and glandular epithelia of the conjunctiva, cornea, lacrimal gland, and meibomian gland, and their basal (connective tissue) and apical (tears) matrices, the eyelashes with their associated glands of Moll and Zeis, components of the eyelids responsible for the blink, and the nasolacrimal duct (see schematic; *Gipson 2007*). Any disorder in these structures can be classified as an ocular surface disorder (OSD).

OSD represents a global public health challenge with significant impact on quality of life. The incidence rate of OSD increases with aging and ranges from 5 to 30 percent in the general population aged 50 years and older (*Smith JA 2007*).

OSD includes (*Khanna 2017*):

- Dry Eye Disease (DED)
- Allergic Eye Disease (AED)
- Meibomian Gland Dysfunction (MGD)
- Blepharitis
- Chemical and Thermal Burns



Schematic representation of the ocular surface (<https://www.aao.org/image/meibomian-gland> and <https://teachmeanatomy.info/head/organs/eye/lacrimal-gland/>).

Patients with OSD may

(*Ali Al-Rajhi 2018*):

- | | |
|--------------------------|---|
| Develop photophobia | Have limited performance of daily activities |
| Develop corneal scarring | Have a negative impact on their quality of life |
| Develop blurred vision | Develop depression |
| Develop pain | |

Dry Eye Disease (DED)

What is DED?

First definition presented at 1995 National Eye Institute: "Dry eye is a disorder of the tear film due to tear deficiency or excessive evaporation, which causes damage to the interpalpebral ocular surface and is associated with symptoms of ocular discomfort" (Lemp MA. 1995).

DEWS 2007 Definition: "Dry eye is a multifactorial disease of the tears and ocular surface that results in symptoms of discomfort, visual disturbance, and tear film instability with potential damage to the ocular surface. It is accompanied by increased osmolarity of the tear film and inflammation of the ocular surface" (Lemp MA 2007).

Dry eye is a multifactorial disease of the ocular surface characterized by a loss of homeostasis of the tear film, and accompanied by ocular symptoms, in which tear film instability and hyperosmolarity, ocular surface inflammation and damage, and neurosensory abnormalities play etiological roles (Craig, Nichols, et al 2017).

Dysfunction of any component of the lacrimal functional unit (Figure 1) can alter the quality or quantity of tears, and thus cause derangement of tear film homeostasis resulting with more or less dry eye disease (DED) symptoms.

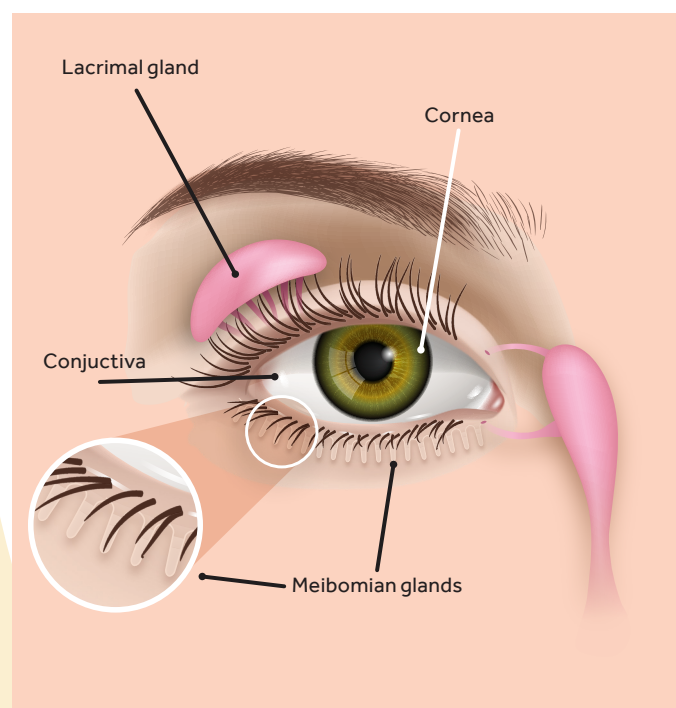


Figure 1: The lacrimal functional unit, responsible for tear secretion, is composed of the ocular surface, the main lacrimal gland, and interconnecting innervation (Yazdani et al).

DED occurs when the tears aren't able to provide adequate lubrication in the ocular surface and the healthy tear, which consists of three layers (fatty oils, aqueous fluid and mucus), is disrupted (Figure 2).

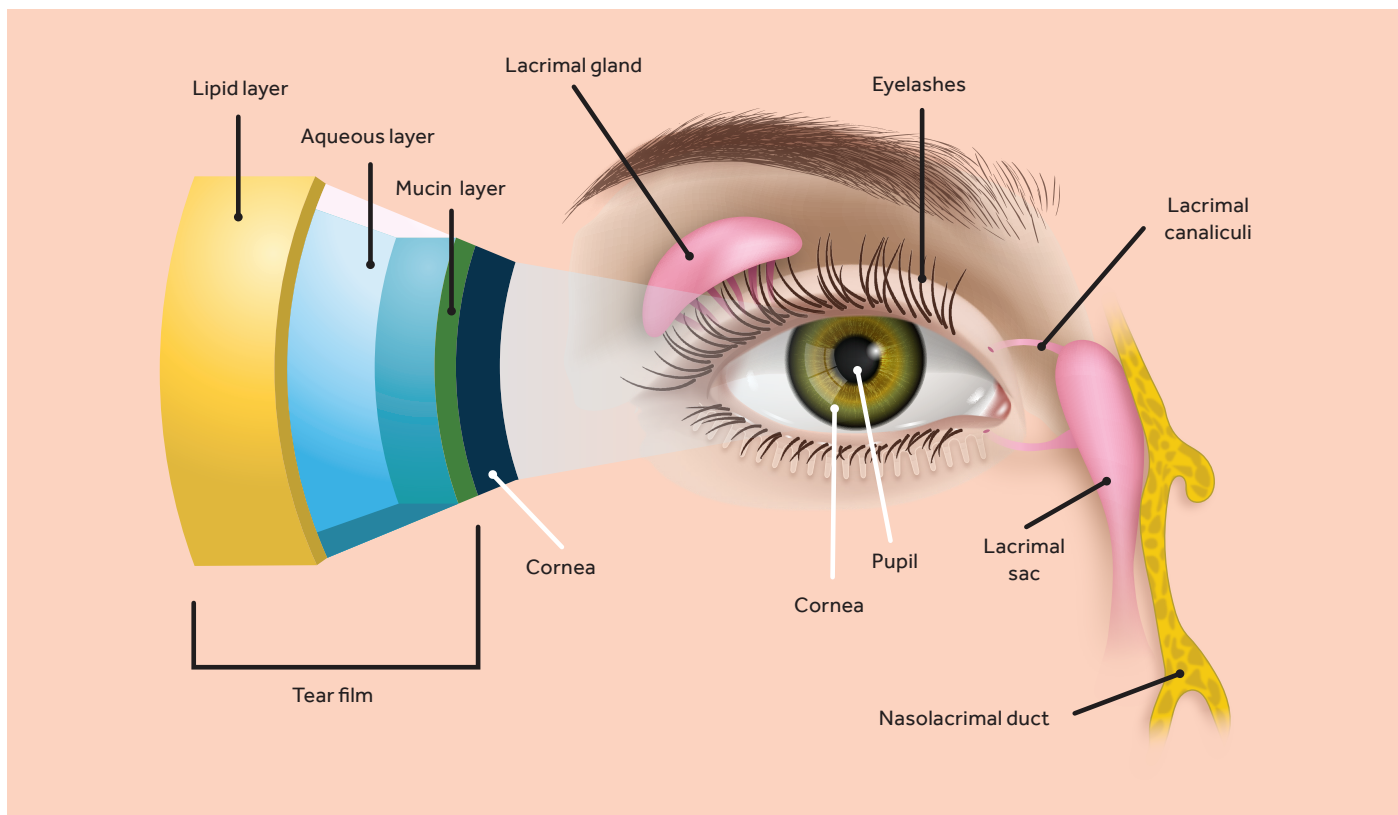


Figure 2: The lacrimal apparatus and the three layers of the tear film. The lacrimal canaliculi drain lacrimal fluid to the lacrimal sac and the nasolacrimal duct carries tears from the lacrimal sac into the nasal cavity. The tear gland (lacrimal gland) secretes the tear film consisting of an outer lipid layer, intermediate aqueous layer and an inner mucin layer. (https://cw.medinforma.co.za/health_subjects/dry-eye/).

Prevalence of DED

DED epidemiology continues to be challenged by the failure for a standardized definition and diagnostic criteria to be used (Craig, Nelson, et al. 2017; Craig, Nichols, et al. 2017).

DED is extremely common in the general adult population (Stapleton et al. 2017).

The prevalence is described by (Caffery et al. 2019; Farrand et al. 2017).

Farrand et al, 2017

In a cross-sectional survey, 6.8% of the US adult population was projected to have diagnosed DED. Prevalence increased with age (18-34 years: 2.7%; ≥75 years: 18.6%) and was higher among women (8.8%) than men (4.5%).

Caffery et al, 2019

In a cross-sectional survey in Canada, DED prevalence was estimated to be 22%. The prevalence also increased with age and was significantly higher in adults 55 - 64 years (24.7%) compared with 25 - 34 years (18.4%).

Stages of DED

A classification of dry eye based on the severity of symptoms and clinical signs has been established (Table 1, (Elisabeth M. Messmer 2015)).

Table 1: Dry eye disease severity grading scheme (Elisabeth M. Messmer 2015).

Dry eye severity level	1	2	3	4
Discomfort, severity and frequency	Mild and/or episodic; occurs under environmental stress	Moderate episodic or chronic, stress or no stress	Severe frequent or constant without stress	Severe and/or disabling and constant
Visual symptoms	None or episodic mild fatigue	Annoying and/or activity-limiting episodic	Annoying, chronic and/or constant, limiting activity	Constant and/or possibly disabling
Conjunctival injection	None to mild	None to mild	+/-	+ / ++
Corneal staining (severity/location)	None to mild	Variable	Marked central	N/A
Corneal/tear signs	None to mild	Mild debris, ↓ meniscus	Filamentary keratitis, mucus clumping, ↑ tear debris	Filamentary keratitis, mucus clumping, ↑ tear debris, ulceration
Lid/meibomian glands	MGD variably present	MGD variably present	MGD frequent	Trichiasis, keratinization, symblepharon
Tear film break-up time (seconds)	Variable	≤ 10	≤ 5	Immediate
Schirmer score (measures tear secretion) (mm/5 minutes)	Variable	≤ 10	≤ 5	≤ 2

When more than one of the following symptoms (Figure 3) persist, it is advisable to consult an ophthalmologist to get an accurate diagnosis and follow a preventive therapy.

Dry Eye Symptoms & Signs

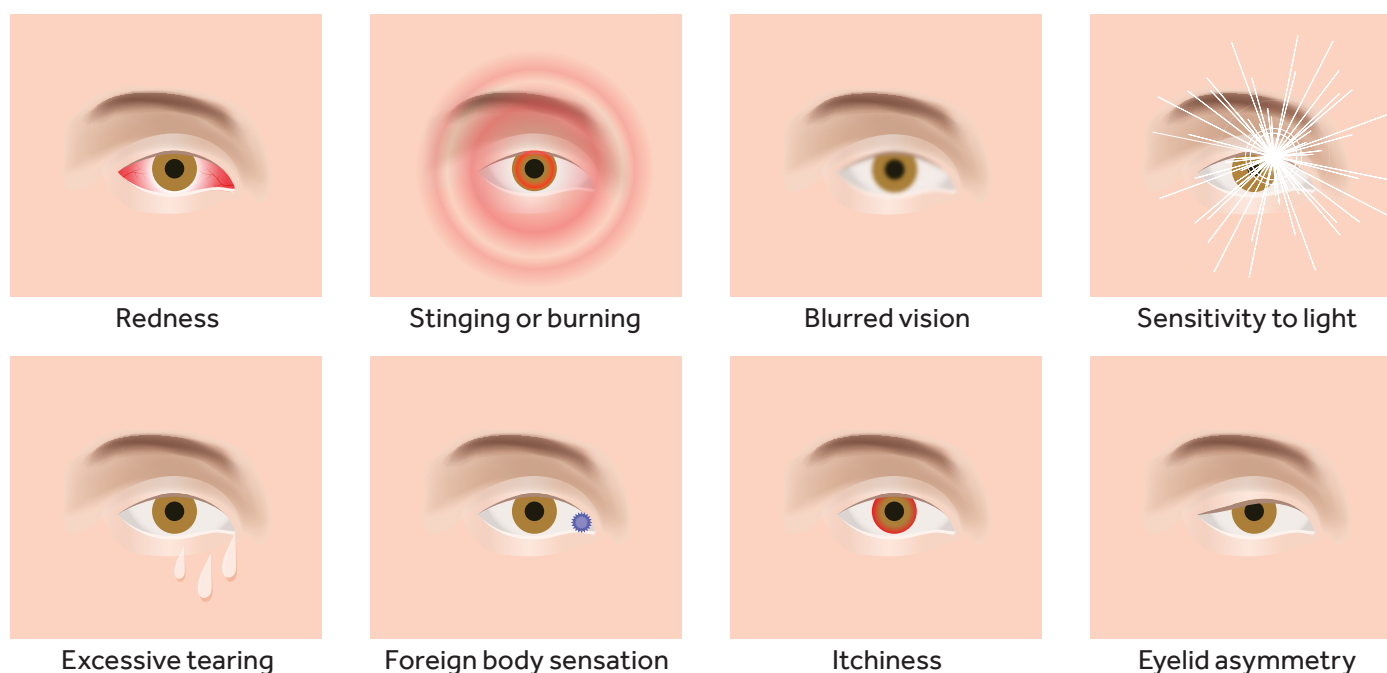


Figure 3: Common visual complaints associated with dry eye (<https://www.malayaoptical.com/dry-eye-symptoms/>)(Pinho Tavares et al. 2010).

Grading Scales of Corneal and Conjunctival Staining Images

Two recommended guidelines are predominantly followed by ophthalmologists in grading conjunctival and corneal staining (Figures 4 & 5; (Begley et al. 2019)).

The Oxford grading scale which divides corneal and conjunctival staining into six groups according to severity from 0 (absent) to 5 (severe) (Bron, Evans, and Smith 2003).

The National Eye Institute/Industry (NEI) scale divides the cornea into five zones (central, superior, temporal, nasal, and inferior) and for each zone, the severity of corneal fluorescein staining is graded on a scale from 0 to 3 (Begley et al. 2019).

Staining with lissamine green are for early to moderate DED while corneal sodium fluorescein for moderate to severe DED (Bron et al 2003).

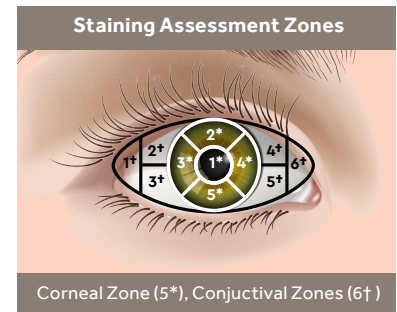
Oxford grading scale

Panel	Grade	Descriptor
A	0	Absent
B	I	Minimal
C	II	Mild
D	III	Moderate
E	IV	Marked
>E	V	Severe

NEI grading scale

Conjunctiva Staining
Lissamine Green

Corneal Staining
Sodium Fluorescein



Corneal Zone (5*), Conjunctival Zones (6†)



Figure 4: The Oxford and NEI grading scales for estimating conjunctival and corneal staining, and thus severity level of DED (Figure adapted from (Chien et al. 2017; Song et al. 2014).
<https://www.aao.org/image/neiindustry-grading-system>, <https://www.aao.org/image/oxford-grading-system>

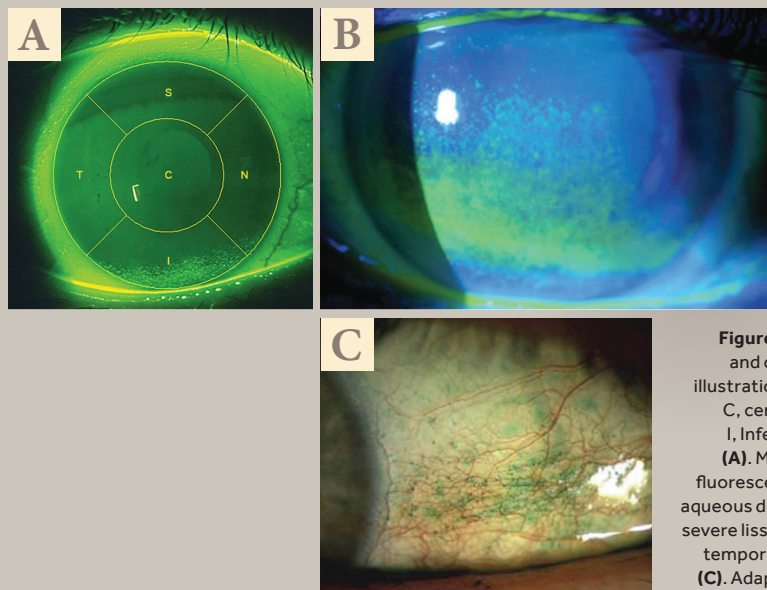


Figure 5: Example of conjunctival and corneal staining. Schematic illustration of the five corneal zones: C, central zone; S, superior zone; I, Inferior zone; T, temporal zone; N, nasal zone. (A). Moderate-to-severe corneal fluorescein staining in a patient with aqueous deficiency (B). Moderate-to-severe lissamine green staining of the temporal aspect of the conjunctiva (C). Adapted from (Milner et al. 2016; Woods et al. 2018).

Aqueous Deficient Dry Eye (ADDE)

Sjogren Syndrome Dry Eye (SSDE) associated autoimmune diseases

- Rheumatoid Arthritis
- Systemic Lupus Erythematosus
- Systemic Sclerosis

Lacrimal gland deficiency

- Blocking sensory drive to lacrimal gland that is essential to maintain osmolar homeostasis

Age- and Sex-related

Trigeminal nerve Injury

Inflammatory (Lymphoma , Sarcoidosis)

Chronic abuse of topical anesthetics

Medication Use

- Antihistamines, beta-blockers, diuretics, psychotropic drugs, anticholinergics

Ocular Surgery & Refractive Surgery including LASIK surgery

Risk factors associated with DED

Several risk factors have been reported to be associated with the development of DED and they are categorized into ADDE and EDE (see schematic below; *Bron et al. 2017; Craig, Nichols, et al. 2017*).

Evaporative Dry eye (EDE)

Meibomian Gland Dysfunction (MGD)

Ocular Surface-Related EDE

- Allergic Eye disease
- vitamin A Deficiency

Disorders of Lid aperture, Dynamics

Contact Lens wear

Ocular Surface Inflammation

Blepharitis

Environmental Conditions (Humidity, Pollution)

Tobacco and screen

Classification, Diagnosis & Pathophysiology Mechanisms of DED

A clinical decision algorithm is recommended beginning with the assessment of symptoms and signs for DED (Figure 6).

Dry eye questionnaires (e.g. Standard Patient Evaluation of Eye Dryness (SPEED) or McMonnies Questionnaire (MQ)) exist to aid the specific diagnosis and grade the severity to set a baseline

for future reference. The OSDI (Ocular Surface Disease Index) and DEQ-5 (Dry Eye Questionnaire 5) are the most widely used (Craig, Nelson, et al. 2017; Craig, Nichols, et al. 2017).

Symptomatic patients without demonstrable clinical signs do not fall into the DED group but might be differentiated into pre-clinical dry eye or neuropathic pain (non-ocular surface disease). Asymptomatic patients with signs of OSD are characterized either by predisposition, where preventive management (e.g. pre-surgery) is suggested as a measure, or by neurotrophic conditions (Bron et al. 2017; Craig, Nichols, et al. 2017).

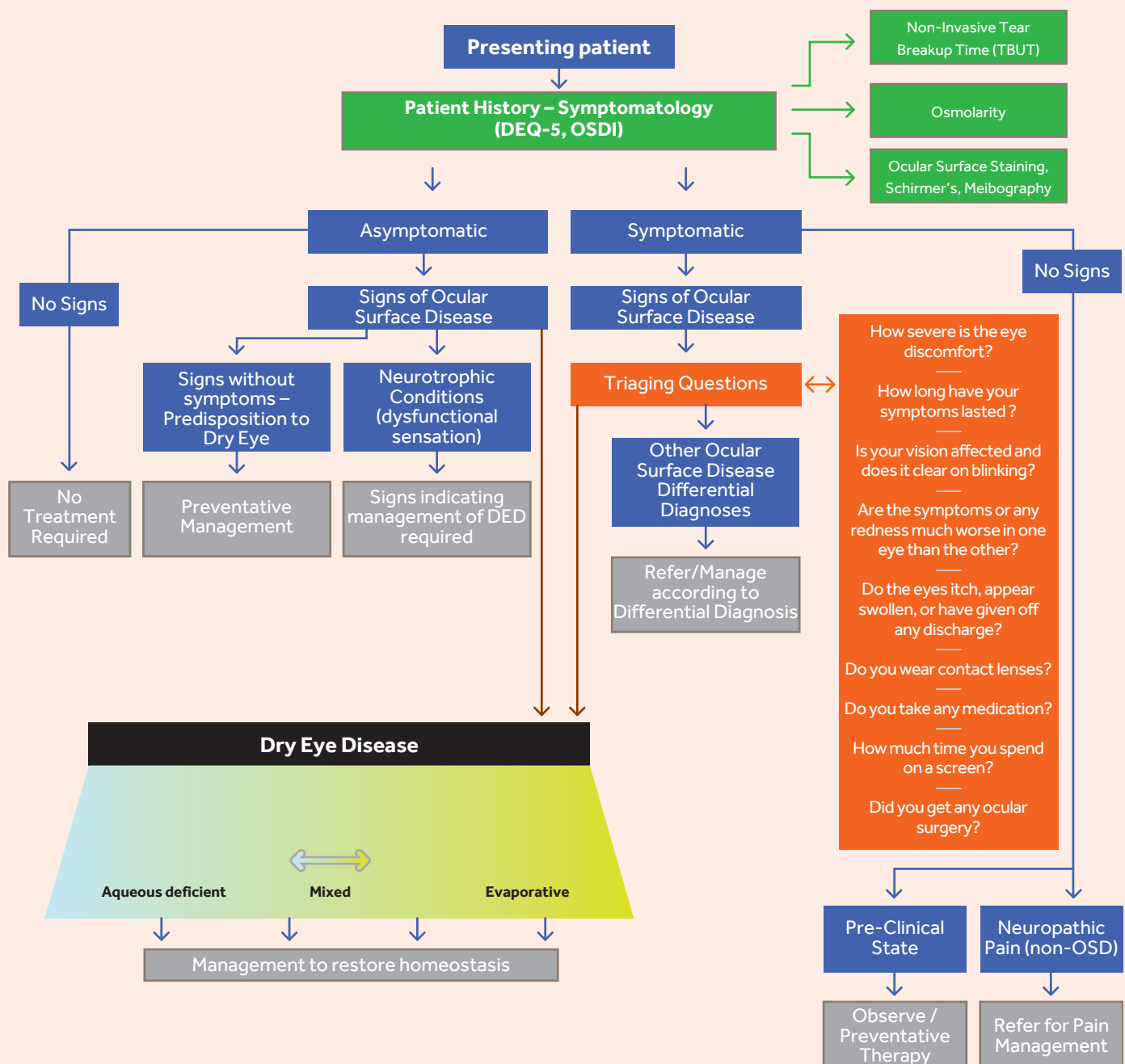


Figure 6: Clinical algorithm approach for assessing DED. Various dry eye questionnaires exist (e.g. SPEED, McMonnies) but among the most widely used ones, Dry Eye Questionnaire-5 (DEQ-5) and Ocular Surface Disease Index (OSDI) indicate whether a patient might have DED and presence of any one of three specified signs; reduced non-invasive tear break-up time, elevated interocular disparity in osmolarity, or ocular surface staining (of the cornea, conjunctiva or lid margin) in either eye. All of these along with Meibography and Schirmer's test are considered representative of disrupted homeostasis, confirming the diagnosis of DED. Further classification is performed to determine whether patient is symptomatic or asymptomatic with or without signs/symptoms. Clinician is interested to evaluate where the DED falls on the spectrum between (aqueous deficient dry eye) ADDE and evaporative dry eye (EDE), and the severity of DED, to guide treatment. Epidemiological and clinical evidence suggest that DED is predominantly evaporative in nature. Constructed from (Bron et al. 2017; Craig, Nelson, et al. 2017; Craig, Nichols, et al. 2017).

Two main types of DED exist; EDE and ADDE (see schematics below & Figure 7), along with a mixed form of DED, which accounts for more than 80% of the cases (Messmer 2015).

ADDE

— In ADDE, tear hyperosmolarity results when lacrimal secretion is reduced, in conditions of normal evaporation from the eye.

EDE

— In EDE, tear hyperosmolarity is caused by excessive evaporation from the exposed tear film in the presence of a normally functioning lacrimal gland.

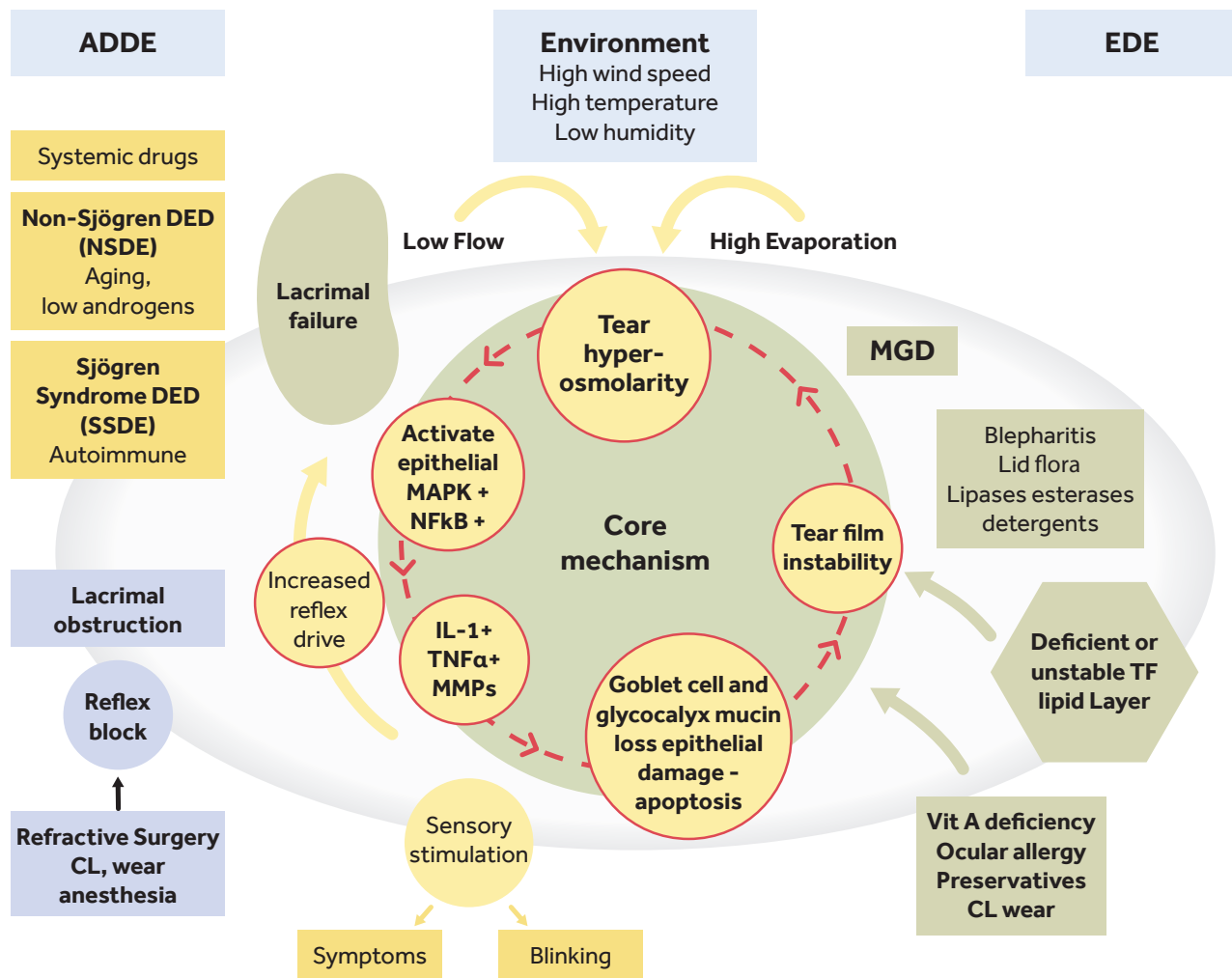
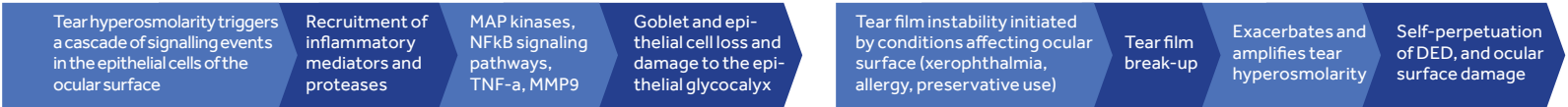

Figure 7: The Vicious Circle of DED. The core mechanism of DED is tear hyperosmolarity. The tear hyperosmolarity and epithelial injury caused by DED stimulates corneal nerve endings, leading to symptoms of discomfort, increased blink rate and potentially, a compensatory, reflex increase in lacrimal tear secretion. Tear film instability, which can be initiated by conditions that affect the ocular surface, including xerophthalmia, ocular allergy, topical preservative use and contact lens wear, leads to early tear film break-up. This break-up exacerbates and amplifies tear hyperosmolarity and completes the vicious circle events that lead to ocular surface damage. Ultimately this is thought to lead to self-perpetuation of the disease. In MGD-related EDE tear hyperosmolarity results from a tear film lipid layer deficiency. Various causes of ADDE exist, such as reflex block to the lacrimal gland due to chronic abuse of topical anesthetics, trigeminal nerve damage and refractive surgery, as well as reduction in lacrimal secretion due systemic medication (antihistamines, beta-blockers, antispasmodics, diuretics and some psychotropic drugs) (Bron et al. 2017).

A list of specific triaging questions has been developed (Figure 6), with the intention of allowing the practitioner to differentially diagnose DED compared to other conditions that can mimic the symptoms.

A thorough slit-lamp examination should be performed to identify dry eye prior to any other clinical tests to exclude misdiagnosis.

For example, slit lamp examination includes observation for:

- superficial corneal erosions, inadequate tear lake volume, early tear film break-up time, osmolarity, ocular surface staining, conjunctival hyperemia, conjunctival surface irregularities, meibomian gland dysfunction, functional visual acuity and tear meniscus assessment (Zeev et al. 2014).

Differential diagnosis includes a slit lamp biomicroscope to examine (Wolffsohn et al. 2017) (Figure 8):

- eyelashes for anterior blepharitis and signs of demodex infestation
- bulbar and palpebral conjunctivitis
- different types of conjunctivitis
- presence of cells or flare, indicating intraocular inflammation

Blepharitis is a chronic inflammatory process of the eyelid margin which may be associated with several systemic diseases, particularly rosacea and seborrheic dermatitis, and is related to other ocular conditions like dry eye, chalazion, conjunctivitis, and keratitis.

- Clinical examination reveals the presence of scurf, telangiectatic vascular changes of the eyelid margin, inspissated meibomian glands, conjunctival hyperemia, punctate keratopathy, cornea vascularization, and ulceration (Bernardes and Bonfioli 2010).

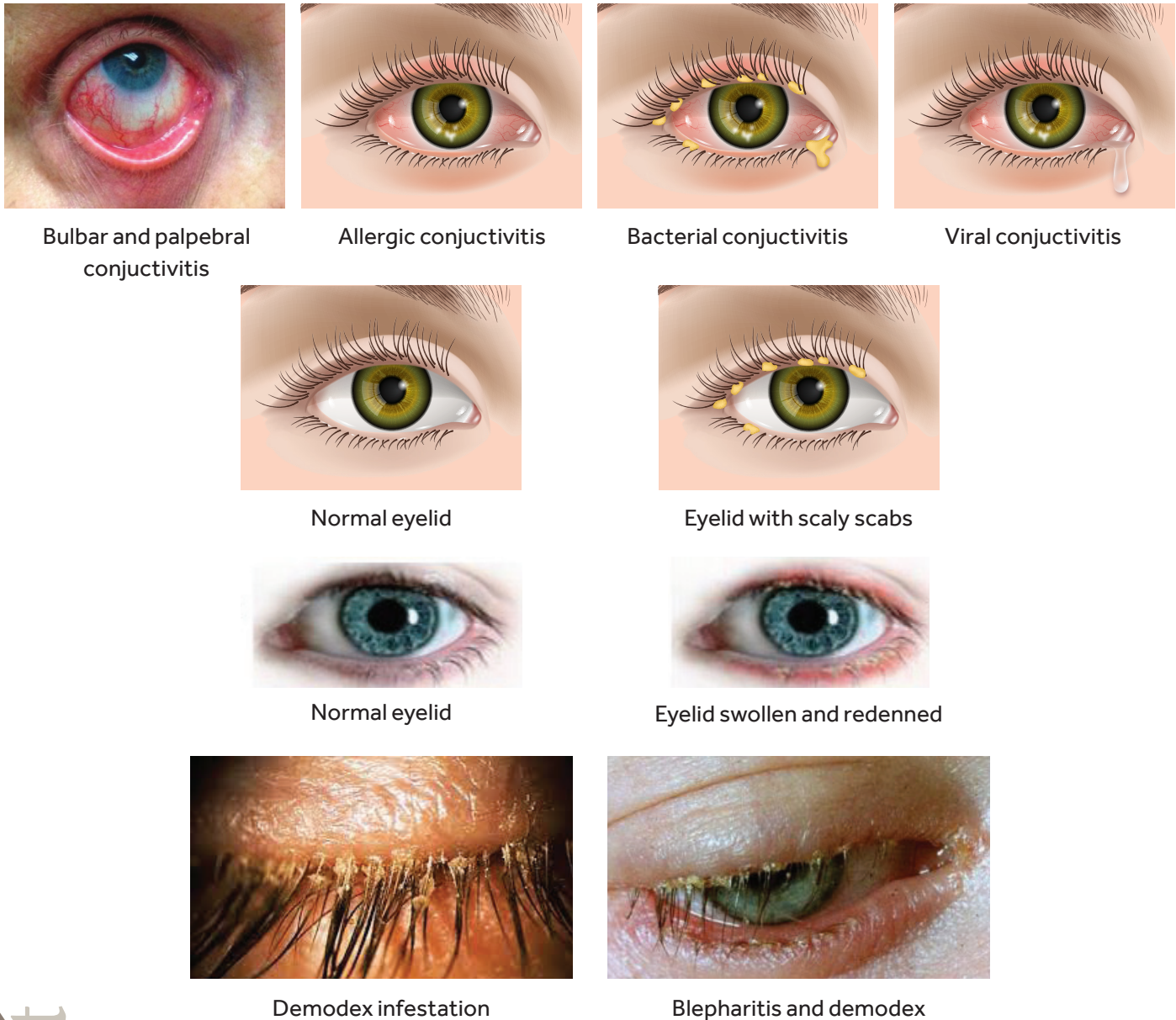


Figure 8: Schematics and patients' eye representation of slit lamp examination for differential diagnosis of DED including several types of conjunctivitis, blepharitis and demodex infestation (Bielory et al. 2013)

<https://goldeneyeoptyometry.com/2019/02/11/blepharitis/>, <https://glaucoma.uk/blepharitis/>
http://west-sussex-family-assist.custhelp.com/app/answers/detail/a_id/314/-/conjunctivitis
<http://www.eyepathology.gr/demodex>

Keypoint

The core mechanism of DED is tear hyperosmolarity, which is the hallmark of the disease. It damages the ocular surface both directly and by initiating inflammation. Eye surgery, particularly LASIK, is a risk factor of DED. (Bron et al 2017; Craig, Nichols et al 2017).

Management of DED

Management of DED can be challenging due to its multifactorial etiology and discordance between symptoms and clinical signs (Agarwal, Craig, and Rupenthal 2021).

It is an ongoing and complex condition that varies from patient to patient, both in severity and in character (Jones et al. 2017).

Management algorithms (Table 2) are often constructed to recommend a sequence of treatments according to the stage of disease, but there is significant heterogeneity in the DED patient population, therefore, the approach may be modified based on individual patient profile (Agarwal et al. 2021; Craig, Nichols, et al. 2017; Jones et al. 2017).

Management and Treatment Options for DED

1 STEP	2 STEP	3 STEP	4 STEP
Education	Non-preserved ocular lubricants	Oral secretagogues	Amniotic membrane grafts
Environmental modifications	Punctal occlusion Moisture chamber devices	Autologous serum eye drops	Systemic anti-inflammatory agents
Dietary and lifestyle modifications	Topical secretagogues	Therapeutic contact lens options	Surgical punctal occlusion
Medication received	Topical antibiotic for anterior blepharitis	Soft bandage lenses	
Tear supplementation	Topical anti-inflammatory drugs (cyclosporine, corticosteroids)	Rigid scleral lenses	
Lid hygiene, warm compresses			

Table 2: Therapeutic strategies for the management and treatment of DED according to level of severity (Step 1 to 4; Constructed from (Agarwal et al. 2021; Craig, Nichols, et al. 2017; Jones et al. 2017).

Keypoint

Management of DED involves chronic monitoring and application of a treatment considering the risk versus benefit and cost considerations between multiple treatment options among patients (Jones et al 2017).

A common approach for treating dry symptoms is anti-inflammatory medication, mainly steroids in combination sometimes with osmoprotectants, such as hyaluronic acid (HA; Figure 9).

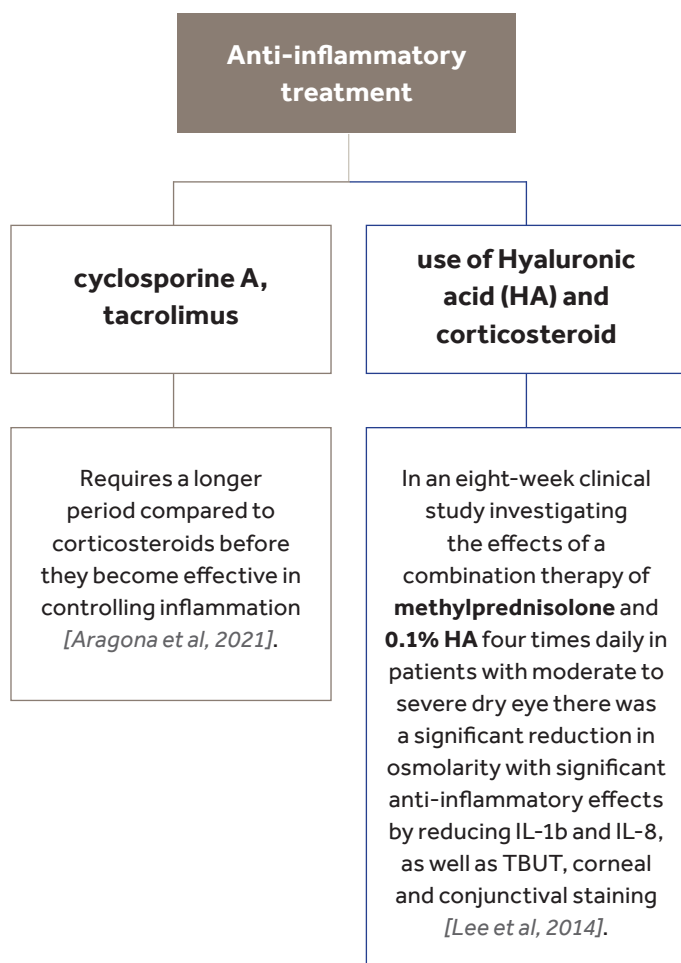


Figure 9: Anti-inflammatory treatments for dry eye symptoms with an example of a study applying steroid together with hyaluronic acid (Aragona et al. 2021; Lee et al. 2014)

Topical corticosteroids are associated with side effects, such as increased intraocular pressure (IOP) and with the potential for steroid-induced glaucoma (Pleyer et al 2013).

An alternative approach to this issue comprises the use of mild or soft steroids, such as hydrocortisone (Aragona et al 2021).

Short term hydrocortisone when safely combined with long-term ciclosporin A therapy may provide fast improvement of clinical symptoms in DED and may have positive long-term effects on the optical image quality (Fondi et al 2021).

Use of hydrocortisone

The use of mild or soft steroids, such as hydrocortisone, is highly indicated for patients with DED, where a long-lasting anti-inflammatory treatment is advisable (Aragona et al. 2021).

This treatment can be considered safer than other types of corticosteroid molecules. However, it is always mandatory to check intraocular pressure and the lens status during the treatment (Aragona et al 2021) (Figure 10).

A

In a prospective study, patients with chronic DED and ocular surface inflammation received preservative-free hydrocortisone (SOFTACORT® 3.35mg/ml eye drops, solution in single-dose container, THEA study, Laboratories Théa, France) which resulted in reduced ocular inflammation and decreased OSDI score with no change in IOP [Kallab et al, 2020].

B

A retrospective review demonstrated that topical application of preservative-free hydrocortisone (SOFTACORT® 3.35mg/ml eye drops, solution in single-dose container, THEA study, Laboratories Théa, France) twice daily for 2 weeks significantly improved clinical signs and symptoms in patients with mild to moderate DED [Elabjer et al 2020].

Figure 10: Examples of studies applying hydrocortisone (soft corticosteroid) for relieving symptoms of DED (Elabjer et al. 2020; Kallab et al. 2020; Schmid et al. 2015).

Viscosity enhancing agents & Trehalose

Certain viscosity enhancing agents that are included in eye drops, such as hydroxypropyl methylcellulose (HPMC), HP-guar, carboxymethyl cellulose (CMC) and hyaluronic acid (HA) in addition to osmoprotectants, such as trehalose, can improve dry eye symptoms (Figure 11, (Jones et al. 2017)).

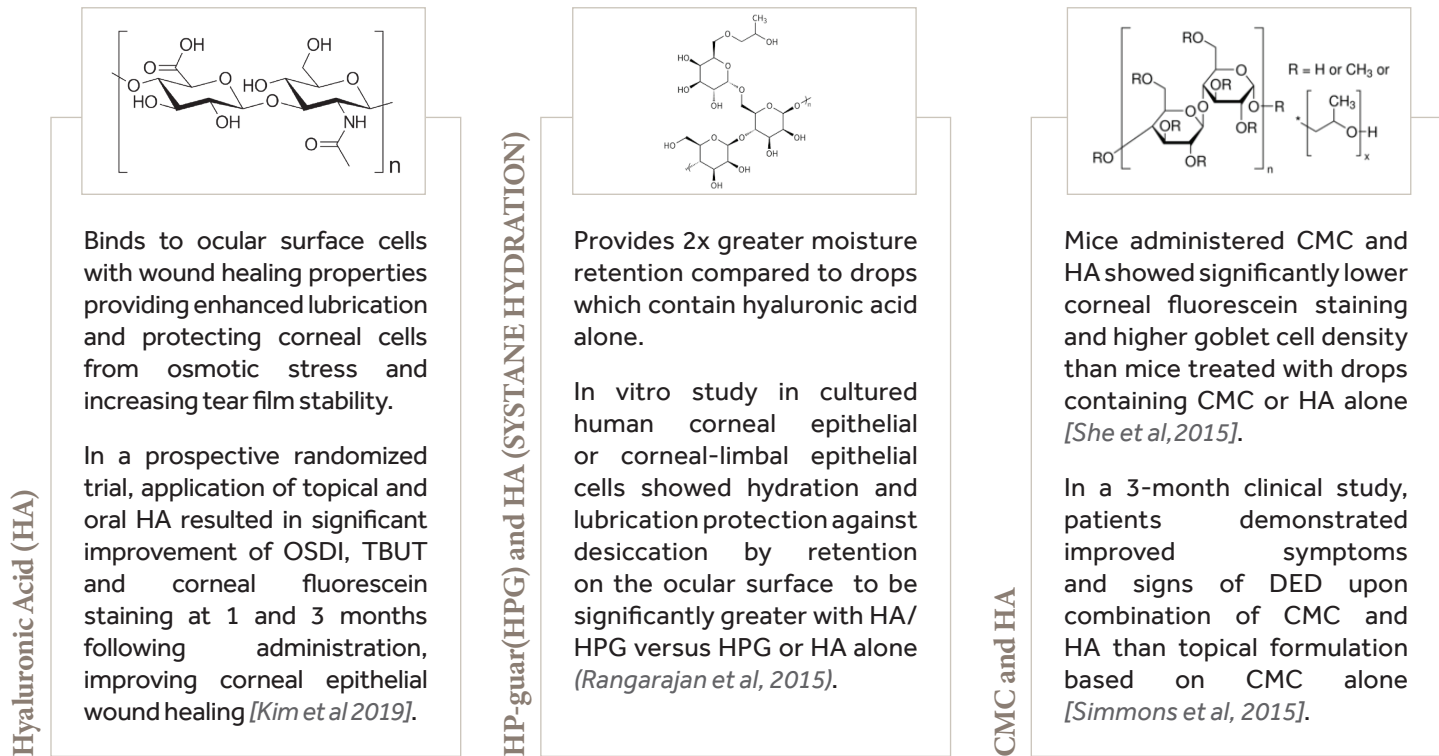


Figure 11: Studies examining the role of hyaluronic acid (HA) alone and in combination with HP-guar and CMC in improving dry eye symptoms and signs (Kim et al. 2019; Rangarajan et al. 2015; Simmons et al. 2015).

Trehalose

- An osmoprotectant that protects corneal cells from the osmotic stress of a dry eye environment.
- Several studies have demonstrated significant results on the efficacy of osmoprotectants in improving dry eye signs and symptoms (Figure 12).
- Preserves the integrity of corneal and conjunctival cells by regulating inflammatory cytokines, maintaining osmotic balance and protecting against apoptosis (Mencucci et al. 2021).
- Effectively controls inflammation due to the activation of the transcription factor E-boxB, responsible for the autophagy cellular degradation pathway (Mencucci et al. 2021).

Trehalose and HA [Thealoz® Duo (Laboratoires Thea, Clermont Ferrand, France)]

- A randomised study showed that a single drop of Thealoz® Duo improved the thickness of the tear film for at least 4 hours (6 times longer than HA alone) [Schmidl et al, 2015].
- In a clinical study, patients with moderate to severe DED who received Thealoz® Duo were symptom-free after 84 days, with significant improvements in blurred vision, stinging and itching compared to HA alone [Chiambaretta et al, 2017].
- In a randomised study, two groups of subjects with moderate to severe DED received a mixture of HA and trehalose (Thealoz® Duo) and of HA, trehalose and carbomer (HTC-gel, Thealoz® Duo Gel) and both demonstrated improvement in signs and symptoms of DED (Fondi et al, 2018).

Figure 12: Various studies examining the efficacy of HA together with trehalose in improving dry eye signs and symptoms (Chiambaretta et al. 2017; Fondi et al. 2018; Hernandez et al. 2021; Schmidl et al. 2015).

Tear replacement is a predominant therapeutic approach for DED with alternative topical formulations being applied which are divided in two main categories; preserved and preservative-free eye drops.

Preservative-free eye drops

Sufficient evidence demonstrates that patients with DED, who require frequent dosing with lubricants or who use chronic topical therapies in conjunction, such as glaucoma medications, should avoid the use of ocular lubricants especially when preserved with benzalkonium chloride (BAK) (Jones et al. 2017).

Preservative-free formulations aim to remove the potential detrimental effect of introducing a preservative to the ocular surface and have a negative impact on tear film (Jones et al. 2017).

Signs and symptoms of DED were reduced by 2- or 3-fold in preservative-free compared to preservative containing medication (Figure 13; (Jaenen et al. 2007).

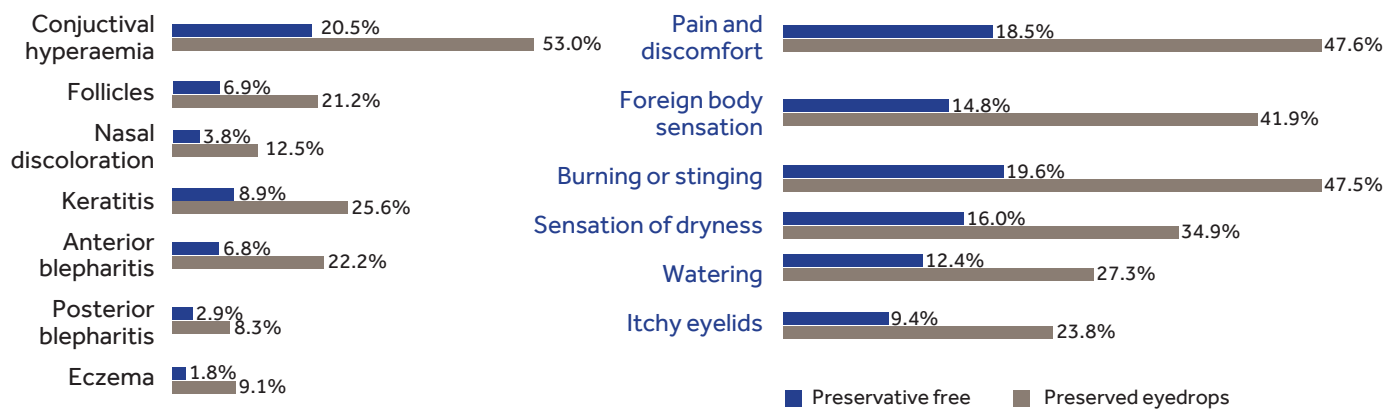


Figure 13: Improvement in signs and symptoms of DED by 2- or 3-fold after using preservative-free compared to preservative containing eye drops (Jaenen et al. 2007).

Preserved eye drops

Topical eye drops containing preservatives administered preoperatively and postoperatively may cause tear film instability and decrease the number of mucin expressing cells and lead to dry eye and corneal damage postoperatively (Cetinkaya et al. 2015).

Benzalkonium chloride (BAK) was originally used to improve penetration of the active agent and is one of the most commonly used preservatives in topical eye drops including antibiotics and steroids.

BAK can cause or enhance various clinical manifestations at the ocular surface level as illustrated in the schematic below (Baudouin et al. 2010; Vaede et al. 2010).

Allergic or nonallergic blepharitis	Meibonian gland dysfunction
Chronic conjunctival inflammation	Tear film instability
Goblet cell density loss	Conjunctival squamous metaplasia and apoptosis
Conjunctival and corneal epithelial cell toxicity	Damages to deeper ocular tissues

BAK is of the main preservatives in anti-glaucoma medication and its long-term use is probably associated with:

- the fibrosis process and bleb failure (Souchier et al. 2006).
- chronic inflammatory changes in the ocular surface (Lemp MA 2007) including increase in subepithelial macrophages, lymphocytes, mast cells, and fibroblasts (Sherwood et al. 1989).

BAK should be avoided or reduced in patients with:

- ✗ severe glaucoma
- ✗ requiring multiple therapy
- ✗ clinically impaired ocular surface (dry eye, allergic reactions, or blepharitis)

Table 3: Dose-dependent toxicity of BAK on the ocular surface

BAK concentration	Ocular effects
0.004%	Significant reduction of the lacrimal tear film
0.005%	Direct toxicity on superficial cells with epithelial erosion
0.007%	In-vitro conjunctival epithelial cell lysis in 90 -100 sec
0.01 %*	Important epithelium alteration, stimulation of limbal and conjunctival infiltration of inflammatory cells
0.02%	Corneal cicatrisation delay
0.1%	Destruction of the endothelium and irreversible corneal oedema in case of intracameral injection
0.1 to 0.5%	Major toxic keratitis, epithelial metaplasia, corneal infiltration of inflammatory cells, and neovascularisation induced by repeated administration in rat
1 to 2% (in animals)	Total destruction of the anterior segment (conjunctiva and cornea) in less than one week

* The most frequent concentration used. Adapted from (Vaede et al. 2010)

Summary Keypoints

DED is characterised by tear film instability and ocular surface inflammation.

The prevalence rate of DED is relatively high.

Multiple mechanisms are involved in the pathogenesis of DED with management of DED being challenging.

Changing to non-preserved topical medications reduced the prevalence of DED.

Preservative-free drops may be a better choice for patients who have pre-existing ocular surface conditions and/or need frequent instillation of eye drops.

(Jones et al 2007; Aragona et al 2021)


Quality of life can be severely affected by dry eyes which may be associated with contact lens intolerance leading patients to seek alternate methods of relief, including refractive error correction (Shtein 2011).

The main different types of corneal refractive surgery that will be discussed in this handbook include: LASIK (LASer In situ Keratomileusis, FS-LASIK (FemtoSecond LASIK), PRK (PhotoRefractive Keratotomy) and SMILE (SMall Incision Lenticule Extraction).

A majority of patients complain of dry eye symptoms following LASIK especially in the early postoperative period. Post-LASIK dry eye usually peaks in the first few months after surgery, and then symptoms begin to improve in the majority of patients at 6–12 months after surgery (Shtein 2011).

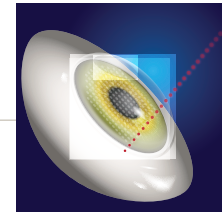
Refractive Surgery

Corneal refractive surgery has evolved with four major types most widely used, as depicted in the schematic below (Liu et al. 2019).



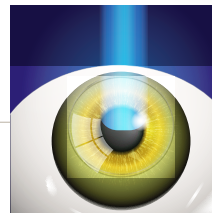
Laser in-situ keratomileusis (**LASIK**) is a common procedure to correct refractive error and reshape the cornea.

It involves creation of a superficial flap of corneal epithelium and anterior stroma, which is retracted to allow for ablation of the underlying tissue.




The femtosecond laser (**FS-LASIK**) produces ultrashort pulses at a very high intensity, achieving a very precise cutting effect with consistent flap diameters and thicknesses.

Provides reduced epithelial injury and faster recovery of corneal sensation.



In photo-refractive keratotomy (**PRK**) stromal tissue is removed solely with an excimer laser photoablation to the corneal epithelial basement membrane and anterior stroma without transection of deep stromal nerves.



Small incision lenticule extraction (**SMILE**). This is a flapless procedure in which an intrastromal lenticule is created and corneal tissue is disrupted with a femtosecond laser and removed manually via a <4-mm vertical side cut.

Different Types Of Refractive Surgery

Patients tend to consider LASIK due to dry eye symptoms caused from wearing contact lenses (Toda 2002).

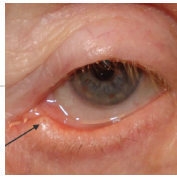
Long-term contact lens user frequently showed chronic ocular surface inflammation with conjunctival infiltration of lymphocytes (Rodriguez et al. 2007) producing changes in ocular surface morphology, tear film composition, and corneal sensitivity (Ambrosio et al. 2008).

After LASIK, even until 6 months, corneal sensitivity and tear secretion have been found more depressed preoperatively in long-term contact lens wearers (Benitez-Del-Castillo et al. 2001).

Preexisting dry eye does not affect the efficacy and safety of LASIK (Toda 2002). However, tear function and ocular surface condition (determined by Schirmer test, TBUT and fluorescein staining) were compromised after LASIK in patients with dry eye compared to patients without (Toda 2002).

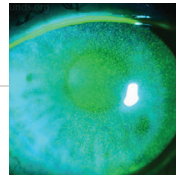
The Key Clinical Signs and Symptoms of DED Following Laser Refractive Surgery (LASIK)

(Toda 2018; Versura et al. 2018)



Irritation, burning, dryness, foreign body sensation and epiphora.

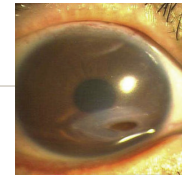
Ocular discomfort.



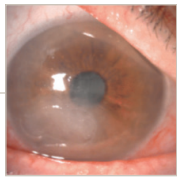Positive vital staining of the ocular surface, by fluorescein, and lissamine green.

Tear breakup time (TBUT) is shortened in almost all cases within 1 week after surgery, and this continues for 3 months on average.

Basic tear secretion determined by the Schirmer test is found to significantly decrease postoperatively over 6 months.



Loss of corneal sensitivity may compromise blink reflex, delay epithelial wound healing, and induce neurotrophic keratitis or sterile corneal melts.



Hypoesthesia, delay in corneal epithelialization, neurotrophic ulcers and chronic inflammation or aberrant hyperesthesia during nerve regrowth, in case of neuroma occurrence.

Keypoint

Pre-existing dry eye is the most significant risk factor for developing severe ocular dryness after LASIK [Cohen, and Spierer 2018].

Patients with pre-existing dry eye symptoms should be warned that their symptoms may persist after LASIK [Toda, 2002].

Several risk factors have been associated with the development of dry eye symptoms following LASIK as depicted in the schematic below (Cohen and Spierer 2018).

<p>! Pre-existing DED</p>	<p>! Previous blepharoplasty, Lagophthalmos</p>	<p>! Diabetes Mellitus, Medication use</p>
	<p>! Higher refractive Correction, Contact Lens wearing</p>	<p>! Ablation depth, Hinge location, Suction time</p>

Pathogenic Mechanisms of DED Following Corneal Refractive Surgery

LASIK is the model of iatrogenic neurotrophic epitheliopathy and is the one that is most commonly reported as inducing DED. Multiple pathways have been suggested for the occurrence of DED following LASIK (Figure 14).

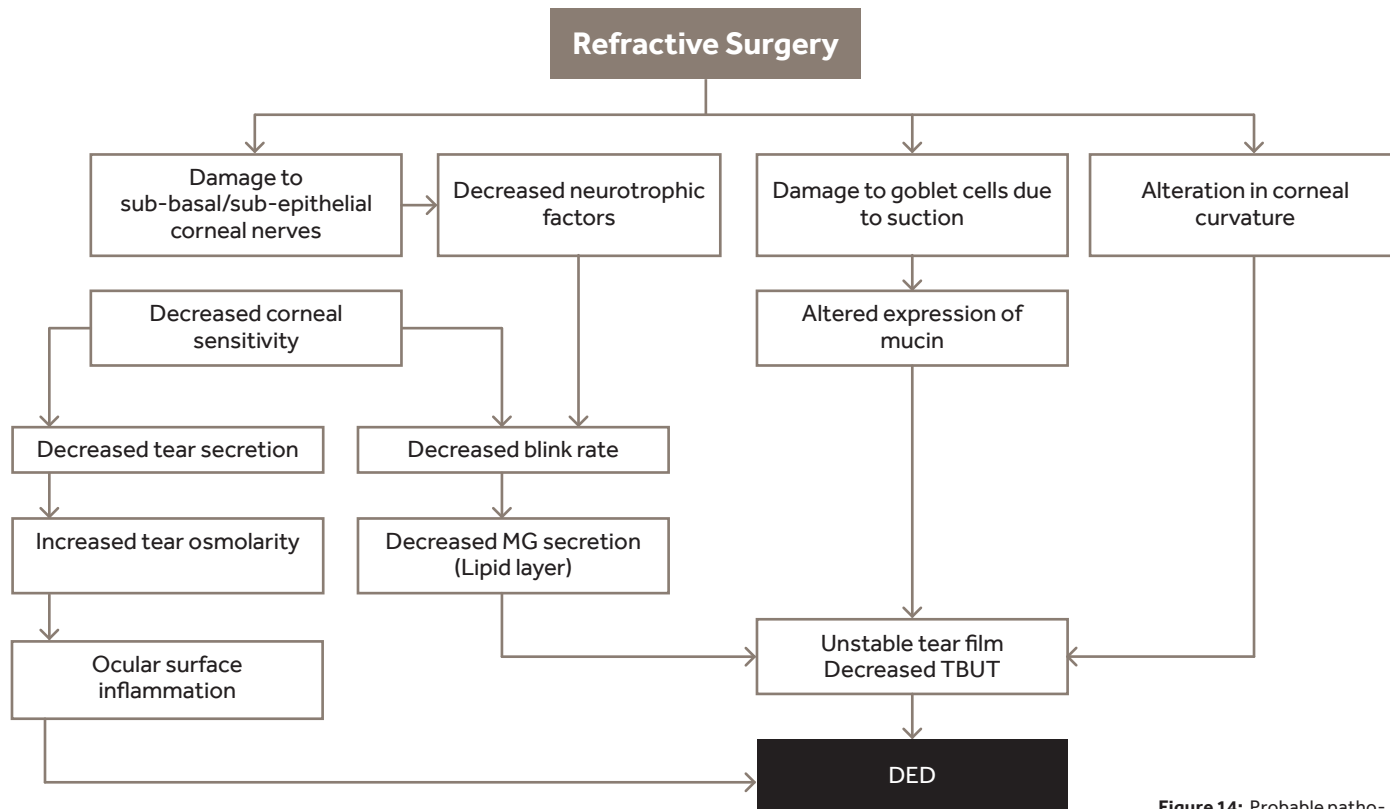
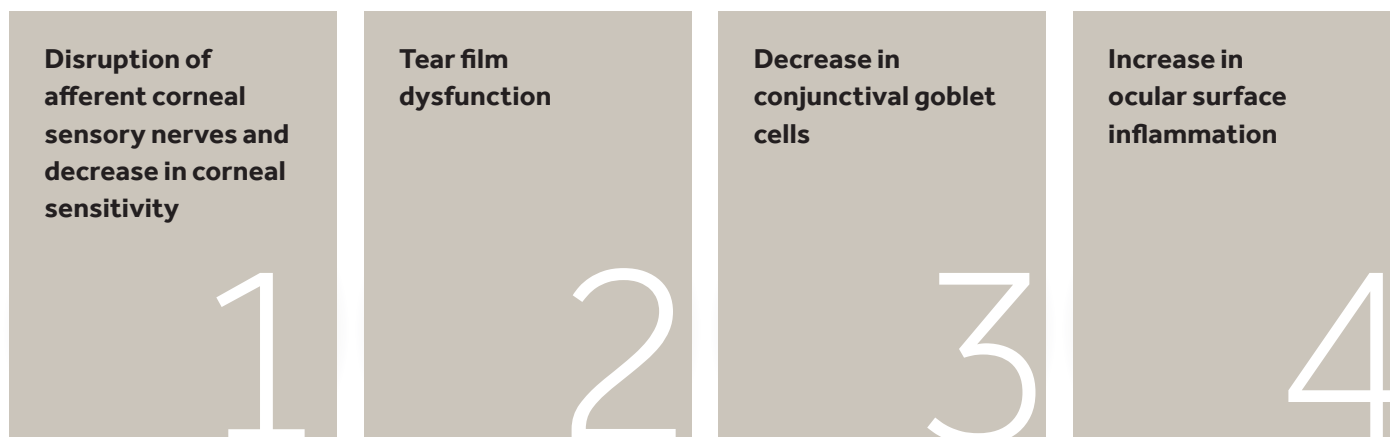


Figure 14: Probable pathophysiology of post-refractive surgery dry eye disease (D'Souza et al. 2020).

Nevertheless, the pathophysiologic basis of post-LASIK dry eye can be summarized into four main mechanisms, as shown in the schematic below: (Tong et al. 2013).

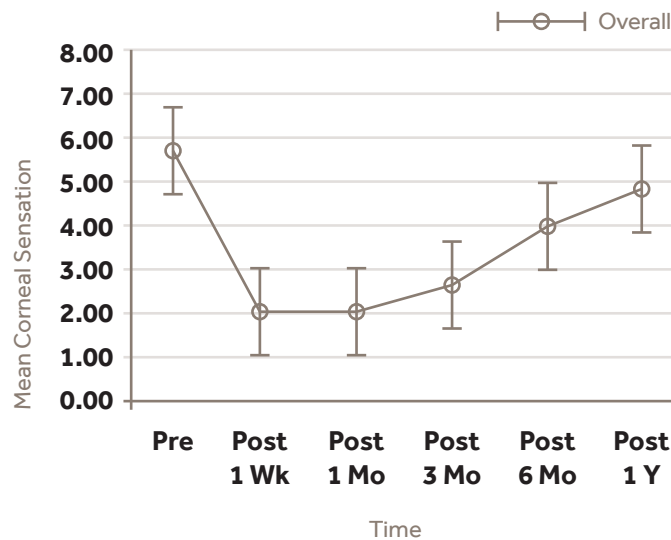


Corneal sensitivity

Corneal sensitivity decreases significantly for 3 months after LASIK. Observation of the intracorneal nerves with a confocal microscope revealed that regeneration of nerve fibers occurred within 3 to 6 months after LASIK (Tong et al. 2013).

Postoperative dry-eye symptoms were increased over preoperative values at 1 week, 1 month, and 3 months. The symptoms normalized to preoperative levels after the 12-month postoperative evaluation (Figure 15, (Mian et al. 2009).

Mean corneal sensation / time



Mean OSDI score / time

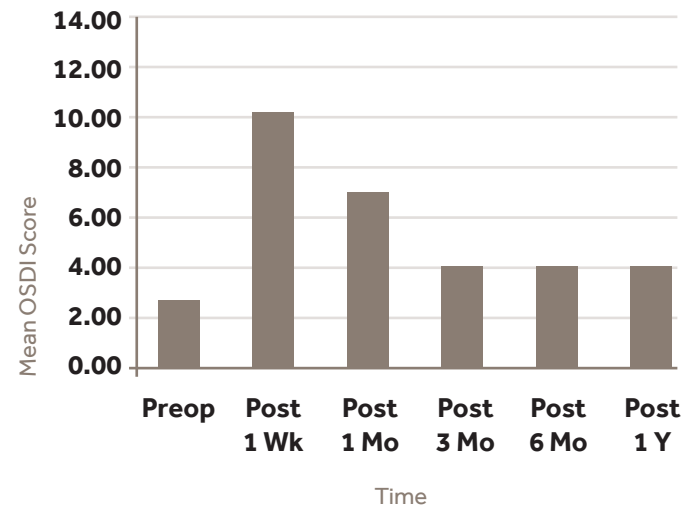


Figure 15: Correlation between corneal sensation and ocular symptoms in LASIK patients. Mean corneal sensation measured with Cochet-Bonnet esthesiometry and mean OSDI score (adapted from (Mian et al. 2009).

Disruption of sensory nerves from flap creation and corneal ablation after surgery leads to a decrease in neurotrophic factors and corneal sensitivity (Figure 16).

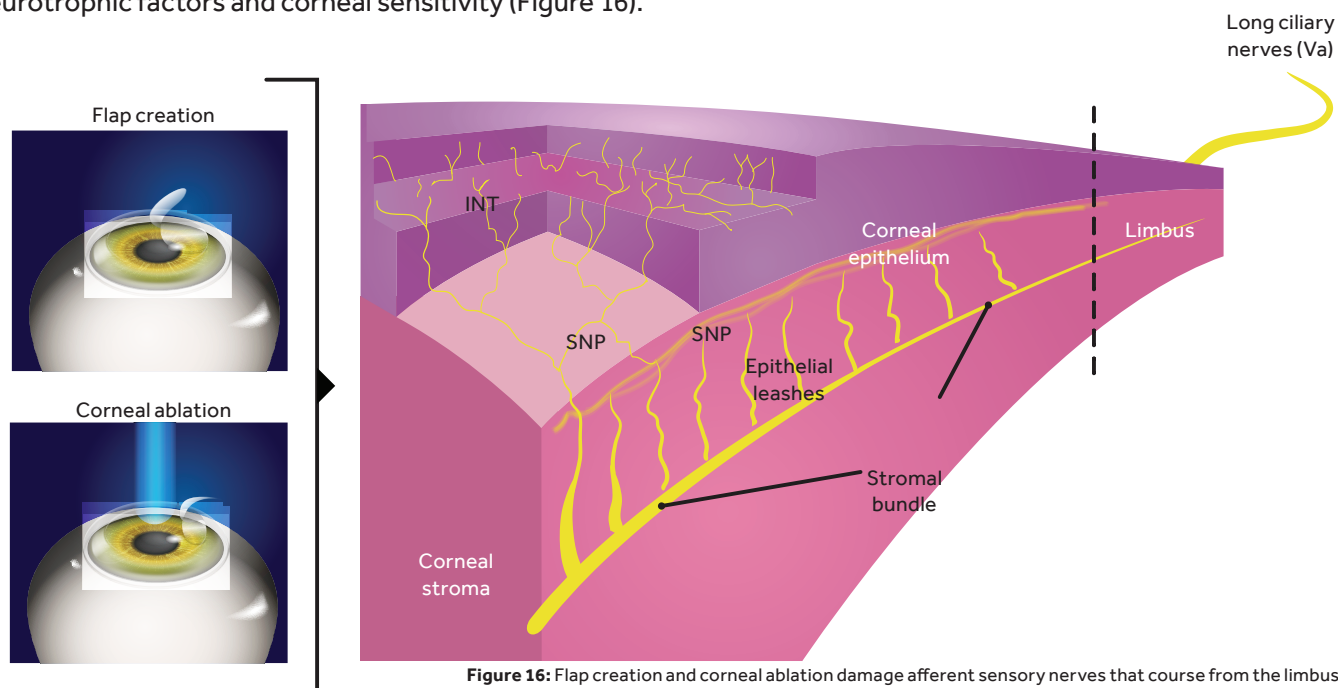


Figure 16: Flap creation and corneal ablation damage afferent sensory nerves that course from the limbus to innervate the stroma and epithelium in the central cornea.

<https://www.eye7.in/lasik-eye-surgery/surface/>, <https://jirehdesign.com/stock-eye-illustrations/eye-surgery/refractive-corneal-surgery/lasik-flap-illustration-surl0001/>. The cornea is the most densely innervated tissue in the body. Intraepithelial nerve terminals (INT) innervate all corneal epithelial layers. Nerve terminals are branches from a continuous subbasal nerve plexus (SNP), which originate from the anastomosis of epithelial leashes in the central and paracentral cornea. Epithelial leashes are subbasal nerve fibers branched from stromal nerves that penetrate into the cornea from the corneoscleral limbus (Gonzalez-Andrades et al. 2019).

Tear film dysfunction

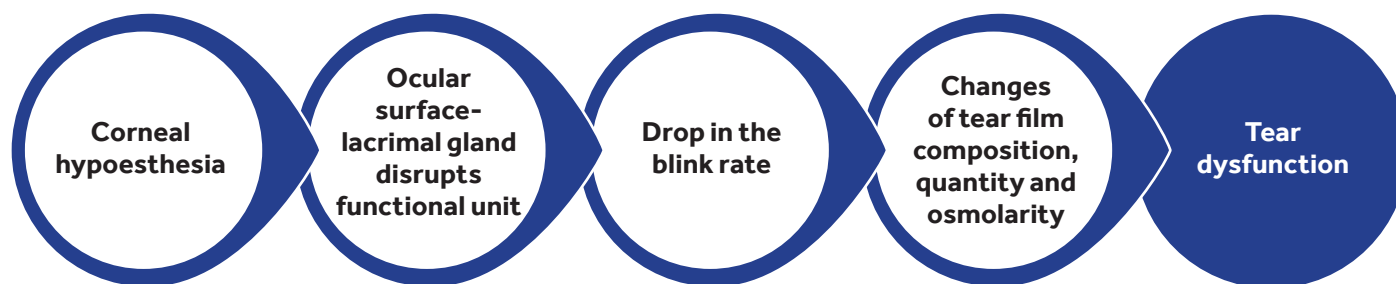


Figure 17: Corneal hypoesthesia after LASIK disrupts the function of the lacrimal gland leading ultimately to tear dysfunction and symptoms of DED (constructed from *(Nettune and Pflugfelder 2010; Toda 2018)*).

Tear secretion (tested by the tear function index) and corneal sensitivity (tested using the Cochet-Bonnet esthesiometer) after LASIK were significantly reduced during the first 3 months after surgery. Tear secretion returned to its preoperative values only after 9 months (Table 4).

Table 4: Mean values of tear film index and corneal sensibility after LASIK surgery

	Tear film index	Corneal Sensibility (mm)
Preoperative	265 ± 488	61.6 ± 1.7
1 week	167 ± 265*	25.4 ± 16.6*
1 month	54 ± 144*	11.6 ± 7.2*
3 months	179 ± 203*	29.4 ± 13.8*
6 months	233 ± 415	58.6 ± 3.2
9 months	256 ± 509	62.0 ± 0.0

* p<0.001 compared to the preoperative value. Adapted from *(Benitez-Del-Castillo et al. 2001)*.

Reduction of conjunctival goblet cells

Patients underwent a decrease in goblet cell density (GCD) after LASIK which recovered after 6 months. At 1 week and 3 months, the femtosecond laser (IL) group showed a greater decrease in the GCD than did the microkeratome (M2) group (Figure 18).

The high pressure induced by the suction ring during LASIK may damage the conjunctival goblet cells, thus altering corneal curvature and the mucin layer of the tear film (Toda 2018).

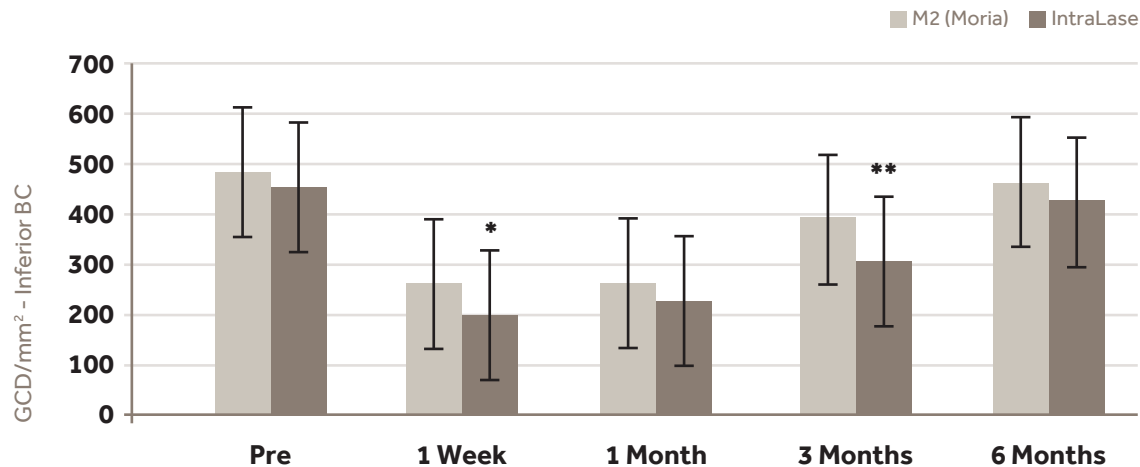


Figure 18: Variation in goblet cell density (GCD) in the inferior temporal bulbar conjunctiva (BC) after LASIK either with femtosecond laser (IL) or microkeratome (M2). Pre: Preoperatively, *P < 0.039 and **P < 0.027, respectively. Adapted from (Rodriguez et al. 2007).

Inflammatory changes

Tear hyperosmolarity causes inflammation via epithelial stress signaling leading to accumulation of inflammatory mediators (substance P, neuropeptide Y, Interleukin (IL)-1, IL-6, IL-8, matrix metalloproteinase (MMP)-9), whose suppression, after refractive surgeries, downregulate corneal epithelial proliferation, integrity,

and wound healing through the degranulation of mast cells and recruitment of polymorphonuclear leukocytes and monocytes/macrophages to the ocular surface. This contributes to postoperative corneal hypoesthesia and dry eye symptoms (Figure 19).

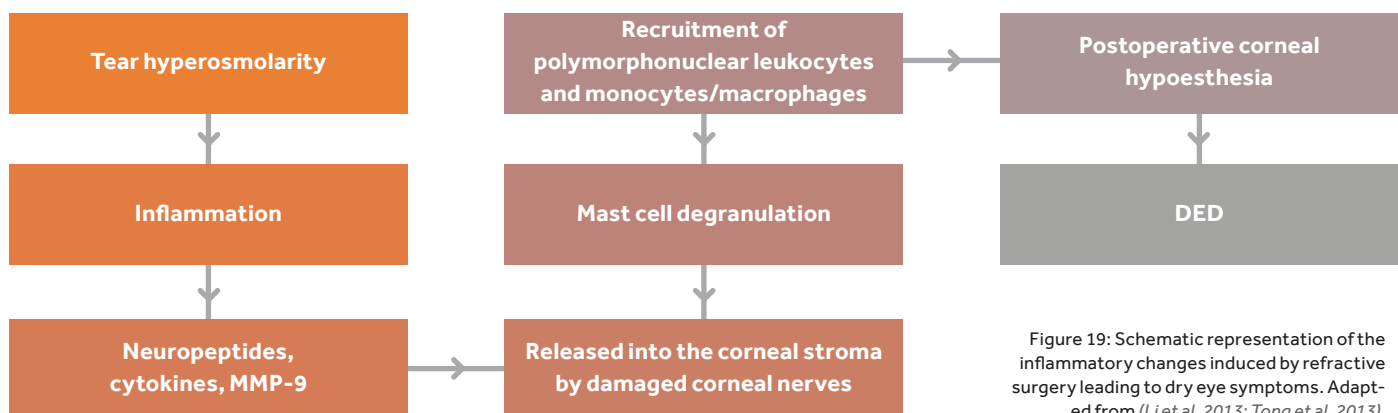


Figure 19: Schematic representation of the inflammatory changes induced by refractive surgery leading to dry eye symptoms. Adapted from (Li et al. 2013; Tong et al. 2013).

Management of DED pre-, intra- and post-operative LASIK

Various parameters have been developed to manage dry eye symptoms before, during or after LASIK.

Preoperative management includes measurement of refractive preoperative properties of the eye and administration of topical 0.05% cyclosporine A either alone or in conjunction with preservative-free eye drops, dietary omega 3 fatty acids, and if needed, insertion of silicone punctal plugs (Ambrosio R et al. 2008; Starr et al. 2019a).

Intraoperative management is associated with ablation depth, suction time, hinge location, and lubrication with substances of low coefficient of friction (Albietz et al 2003; Rodriguez et al. 2007; Sambursky and O'Brien 2011; Toda 2002).

Postoperative management includes topical administration of preservative-free tears and when necessary, of antibiotics and/or corticosteroids. Punctal occlusion may also be considered (Cohen and Spierer 2018; Sambursky and O'Brien 2011; Shtein 2011; Toda 2018).

Preoperative management

The preoperative management includes clinical examination as well as assessment of signs and symptoms to evaluate whether to proceed or delay the surgery (Figure 20).

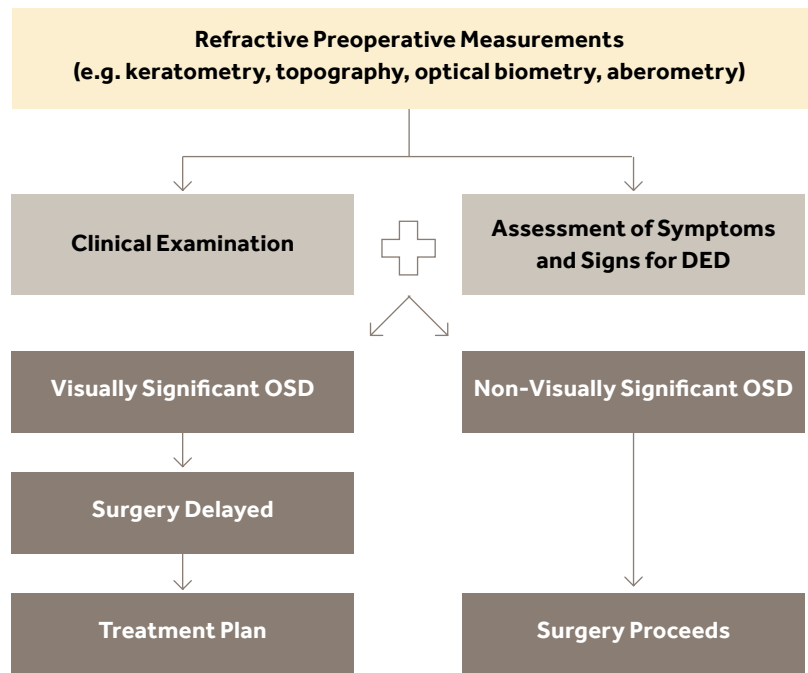
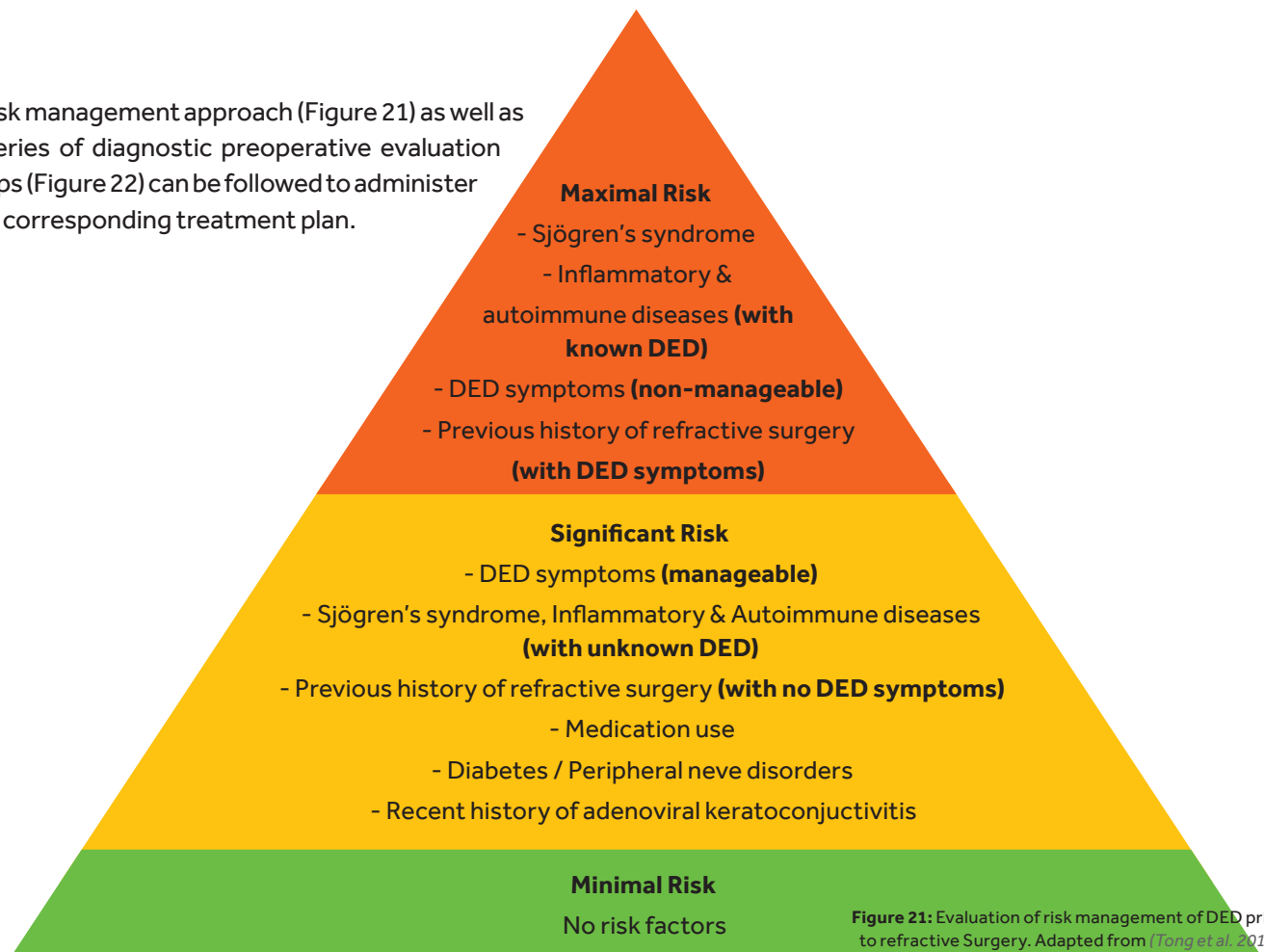


Figure 20: Ocular surface clinical examination algorithm before refractive surgery.

Common approaches for managing DED symptoms before LASIK surgery include the following:

Preservative-free tears	Insertion of permanent or transitory punctal plugs	Dietary supplementation with omega-3 fatty acids	Tear gel or ointment at bedtime

A risk management approach (Figure 21) as well as a series of diagnostic preoperative evaluation steps (Figure 22) can be followed to administer the corresponding treatment plan.



History and slit-lamp examination

History of pre-existing dry eyes, contact lens intolerance, allergy, medication use (diuretics, anticholinergics, antidepressants, antihistamines).

Eyelid disease, tear volume, tears debris, conjunctiva and corneal injection, fluorescein staining.

Patient questionnaire

Validated questionnaires like the Ocular Surface Disease Index (OSDI), Dry Eye Questionnaire (DEQ-5) and Impact of Dry Eye on Everyday Living (IDEEL) are useful to preoperatively pick up symptomatology.

Ocular surface assessment

Evaluation of eyelids including meibomian glands, blink patterns, tear film, conjunctiva and cornea.

Routine tests including tear meniscus height, schirmers test tear break time and ocular surface staining using fluorescein or lissamine.

Advanced Diagnostic Modalities

Tear Film Interferometry: It measures lipid layer thickness (LLT) and lipid layer breakup.

In vivo Confocal microscopy (IVCM): It delineates cellular changes. Useful in following up number and density of sub-basal and stromal nerve cells, micro-neuromas, irregular branching and increased corneal dendritic cell density.

Inflammatory biomarkers: Identification and quantification of the inflammatory markers related to ocular surface inflammation (e.g. matrix metalloproteinase, MMP9).

Other include: Meibometry for oil gland assessment; Osmometry for tear osmolarity assessment.

Figure 22: Series of diagnostic preoperative DED evaluation steps in patients undergoing refractive surgery. Adapted from (Labetoulle et al. 2019; Toda 2018; Tong et al. 2013).

Intraoperative risk factors

for developing post-LASIK dry eye and management include (Lenton and Albietz 1999; Rodriguez et al. 2007; Sambursky and O'Brien 2011; Toda 2002):

Ablation depth

- Ablation depth and higher myopic refractive corrections positively correlate with decreased corneal sensitivity [Sambursky & O'Brien, 2011].
- Deeper ablation associated with reduction of corneal sensitivity whereby delayed recovery of corneal nerves may be responsible for tear deficiency [Toda, 2002].

Suction time

- Longer suction time may affect ocular surface and induce inflammatory changes.
- The post-operative inflammation may be more severe after femtosecond laser than after microteratome [Rodriguez, 2007].

Hinge Location

- Studies have reported conflicting results regarding the effects of hinge location on development of post-LASIK corneal hypoesthesia and dry eye. The initial assumption of more nerves cut in a superior hinge has not been proved and currently, the majority of LASIK are done with a superior and not nasal hinge.
- Further research is needed to determine the effect of corneal flap hinge position, hinge angle, and thickness on corneal sensation or dry-eye syndrome [Sambursky & O'Brien, 2011].

Lubricate with substances of low coefficient of friction

- The amount of ocular surface trauma encountered during the LASIK procedure can be reduced through the use of appropriate lubricants to maintain hydration and surface integrity of the cornea.
- In a retrospective study, eyes that received preservative-free CMC 0.5% prior to LASIK flap cut and a combination of CMC and balanced salt solution during the flap cut had a significantly lower incidence of epithelial defects compared to eyes that received no lubrication during surgery [Lenton & Albietz, 1999].

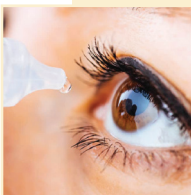Post-operative management

Postoperative regimens include topically applied antibiotics, corticosteroids, anti-inflammatory, and oral analgesic. Therefore, it is the decision of the operating surgeon to use any or all of these products singly or in combination (Shtein 2011).

Generally, treatment after LASIK surgery consists of 2 types of eye drops administered topically: antibiotic and cortisone for 2-4 weeks and preservative-free artificial tears for 1-3 months.

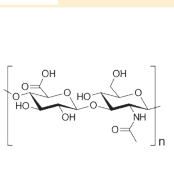
When LASIK-induced dry eye occurs, the following treatments are effective in the majority of patients (Figures 23 & 24):

Preservative-free eyedrops on DED AFTER LASIK



- In an interventional prospective study we compared conventional treatment (dexamethasone and topical tobramycin) with HA 0.15% (Hyabak®, THEA STUDY, Clermont-Ferrand, France) in one group and Hyabak® plus 3% trehalose (Thealoz®, THEA STUDY, Clermont-Ferrand, France) in the other group [Mateo et al 2017].
- We obtained statistically significant differences in postoperative quality-of-life tests and vital stains, TBUT and dry eye symptoms for the group treated with 3% trehalose as an adjuvant after LASIK [Mateo et al 2017].
- In a randomised clinical study, preservative-free CMC-HA-containing formulation relieved post-LASIK ocular dryness showing advanced management of postoperative signs and symptoms of dry eye [Wallerstein et al 2018].

Figure 23: Examples of studies examining preservative-free eye drops on dry eye symptoms following LASIK (Mateo et al. 2017; Wallerstein et al. 2018).



Artificial tears and Osmoprotectants

Preservative-free tears are the initial therapy, especially in sensitive postoperative eyes (*Shtein 2011*).

Punctal occlusion

If artificial tears are not effective, intensive care with punctal plugs are considered for the treatment of post-LASIK dry eye, improving goblet cell density (*Albietz et al. 2003; Quinto, Camacho, and Behrens 2008; Toda 2018*).

If significant superficial punctate keratitis is present for more than 1 week to 2 months postoperatively, punctal plugs can be placed in addition to administration of cyclosporine 0.05% and add a tear ointment at bedtime (*Alfawaz et al. 2014; Toda 2018*).

Contact lenses and Ointments/Eye Patches

Scleral gas permeable contact lenses have been shown to improve comfort in patients with post-LASIK dry eyes (*Shtein 2011*).

Preservative-free artificial tears

Patients treated with unpreserved artificial tears for 60 days post-operatively, no signs or symptoms of dry eye were detected until 60 days after surgery

Artificial tears are recommended to be used for at least 90 days [*Hassan, 2013*].

Punctal Occlusion

A randomised study confirmed that punctal occlusion was effective in patients with post-LASIK dry eye that cannot be controlled by artificial tears alone [*Yung, 2012*].

In individuals with moderate DED for 3 weeks, punctal occlusion resulted in reduced corneal fluorescein staining and symptom scores, without elevation of cytokine or matrix metalloproteinase (MMP)-9 levels [*Tong et al, 2016*].

Contact lenses and Ointments/Eye Patches

Bandage soft contact lenses can be used in patients with normal tear production following LASIK to reduce fluctuating vision and ocular irritation until the corneal nerves regenerate [*Ambrosio, 2008*].

Use of ointment and eye patches at bed time for a month after LASIK help prevent complications such as epithelial defects, recurrent erosion, delayed wound healing of the flap edge, and epithelial ingrowth, which in turn induce severe symptoms [*Toda, 2018*].

Figure 24: Examples of studies applying preservative-free tears, osmoprotectants, punctal occlusion and eye patches to reduce or eliminate dry eye symptoms following refractive surgery (*Ambrosio R et al. 2008; Hassan et al. 2013; Toda 2018; Tong et al. 2016; Yung et al. 2012*).

Antibiotics

Doxycycline and azithromycin are known for their therapeutic efficacy in treating post-LASIK DED by inhibiting MMP-9 activity in human corneal epithelial cells and for preventing from infection in postoperative period, such as patients who develop persistent neurotrophic keratopathy after LASIK (*Sambursky and O'Brien 2011*). In addition, clinical studies have demonstrated efficacy of azithromycin and doxycycline in improving blepharitis signs and symptoms (*Kagkellaris et al. 2018*).

Anti-inflammatory therapy

Treatment with artificial tears may not be sufficient to improve outcomes after surgery and treatment with anti-inflammatory eye drops may be used to treat post-LASIK dryness, inflammation, and neurotrophic epitheliopathy (Cohen and Spierer 2018).

Anti-inflammatory therapy (steroids)

Upon topical administration of 1% nonpreserved methylprednisolone, patients with severe dry eye demonstrated relief from irritation [Marsh, 1999; Quinto et al. 2008].

While topical steroids may have the most rapid anti-inflammatory action, treatment is not advisable for long-term due to side effects, especially cataract formation and glaucoma [Quinto et al. 2008].

Autologous serum

Application of topical autologous serum diluted to 20% with physiological saline has been proposed as a safe and effective treatment for dry eye after LASIK [Ambrosio et al. 2008]. However, routine use of autologous serum is not recommended because of a higher risk of infection and a potential development of epithelia hyperplasia associated with refractive regression.

Application of nondiluted autologous serum eye drops could be used as an adjuvant therapy for promoting the epithelial healing process during the repair stage of corneal alkali wounds [Salman & Gunodogdu 2010].

Anti-inflammatory therapy (Cyclosporine A 0.05%)

In a randomized trial, administration of cyclosporine A for 1 month prior to LASIK and 3 months after LASIK resulted in improved refractive results compared with artificial tears [Salib et al. 2006].

A retrospective study showed that cyclosporine was effective in treating postoperative dry eye following LASIK in patients who did not have preoperative symptoms or signs of dry eye [Kanellopoulos 2019].

A prospective, randomized study showed that cyclosporine significantly improved corneal sensitivity and visual acuity at 3 months after LASIK [Peyman et al. 2008].

Figure 25: Examples of studies demonstrating improvement in DED following LASIK with application of anti-inflammatory, autologous serum and DQS treatments (Ambrosio R et al. 2008; kanellopoulos 2019; Marsh 1999; Mori et al. 2014; Peyman GA et al. 2008; Quinto et al. 2008; Salib, McDonald, and Smolek 2006; Salman and Gündoğdu 2010; Toda et al. 2014).

Diquafosol tetrasodium (DQS)

The 3% DQS ophthalmic solution in patients with dry eye following LASIK showed to be more effective either alone or in combination with Hyaluronic acid compared to conventional therapy using artificial tears or sodium hyaluronate [Koh 2015; Mori et al 2014; Toda et al 2014].

Dry eye symptoms were significantly improved upon administration of 3% DQS and 0.3% HA compared with HA or DQS alone in post-LASIK patients 1 week after surgery [Toda et al. 2014].

Symptoms of dryness, and discomfort significantly improved after additional 3% DQS treatment compared to artificial tears and HA treatment alone at 1, 4 and 12 weeks post LASIK (Mori et al. 2014).

Neuropathic ocular pain after LASIK: implications for prevention and treatment of persistent symptoms

Transient dry eye symptoms have been reported following LASIK. Very rarely, patients may present with debilitating symptoms of dry eye with limited or no evidence of ocular surface disease. These patients are diagnosed with a form of DED known as neuropathic corneal pain (Moshirfar et al. 2021).

Accepting that neuropathic ocular pain is thought to at least partially underly persistent dry eye symptoms after LASIK, opens a new realm of possibilities for prevention and treatment (Levitt et al. 2015).

However, no studies have been conducted to comprehensively evaluate pharmacological treatment efficacy for the prevention of persistent ocular pain following LASIK (Levitt et al. 2015).

Gabapentin and pregabalin (referred to collectively as "gabapentinoids") are mainstays in the treatment of neuropathic pain (Levitt et al. 2015).

A retrospective medical record review of a case series of 18 patients who developed neuropathic corneal pain post-LASIK revealed that patients benefited from proper diagnosis and a multimodal approach to treatment, including gabapentinoids (Moshirfar et al. 2021).

Incidence of DED Pre-, Intra- and Post-Corneal Refractive Surgery

The schematics below highlight the incidence of developing dry eye symptoms after LASIK surgery as well as after PRK, FS-LASIK and SMILE in comparison with LASIK (Bower et al. 2015; Kobashi et al. 2017; Levitt et al. 2015; Li et al. 2013; Murakami and Manche 2012; de Paiva et al. 2006; Reinstein et al. 2014; Salomão et al. 2009; Sambhi et al. 2020; Shen et al. 2016; Shtein 2011; Toda 2002, 2018; Tong et al. 2013; Yu et al. 2000).

Additionally, the impact of dry eye before LASIK is also described.

Incidence of DED Following LASIK

Yu et al, 2000

DED after LASIK appeared in 94.8% of patients at 1 day , 85.4% at 1 week, and 59.4% at 1 month after surgery.

De Paiva et al, 2006

Approximately 50% of patients at 1 week, 40% at 1 month, 20% at 3 months and 10-40% at 6 months had dry eye symptoms after LASIK surgery.

Bower et al 2015

Transient dry eye occurred in 13.8% of patients after surgery and chronic dry eye (6 or 12 months) in only 0.8%.

Shtein 2011

A small proportion of patients may develop chronic and severe dry eyes that can be quite refractory to traditional dry eye treatments.

Immediately after LASIK, 95% of patients reported some dry eye symptoms with 60% of them 1 month after LASIK.

Levitt et al 2015

20-55% of patients after surgery had persistent symptoms after 6 months as summarized in Table below.

Study	Procedure	N	Designs	Definition	Incidence
Denoyer et al, 2014	LASIK	0	Prospective series	Use of eye drops at 6 months	43%
De Paiva et al, 2006	LASIK	35	Prospective randomized (nasal vs. superior hinge)	Fluorescein staining score of 3 or more at 6 months	36.4% (overall)
Shoja et al, 2007	LASIK	95	Retrospective series	Subjective symptoms at 6 months	20%
Donnefeld et al, 2003	LASIK	52	Prospective randomized (nasal vs. superior hinge)	Patients reporting eyes drier than before LASIK at 6 months	31% (overall)
Tuisku et al, 2007	LASIK	20	Retrospective case-control	Subjective symptoms at 2-5 years	55%

Incidence of DED Following FS-LASIK (vs LASIK)

Salomao et al 2009

Incidence of dry eye at one month after surgery was significantly higher in the microkeratome group (46%) than in the femtosecond group (8%).

The need for postoperative cyclosporine A treatment after one month was also significantly higher in the microkeratome group than in the femtosecond group (24% and 7%, respectively).

Incidence of DED Following PRK (vs LASIK)

Tong et al 2013

LASIK tends to enhance tear dysfunction with less dry eye symptoms while PRK causes more severe dry eye symptoms with less tear dysfunction.

Bower et al 2015

After LASIK, significant changes were observed in TBUT, corneal sensitivity, ocular surface staining, and responses to questionnaire. Chronic dry eye at one year after surgery was 5% with PRK and 0.8% with LASIK procedure.

Murakami & Manche, 2012

PRK eyes tend to have more visual fluctuation at 1 month after surgery possibly due to induced dry eye but that could also be attributable to prolonged central epithelial remodeling after the surface ablation procedure.

Incidence of DED Following SMILE (vs LASIK)

Reinstein et al 2014

After SMILE, less postoperative dry eye is expected compared to LASIK because the anterior stroma is disturbed only by a small incision, thus the anterior corneal nerves are less affected.

Kobashi et al 2017

SMILE produced fewer dry eye symptoms than FS-LASIK.

TBUT was longer in the SMILE than the FS-LASIK group at 1 month and 6 months after surgery.

Corneal sensitivity was significantly higher in the SMILE than the FS-LASIK group at 1 week, 1 month, 3 months, and 6 months after surgery.

OSDI scores were significantly better in SMILE at 6 months postoperatively.

Corneal subbasal nerve density was also significantly higher in SMILE-treated eyes than it was in FS-LASIK-treated eyes at 1 month postoperatively.

Shen et al 2016

DED occurred transiently both after SMILE and FS-LASIK.

TBUT and OSDI score were significantly worse in FS-LASIK than in SMILE at 1 month, 3 months and 6 months.

At 6 months post-operatively, TBUT and TFO values in both groups and OSDI scores in the SMILE returned to post-operative levels. The 2 groups did not differ significantly in terms of Schirmer's I test and tear film osmolarity at any postoperative visits.

Sambhi et al 2019

Significant reduction in postoperative tear production (Schirmer test) and TBUT was shown with LASIK and not SMILE at 6, 12 and 24 months.

Li et al 2013

Decrease in subbasal nerve density was less severe in SMILE-treated eyes than in LASIK at a 1 week, 1 month, and 3 months.

Toda 2018

SMILE is less invasive and reduces the incidence of post-operative dry eye compared to LASIK.

Impact of Pre-Existing DED Before LASIK

Shtein 2011

The prevalence of dry eye symptoms prior to undergoing LASIK is estimated to be between 38 and 75%.

Toda 2002

Tear function and ocular surface condition determined by Schirmer test, TBUT and fluorescein stainings were shown to be more compromised after LASIK in the pre-existing dry eye patients compared to patients without dry eye.

Although the efficacy and safety of LASIK are not affected by preexisting dry eye, this is a risk factor for severe postoperative dry eye with lower tear function.

Summary Keypoints

Pre-existing dry eye may compromise tear function and ocular surface condition after LASIK.

Pathogenic mechanisms for development of DED after refractive surgery include tear film dysfunction, disruption of afferent corneal sensory nerves and decrease in corneal sensitivity, increase in ocular surface inflammation, decrease in conjunctival goblet cells .

It is critical to consider parameters before, during and after surgery to manage dry eye symptoms with the corresponding therapy for each patient.

Preservative-free eye drops show superior outcome in managing dry eye symptoms after refractive surgery .

There is a relatively high prevalence of dry eye symptoms following LASIK which may persist for more than 6 months.

(Cohen & Spierer 2018; D'Souza et al 2020; Sambursky & O'Brien 2011; Toda 2018; Toda 2002; Mateo et al 2017; Mencucci et al 2021)

Cataract Surgery

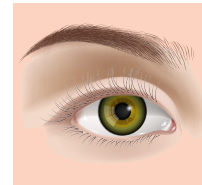
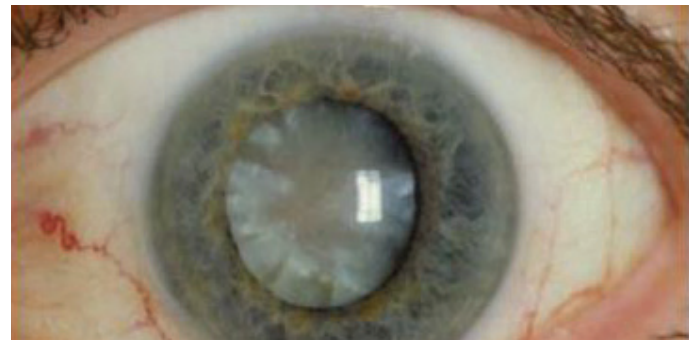What is it?

A cataract is a clouding or opacification of the normally clear lens of the eye or its capsule (surrounding transparent membrane) that obscures the passage of light through the lens to the retina of the eye. In other words, a cataract is a clouding of the crystalline lens inside the eye, which can gradually lead to a decrease in vision (Figure 26, (Nizami and Gulani 2022; Thompson and Lakhani 2015).

This disease can affect infants, adults, and older people, but it predominates the latter group. It can be bilateral and vary in severity. The disease process progresses gradually without affecting daily activities early on, but with time, especially after the fourth or fifth decade, the cataract will eventually mature, making the lens completely opaque to light interfering with routine activities (Nizami and Gulani 2022).

Signs and Symptoms of Cataract

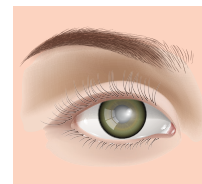
(Thompson & Lakhani 2015; Nizami & Gulani 2021)



Healthy eye



Clear lens



Eye with cataract

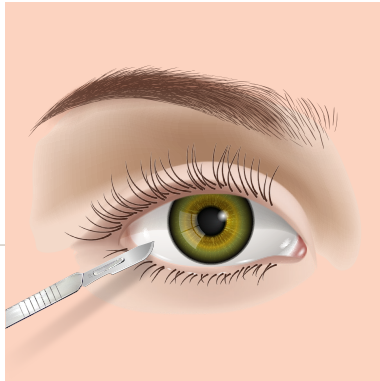


Lens clouded by cataract

- **Blurred, clouded or dim vision**
- **Diplopia or polyopia**
- **Colored halos around the light
Sensitivity to light and glare**
- **Fading or yellowing of colors**
- **Reduced visual acuity**
- **Vision loss**
- **Blindness**

Figure 26: Schematic illustration and patient's photograph of a cataract and the associated signs and symptoms. <https://www.dreamstime.com/cataract-clouding-crystalline-lens-inside-eye-cataract-clouding-crystalline-lens-inside-eye-image103021796>, <https://www.nhs.uk/conditions/cataracts/>, <https://www.mayoclinic.org/diseases-conditions/cataracts/symptoms-causes/syc-20353790>.

It is the most common cause of blindness worldwide, in the developing countries, and is conventionally treated with surgery. Different types of corneal incisions for cataract surgery exist as shown in the schematic below (Li et al. 2018; Shaheen et al. 2020; Shentu et al. 2016).



Standard

Conventional phacoemulsification steps using a microblade:

Creating corneal incisions using a blade or keratome



Capsulotomy



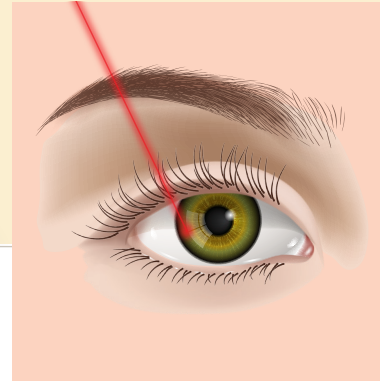
Fragmenting the cataractous lens with ultrasonic energy (emulsification)



Irrigation and suction



Implantation of an intraocular lens (IOL)



Laser-assisted

Femtosecond Laser-Assisted Cataract Surgery (FLACS) uses a laser to:

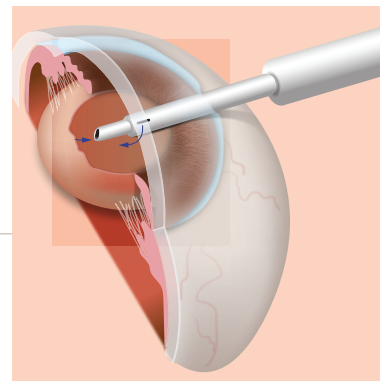
Create an incision in the cornea



Open the cataract membrane or capsules

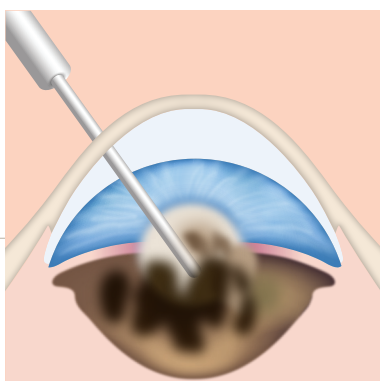


Soften the cataract prior to removal



C-MICS

In coaxial micro-incision phacoemulsification (C-MICS) the incisions are smaller than SICS



SICS

In small-incision cataract surgery (SICS) the incisions are smaller than conventional phacoemulsification

Risk factors

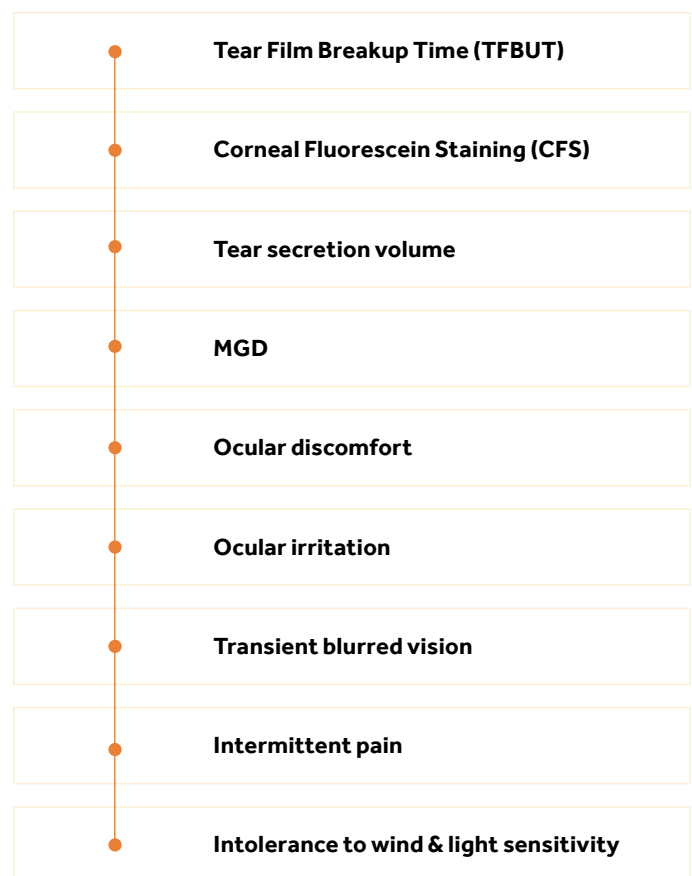
Visual loss occurs because opacification of the lens obstructs light from passing and being focused on to the retina at the back of the eye. Various risk factors are involved in the development of cataract that will necessitate surgery at some point (see table below, (Chang et al. 2011; Nizami and Gulani 2022; Seddon et al. 1995).

Risk factors for developing cataract surgery

(Seddon et al. 1995; Chang et al. 2011; Nizami & Gulani 2021)

Increasing age	Educational status
Sex and estrogen replacement therapy	Medication use (prolonged use of corticosteroid medications)
Diabetes	High blood pressure
Alcohol & Smoking	Obesity
Exposure to ionizing and UV radiation	Previous eye trauma or inflammation
Previous eye surgery (refraction)	

In the schematic below are summarized the signs and symptoms of DED after cataract surgery. Several DED parameters and subjective symptoms occurred 1 week after cataract surgery but reported values ranged from 1 month to 1 year after cataract surgery (Mencucci et al. 2021; Miura et al. 2022).



Keypoints

DED can have a negative impact on patients' quality of life, visual outcome and satisfaction after cataract surgery.

Maintaining a healthy ocular surface is essential for achieving the best visual outcome after cataract surgery.

(Mencucci et al 2021)

Risk Factors and Pathogenic Mechanisms of DED Following Cataract Surgery

Disruption in tear film homeostasis is a key component in the pathogenesis of DED (Figure 27) and there are several pre-, intra- and post-operative risk factors in phacoemulsification cataract surgery which can disturb the tear film stability (Naderi et al 2020) (Figure 27).

Studies have shown that patients previously diagnosed with DED report a worsening of symptoms after uncomplicated phacoemulsification (Mencucci et al. 2021).

Blepharitis is one reason for cancellation of cataract surgery, as it is thought to be a primary risk factor for endophthalmitis (Movahedan and Djalilian 2012; Speaker et al. 1991).

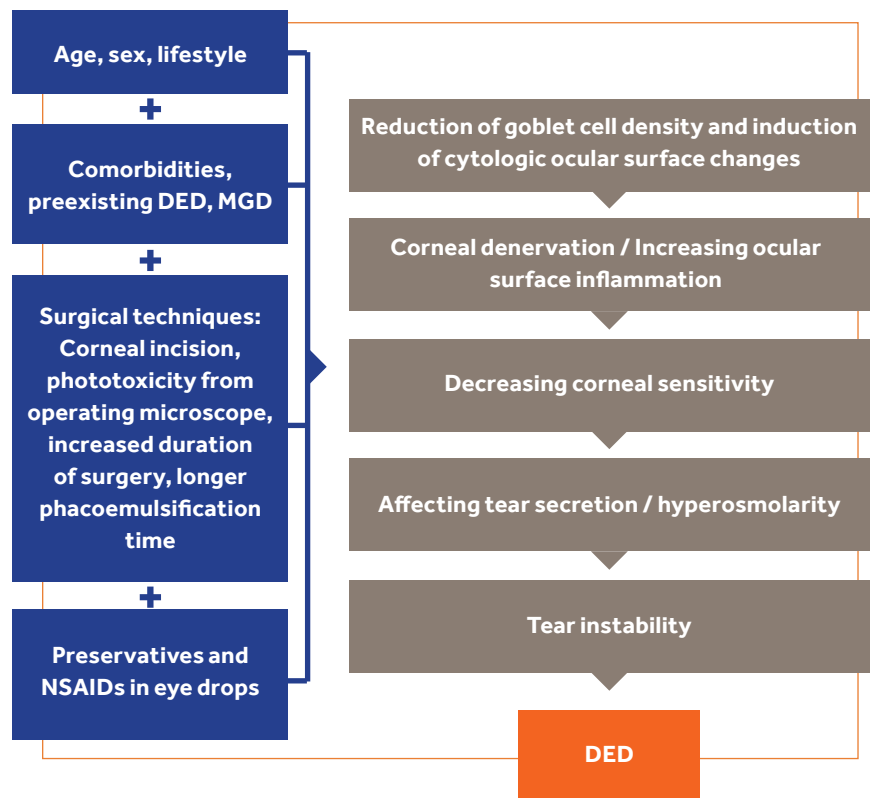


Figure 27: An overview of the pathogenic mechanisms leading to DED following cataract surgery (Mencucci et al. 2021; Naderi, Gormley, and O'Brart 2020).

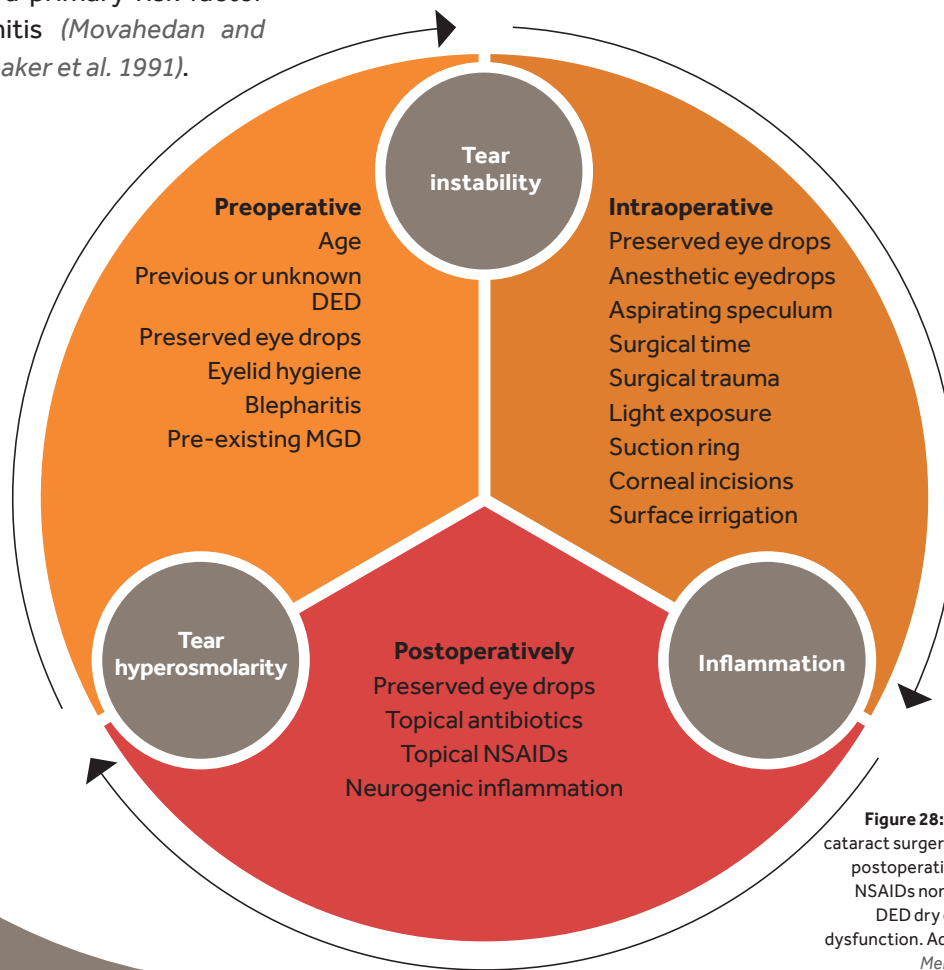
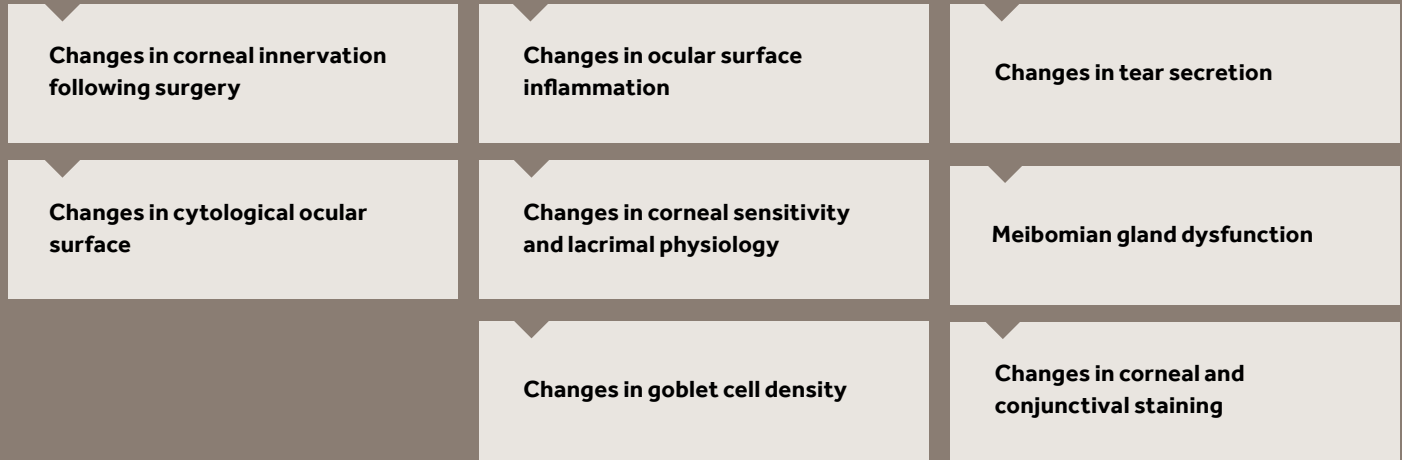


Figure 28: The vicious circle of DED related to cataract surgery and its associated pre-, intra- and postoperative risk factors contributing to DED. NSAIDs nonsteroidal anti-inflammatory drugs, DED dry eye disease, MGD meibomian gland dysfunction. Adapted from (Kasetsuwan et al. 2013; Mencucci et al. 2021; Naderi et al. 2020).

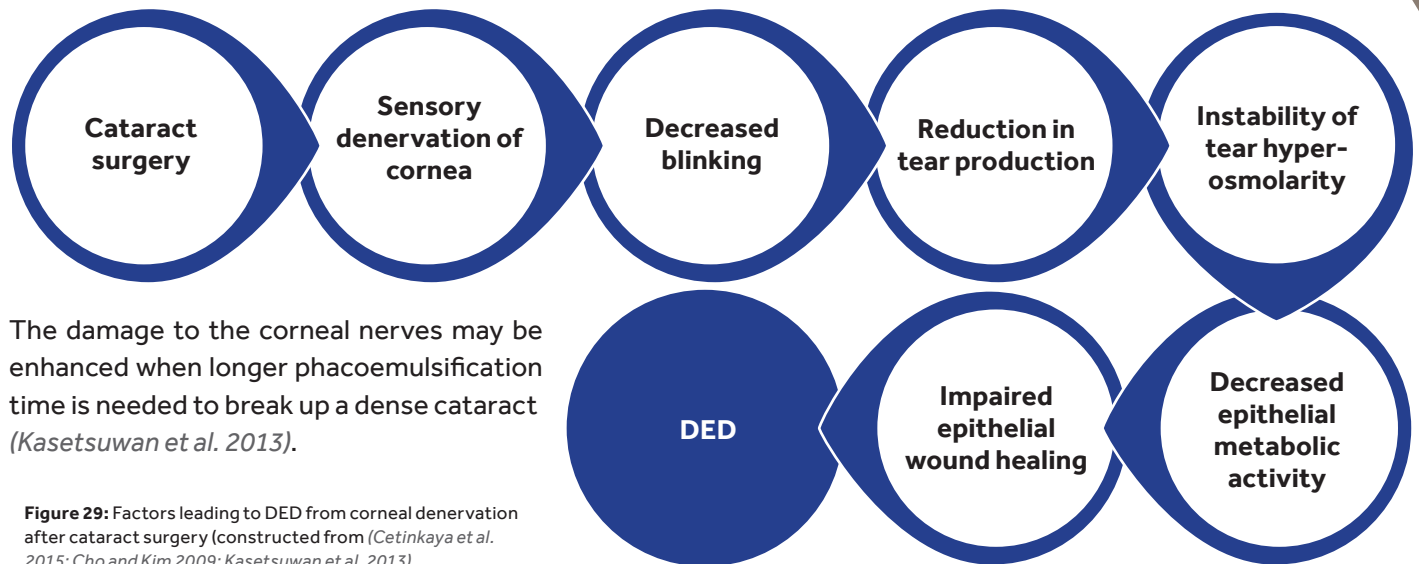
Keypoint

Pre-existing dry eye is a significant risk factor for persistent dry eye after cataract surgery which can be worsened after surgery (Cetinkaya et al 2015).

The schematic below summarizes the associated pathophysiological changes following cataract surgery (Cetinkaya et al. 2015; Gomes et al. 2017; Han et al. 2014; Jiang et al. 2016; Kasetuwan et al. 2013; Khanal et al. 2008; Naderi et al. 2020; Sitompul et al. 2008).



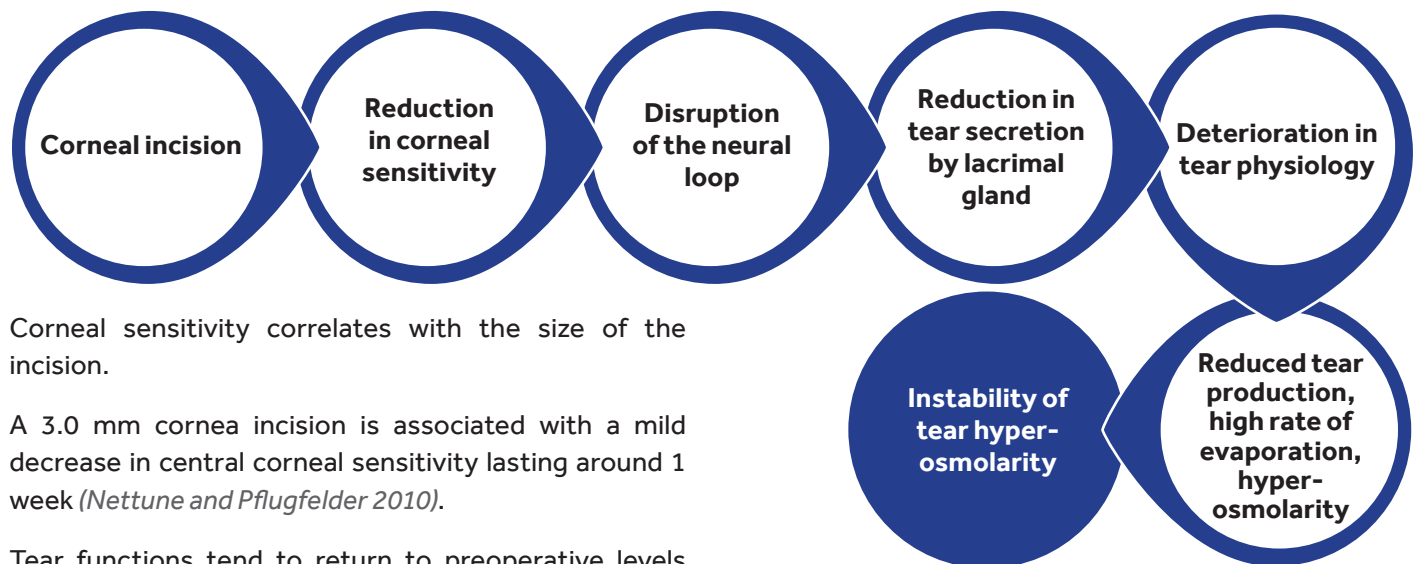
Changes in corneal innervation following surgery



The damage to the corneal nerves may be enhanced when longer phacoemulsification time is needed to break up a dense cataract (Kasetuwan et al. 2013).

Figure 29: Factors leading to DED from corneal denervation after cataract surgery (constructed from (Cetinkaya et al. 2015; Cho and Kim 2009; Kasetuwan et al. 2013)

Corneal sensitivity and lacrimal physiology



Corneal sensitivity correlates with the size of the incision.

A 3.0 mm cornea incision is associated with a mild decrease in central corneal sensitivity lasting around 1 week (Nettune and Pflugfelder 2010).

Tear functions tend to return to preoperative levels within 1 month after surgery while corneal sensitivity does not return until 3 months after (Cetinkaya et al. 2015; Khanal et al. 2008).

Figure 30: The effects of corneal incision in corneal sensitivity and tear physiology. Constructed from (Kasetsuwan et al. 2013; Sánchez et al. 2010).

Increased ocular surface inflammation

Neurogenic inflammation also can develop after corneal incisions with inflammatory mediators reducing corneal sensitivity and resulting in tear film instability (Cetinkaya et al. 2015; Jiang et al. 2016; Kasetsuwan et al. 2013; Sitompul et al. 2008).

Conjunctival impression cytology demonstrated increased HLA-DR and CD3, characteristic of ocular surface inflammation, one month after phacoemulsification (Sánchez et al. 2010).

Cytological ocular surface changes Squamous metaplasia

Impression cytology studies suggest the presence of serious squamous metaplasia in the epithelial layer of the conjunctiva, especially the lower lid region, at 3 months after cataract surgery (Figure 31).

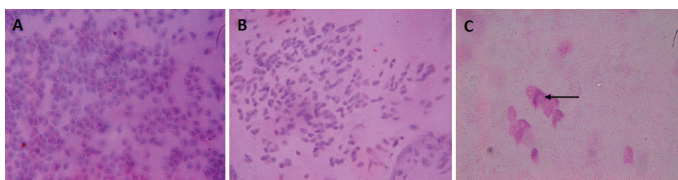


Figure 31: Impression cytology of conjunctival squamous metaplasia. Conjunctival epithelium characterized by (A) normal morphology and nuclear/cytoplasmic ratio, (B) loose intercellular connection, increased gap among epithelial cells and increased nuclear/cytoplasmic ratio, (C) altered (snake-like) chromatin (adapted from (Li et al. 2007).

Goblet cell density

Vigorous irrigation of the tear film and manipulation of the ocular surface intraoperatively can reduce goblet cell density (GCD) postoperatively and exacerbate dry eye symptoms during early recovery (Gomes et al. 2017; Kasetsuwan et al. 2013).

The degree of goblet cell loss and associated conjunctival cell squamous metaplasia is related to operating room time and the length of exposure to the operating microscope light during surgery (Gomes et al. 2017).

Conjunctival impression specimens revealed a statistically significant difference in the mean GCD in 3 ocular regions before and 3 months after cataract surgery (Table 5).

Region	Before surgery	At 3 months
Upper lid covered	474 ± 47	382 ± 244
Explosive	468 ± 229	384 ± 242
Lower lid-covered	466 ± 230	288 ± 223

Table 5: Average density of goblet cells before and 3 months following cataract surgery in 3 ocular regions. Adapted from (Li et al. 2007).

Change in tear secretion

The lacrimal river line became narrower after phacoemulsification in most patients and even dried up in some cases. This phenomenon was most distinct at 1 month after cataract surgery (Figure 32).

No detectable differences were observed in tear production and tear meniscus volume after cataract surgery, suggesting that ocular discomfort cannot be explained by a decrease in tear secretion alone (Han et al. 2014).

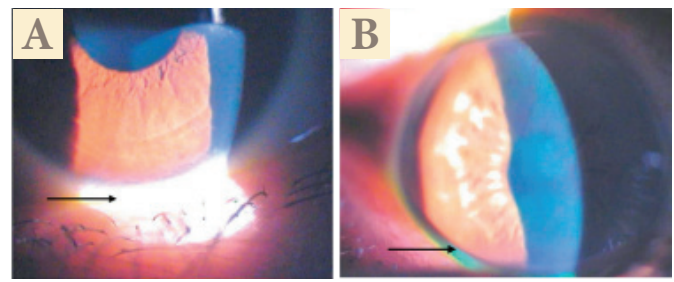


Figure 32: Observation of lacrimal river after phacoemulsification. (A) width became narrow after cataract surgery and (B) width of lacrimal river line is normal before cataract surgery (arrow). Adapted from (Li et al. n.d.).

Meibomian gland dysfunction

Meibomian gland function is frequently altered after cataract surgery without accompanying structural changes. Actually, it is commonly altered before surgery because of the aging process, but will be potentially increased by the surgery (Han et al. 2014).

Lid margin abnormalities were significantly increased, with more than 70% of eyes showing plugging of meibomian gland orifice and vascular engorgement of the lid margin at 1 and 3 months postoperatively (Figure 33).

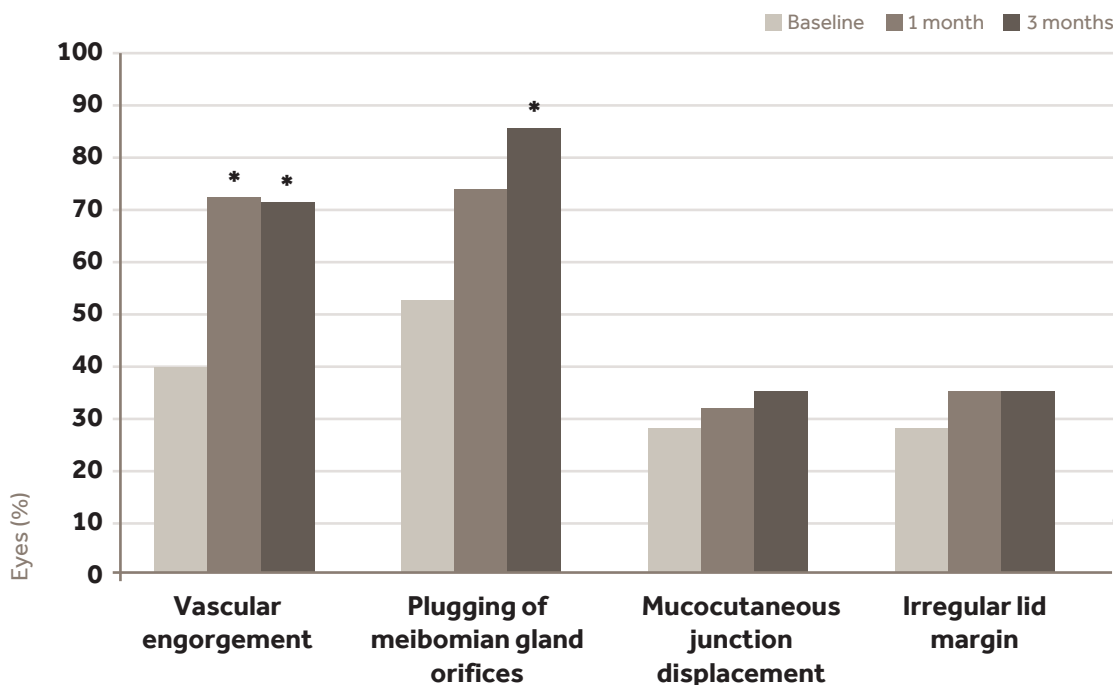


Figure 33: Changes in lid margin abnormalities after cataract surgery. An asterisk indicates p value less than 0.05 when compared with baseline. Adapted from (Han et al. 2014).

Corneal and conjunctival staining

Increased corneal and conjunctival staining was observed after cataract surgery which peaked at 1 month postoperatively. Patients whose cornea and conjunctiva fluorescein staining were positive 1 week after cataract surgery still had positive results 3 months after surgery (Figure 34).

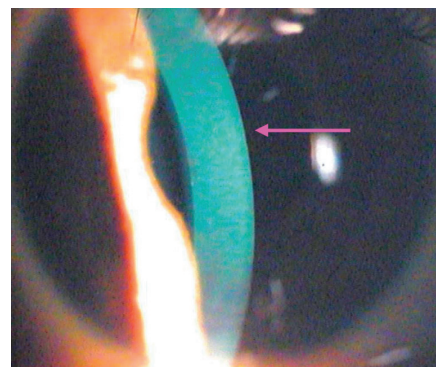


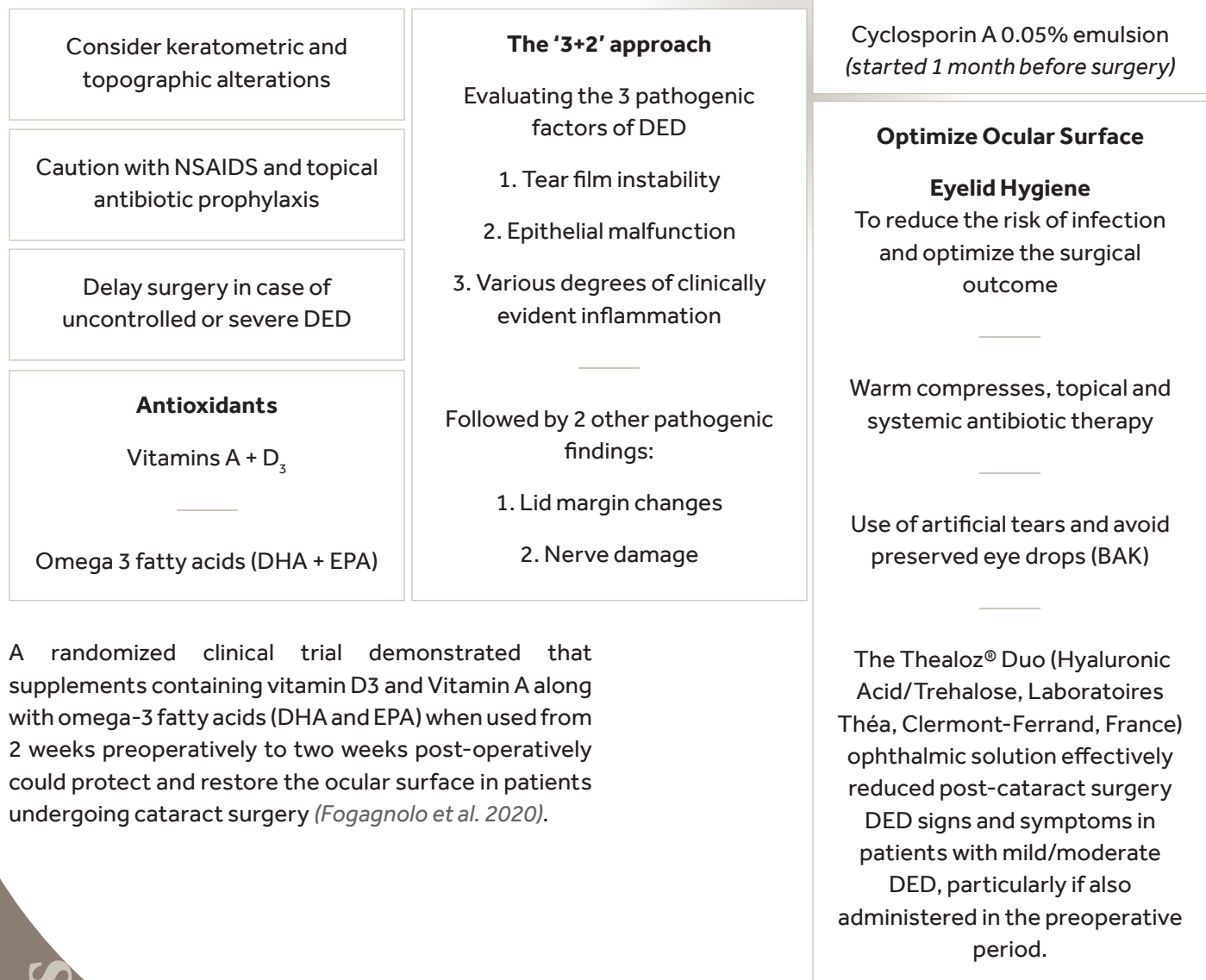
Figure 34: Fluorescein staining spots on cornea and conjunctiva 1 month after cataract surgery. Adapted from (Li et al. 2007).

Management of DED pre-, intra- and post-Cataract Surgery

Preoperative management

Preoperative recommendations for preventing and reducing DED

The schematic below summarizes the different approaches in managing DED symptoms before cataract surgery (constructed from (D'Souza et al. 2020; Hovanesian et al. 2020; Labetoulle et al. 2019; Mencucci et al. 2021; Naderi et al. 2020))



A randomized clinical trial demonstrated that supplements containing vitamin D3 and Vitamin A along with omega-3 fatty acids (DHA and EPA) when used from 2 weeks preoperatively to two weeks post-operatively could protect and restore the ocular surface in patients undergoing cataract surgery (Fogagnolo et al. 2020).

Keypoints

An important consideration in patients with cataract surgery is to maximally suppress inflammation preoperatively, to avoid enhancement of inflammation after surgery.

Once a patient is diagnosed with poorly controlled or severe DED, surgery should be typically postponed until the surface can be optimized.

(Naderi et al 2020; Mencucci et al 2021)

Intraoperative management

Intra-operative recommendations for preventing and reducing DED (*Mencucci et al 2021*)

- Limit the use of topical anesthetic drops and mydriatic drops
- Avoid persistent surface irrigation
- Prefer small incisions & shorter operative procedures
- Reduce light microscope exposure and intensity
- Caution with premium IOLs in DED patients
- Caution with FLACS in DED patients

Corneal incision

Different types of corneal incisions have an impact on tear film stability and ocular surface function, and a differential incidence on DED after surgery.

Topical anesthetic drops

Use of such agents during surgery should be limited as they can affect tear film and ocular surface condition (*Mencucci et al. 2021*).

Excessive and/or repeated dosing can be toxic to the corneal epithelium and stromal keratocytes (*Mencucci et al. 2021*).

During surgery, frequent irrigation with viscous eye lubricants and ophthalmic viscosurgical device (OVD) is recommended to ensure that the ocular surface is less susceptible to desiccation stress (*Mencucci et al. 2021*).

Corneal incision

Both SICS and FLACS were shown to reduce tear film stability and affect the ocular surface function compared to standard phacoemulsification (*Mencucci et al, 2021*).

Patients with pre-existing dry eye who underwent surgery with FLACS had a higher risk for dry eye symptoms than those of conventional phacoemulsification (*Shao et al, 2018; Yu et al, 2015*).

Phototoxicity

The longer the operative time, the greater the exposure to microscopic light and the greater the inflammatory response and damage that can potentially be caused to the ocular surface and goblet cell density (*Mencucci et al, 2021*).

A prospective clinical study showed that duration of microscopic light exposure during cataract surgery was associated with worse DED symptoms in patients with no prior history of dry eyes (*Cho & Kim, 2009*).

Aspirating Speculum

Negative pressure caused by the suction ring and aspirating speculum can induce or aggravate dry eye parameters and result in conjunctival damage and reduction of goblet cell density, alteration of mucin secretion, and increased inflammation (*Mencucci et al, 2021; Cetinkaya et al, 2015*).

In patients where aspirating speculum was used, it resulted in reduced TBUT and higher OSDI scores at 1 week after surgery compared to a non-aspirating speculum (*Mencucci et al, 2021*).

Topical anesthetic drops

In a randomized study, statistically significantly fewer patients reported dry eye symptoms at 1 week and 1 month postoperatively who were treated with an intracameral injection of a standardized ophthalmic combination of anesthetics compared with the group receiving eye drops (*Mencucci et al 2021*).

In a prospective study, the intra-operative use of 2% HPMC showed that tear film and ocular surface health were better than with the use of balanced salt solution in patients with DED before surgery and patients whose surgical time was prolonged (*Yusufu et al 2018*).

Table 6: Intraoperative factors that can negatively influence development of postoperative DED (*Cetinkaya et al. 2015; Cho and Kim 2009; Mencucci et al. 2021; Shao et al. 2018; Yu et al. 2015; Yusufu et al. 2018*).

Postoperative management

Postoperative recommendations for preventing and reducing DED (*Mencucci et al. 2021*).

Generally, homeostasis indicators such as corneal sensitivity, tear film stability and average density of goblet cells are reduced at 1 day postoperatively, with a peak at 7 days followed by a progressive recovery (*Mencucci et al. 2021*).

Dry eye symptoms have been reported to persist for 1–3 months postoperatively while in severe circumstances, the ocular surface does not recover until 6 months postoperatively (*Mencucci et al. 2021*).

Caution with patients with premium IOLs and visual disturbance (*Mencucci et al. 2021*).

Eyelid Hygiene

For a complete ocular surface treatment, MGD must be considered. MGD represents an important but frequently underestimated and undertreated factor that contributes to the vicious cycle of postoperative DED and it may be aggravated by cataract surgery. There are many clinical treatments for MGD, including eyelid hygiene, warm compresses, meibomian gland expression, omega-3 supplementation and oral antibiotics (*Mencucci et al. 2021*).

Preservative-free Artificial tears

Tear substitutes may play an important role in achieving the control of the inflammatory process in postoperative DED, improving tear fluid clearance and reducing the concentration of pro-inflammatory cytokines (*Mencucci et al. 2021*).

Use of topical artificial tears and lubricants are recommended at least during the first month after phacoemulsification in all patients undergoing cataract surgery (*Sánchez et al. 2010*), improving TBUT, corneal staining and dry eye symptoms postoperatively.

HA/trehalose ophthalmic solution effectively reduced post-cataract surgery DED signs and symptoms in patients with mild/moderate DED, particularly if also administered in the preoperative period (*Mencucci, Favuzza et al. 2021*).

Sodium hyaluronate 0.1% and carboxymethylcellulose 0.5% ophthalmic solution was effective and well tolerated in reducing dry-eye disease symptoms and improving the clinical outcome after cataract surgery (*Mencucci et al. 2015*).

In a prospective study, patients with pre-existing DED who received a fixed combination of carbomer, + HA 0.1% + trehalose (Trehalose Gel, Laboratoires Théa, THEA STUDY) for 1 month after cataract surgery had better outcome in treating ocular irritation and tear film alterations than HA 0.1% (Hydrabak®, Laboratoires Théa, THEA STUDY) alone (*Caretti et al. 2019*).

In patients with postoperative dry eye after cataract surgery, administration of 3% trehalose with 0.15% HA helps reduce inflammation and symptoms of dry eye (THEA study, (*Cagini et al. 2021*)).

Regular post-operative treatments

Post-surgical care implies the use of topical antibiotics, nonsteroidal anti-inflammatory drugs (NSAIDs) and steroids. The use of these eye drops is associated with epithelial toxicity and worsening of goblet cell density. Therefore, in cases of postoperative DED, epitheliotoxic antibiotics should be avoided or used with caution and/or for a short duration (*Mencucci et al. 2021*).

In case of severe inflammation of the ocular surface, more aggressive treatment, including pulse topical steroid therapy or even topical immunomodulatory drugs, can be considered (*Mencucci et al. 2021*).

Keypoints

*Preservative-free topical formulations appear to be more effective in reducing ocular symptoms and improving vision compared to preserved options, especially when eye drops have to be instilled more than 4 times a day over long periods of time, or in patients with pre-existing DED (*Mencucci, Favuzza et al. 2021*).*

Incidence and Prevalence of DED following Cataract Surgery

Dry eye sensation frequently occurs after cataract surgery. The prevalence is variable across studies mainly due to different definition and diagnostic criteria. It is probably higher than generally thought, especially in patients who are asymptomatic before surgery (Starr et al. 2019; Xue et al. 2019).

Dry eye symptoms are generally transient with a peak at 7 days after cataract surgery, but can persist for more than 3 months and usually subside 6 months postoperatively (Starr et al. 2019; Xue et al. 2019).

Below the prevalence of DED following surgery and the impact of pre-existing DED on cataract surgery are described (Cho and Kim 2009; Cochener et al 2018; Iglesias et al. 2018; Jung et al. 2016; Kasetsuwan et al. 2013; Miyake and Yokoi 2017; Naderi et al. 2020; Park, Hwang, and Kim 2016; Sajnani et al. 2018; Stephenson Michelle 2007; Trattler et al. 2017).

Incidence of DED Following Cataract Surgery

Sajnani et al 2018

34 % of patients who experienced dry eye symptoms up to 6 months after cataract surgery reported using frequently artificial tears as well as experiencing neuropathic ocular pain symptoms and light sensitivity.

Stephenson et al 2007

About 50% of patients undergoing cataract surgery reported blurry vision, burning sensation and sticking of the eyelids.

More than 70% of patients reported foreign body sensation. More than 80% of patients experienced dry eyes occasionally using artificial tears.

Kasetsuwan et al 2013

The following table shows the incidence of dry eye at day 7 after phacoemulsification with intraocular lens (IOL) implantation in patients without pre-existing dry eye.

Test	Incidence (95% CI)
OSDI	9.8% (3.6-16.0)
TBUT	68.4% (52.9-83.9)
Oxford scale	58.7% (47.2-70.1)
Schirmer I	11.9% (3.4-20.4)

Miyake & Yokoi, 2017

55.7 % of patients developed dry eye at one month after surgery.

Naderi et al 2020

At 12 weeks post surgery, 100% of patients showed abnormalities in TBUT, Schirmer I tests and DED symptomatology.

Iglesias et al 2018

32% experienced symptoms of DED after cataract surgery.

Keypoint

Postoperative DED is a frequent complication of cataract surgery; its prevalence fluctuates from 9.8 to 34% (Mencucci et al,2021).

Impact of Pre-existing DED & MGD Before Cataract Surgery in Developing OSD

Miyake & Yokoi, 2017

69.7% of patients were diagnosed with DED before cataract surgery.

Cho & Kim, 2009

Patients with preexisting dry eye developed significant exacerbations in dry eye symptoms at 2 months postoperatively.

Cochener et al, 2018, Jung et al, 2016

52% of patients had MGD, and 56% Meibomian gland atrophy before cataract surgery.

Park et al. 2016

Lid margin abnormalities and meibum quality were significantly worsened after surgery in patients with pre-existing mild to moderate DED.

Trattler et al 2017

25% of patients undergoing cataract surgery had been previously diagnosed with DED.

Summary Keypoints

Cataract is characterized by clouding of the lens and blurred vision.

Several precision surgical approaches have been developed in addition to conventional phacoemulsification.

Pathogenic mechanisms that lead to dry eye symptoms following cataract surgery include changes in corneal innervation and sensitivity, increased ocular surface inflammation, meibomian gland dysfunction, and changes in goblet cell density and tear secretion.

Various risk factors have been suggested to be responsible for development of DED before, during or after surgery, and corresponding management approaches.

Preservative-free eye drops are recommended for frequent instillation either before or after surgery along with short-term administration of regular treatments to reduce dry eye symptoms and improve vision.

Prevalence of dry eye symptoms following cataract surgery is relatively high but tends to be significantly reduced after 6 months.

Pre-existing DED is relatively common for patients undergoing cataract surgery and careful consideration on the examination and management should be taken to avoid the development of significant exacerbations of dry eye symptoms after surgery.

(Li et al 2018; Naderi et al 2020; Mencucci et al 2021; Sanchez et al 2010)

Glaucoma Surgery

What is it?

Glaucoma is one of the most common eye conditions where the optic nerve, which connects the eye to the brain, becomes damaged and can potentially result in blindness (Figures 35 & 36).

Glaucoma is one of the leading causes of irreversible blindness in the world and remains a major public health problem (Mélík Parsadaniantz et al. 2020).

Open-angle glaucoma (OAG) is the most common form of glaucoma, characterized by degeneration of the trabecular meshwork, which increases intraocular pressure (IOP) (Mélík Parsadaniantz et al. 2020).

Glaucoma is an insidious disease that remains asymptomatic for a long time, in which visual manifestations occur when there is already permanent damage (Mélík Parsadaniantz et al. 2020).

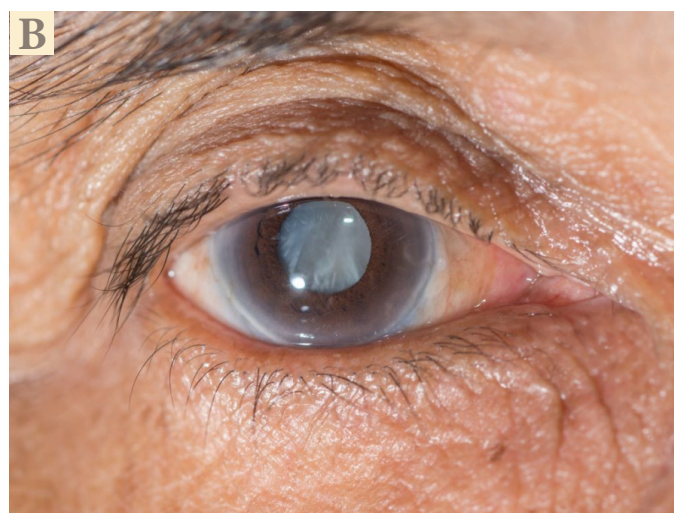
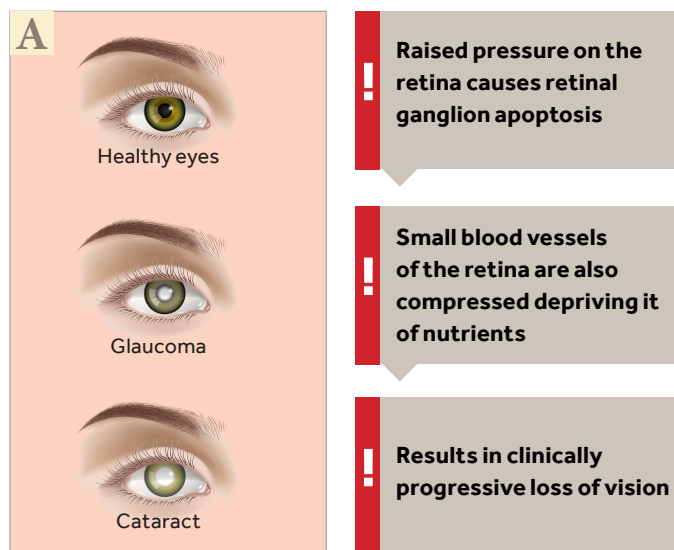


Figure 35: (A) Schematic showing difference in clinical morphological examination among healthy eye and that suffering from glaucoma and cataract. (B) Patient's eye suffering from glaucoma <https://www.eye7.in/glaucoma/>, <https://www.paragoneyes.com/blog/why-you-should-never-ignore-the-symptoms-of-glaucoma>, (Agar et al. 2006; Weinreb et al. 2014).

Recent research suggests that glaucomatous optic neuropathy is a disease that shares common neuroinflammatory mechanisms with “classical” neurodegenerative pathologies. In addition to the death of retinal ganglion cells (RGCs), neuroinflammation appears to be a key element in the progression and spread of this disease. Early reactivity of glial cells has been observed in the retina, but also in the central visual pathways of glaucoma patients and in preclinical models of ocular hypertension (Mélík Parsadaniantz et al. 2020).

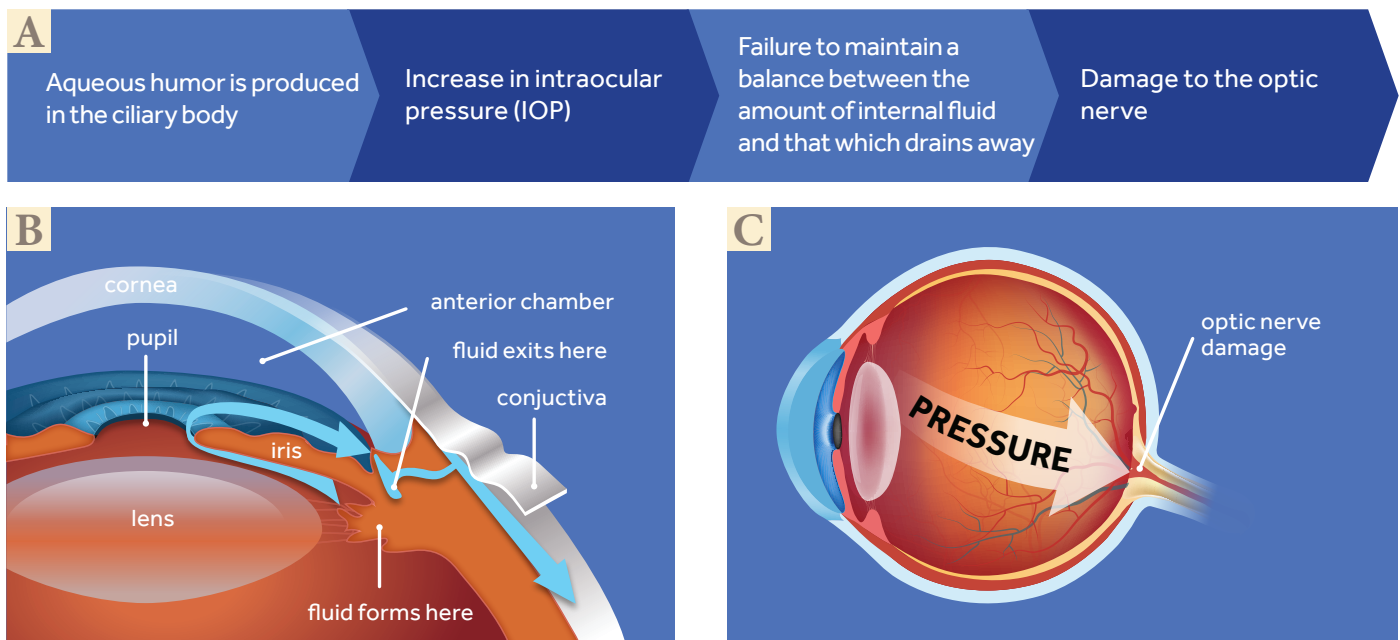


Figure 36: (A) Schematic showing the process flow of glaucoma development leading to damage of the optic nerve (Gupta and Chen 2016). (B) Aqueous humor which plays an important role in nutrient delivery and waste disposal for the cells, is produced in the ciliary body behind the iris and flows into the anterior chamber through the pupil. It drains out through the trabecular meshwork at the anterior chamber angle between the iris and the cornea. (C) Overproduction of the aqueous humor or obstruction of its outflow causes a rise in IOP that can damage the optic nerve in the back of the eye leading to progressive loss of vision. Adapted from <https://www.allaboutvision.com/conditions/glaucoma-2-cause.htm>.

Ocular symptoms

- Pain or discomfort
- Foreign body sensation
- Stinging or burning
- Dry eye sensation
- Tearing
- Eyelid itching
- Eye redness, pruritus
- Photosensitivity, blurred vision

Ocular signs

- Blepharitis
- Eczema
- Conjunctival signs
- Conjunctival Hyperemia
- Follicles
- Corneal signs (superficial punctate keratitis)
- Fluorescein staining
- Tear osmolarity, tear film stability

Modification of patients' primary open angle glaucoma (POAG) or ocular hypertension due to ocular surface intolerance revealed the following symptoms and signs as depicted in the schematic below (adapted from (Baudouin et al. 2013; Jaenen et al. 2007)).

Risk factors for developing Glaucoma (Baudouin et al 2013)

- ! **Age**
- ! **Ethnicity**
(African, Caribbean or Asian origin are at a higher risk)
- ! **Family History**
- ! **Intraocular Pressure (IOP)**
- ! **Past topical treatment**
(instillation frequency)

Trabeculectomy

One of the most common surgical procedures used to treat open-angle and chronic closed-angle glaucoma (Koike & Chang 2018). Trabeculectomy augmented with antifibrotic agents is recommended as an initial surgical treatment for open angle glaucoma (<https://www.eugs.org/eng/guidelines.asp>" Guidelines (eugs.org)).

Surgical intervention is necessary when topical medications are inadequate in achieving the target IOP, or there are significant contraindications for medication use (Koike & Chang 2018).

The main goal of this surgical procedure is the creation of a new pathway for fluid inside the eye to be drained and reduce eye pressure (Figure 37) (Koike & Chang 2018).

Approximately only 40% of patients following trabeculectomy no longer require the use of anti-glaucoma medication (Lee et al 2013).

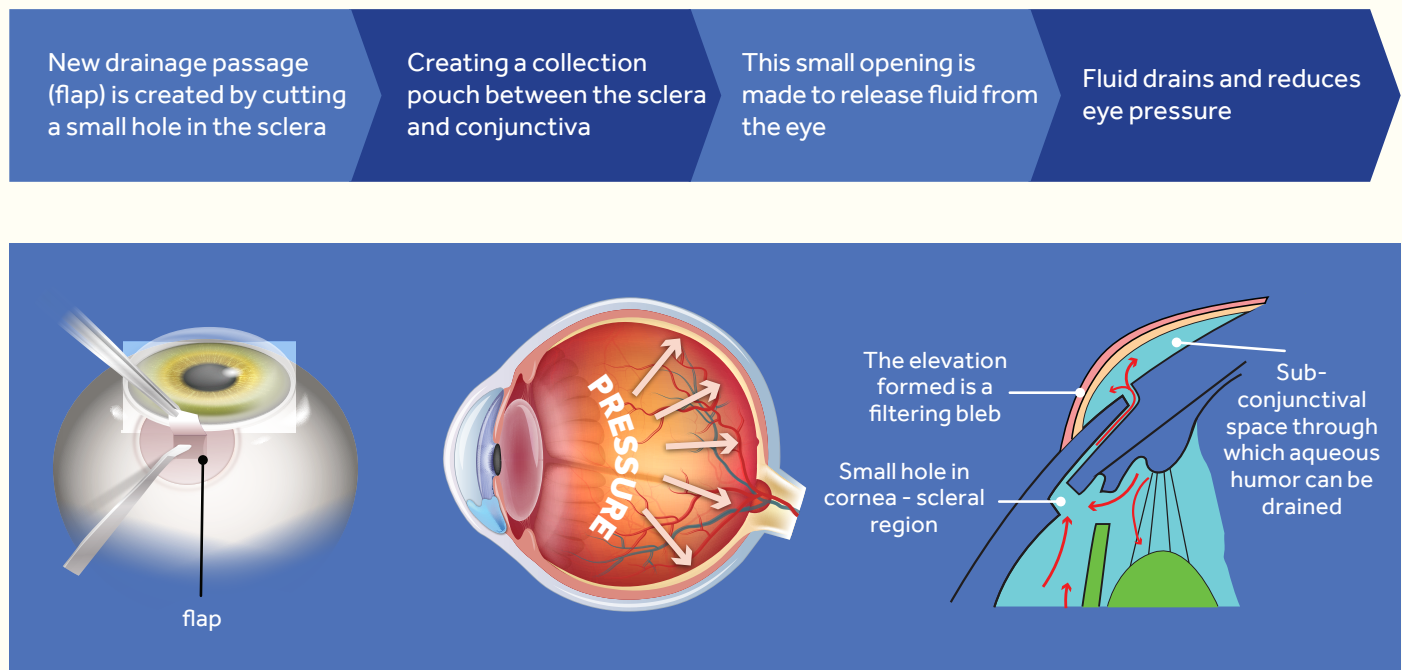


Figure 37: Series of steps and schematics describing the procedure of trabeculectomy (King et al. 2013). <http://www.ngsglaucoma.com/glaucomatrab.html>, <https://cvemg.com/services/glaucoma-treatment/filtration-surgery-trabeculectomy/>, <https://www.osmich.com/glaucoma-dearborn/>.

Pathogenic Mechanisms of DED Associated With Glaucoma Surgery

The mechanisms leading to the disruption and instability of the tear film in the ocular surface, and thus to the development of dry eye symptoms, which also have a negative impact on the outcome of glaucoma surgery, can be summarized into three main categories (Figure 38):

- Morphology of functioning filtering blebs.
- Chronic use of anti-glaucoma medication with preservatives which can stimulate inflammatory responses (increased concentrations of macrophages, lymphocytes, mast cells and fibroblasts).
- Use of antimetabolites (mitomycin C) during glaucoma surgery.

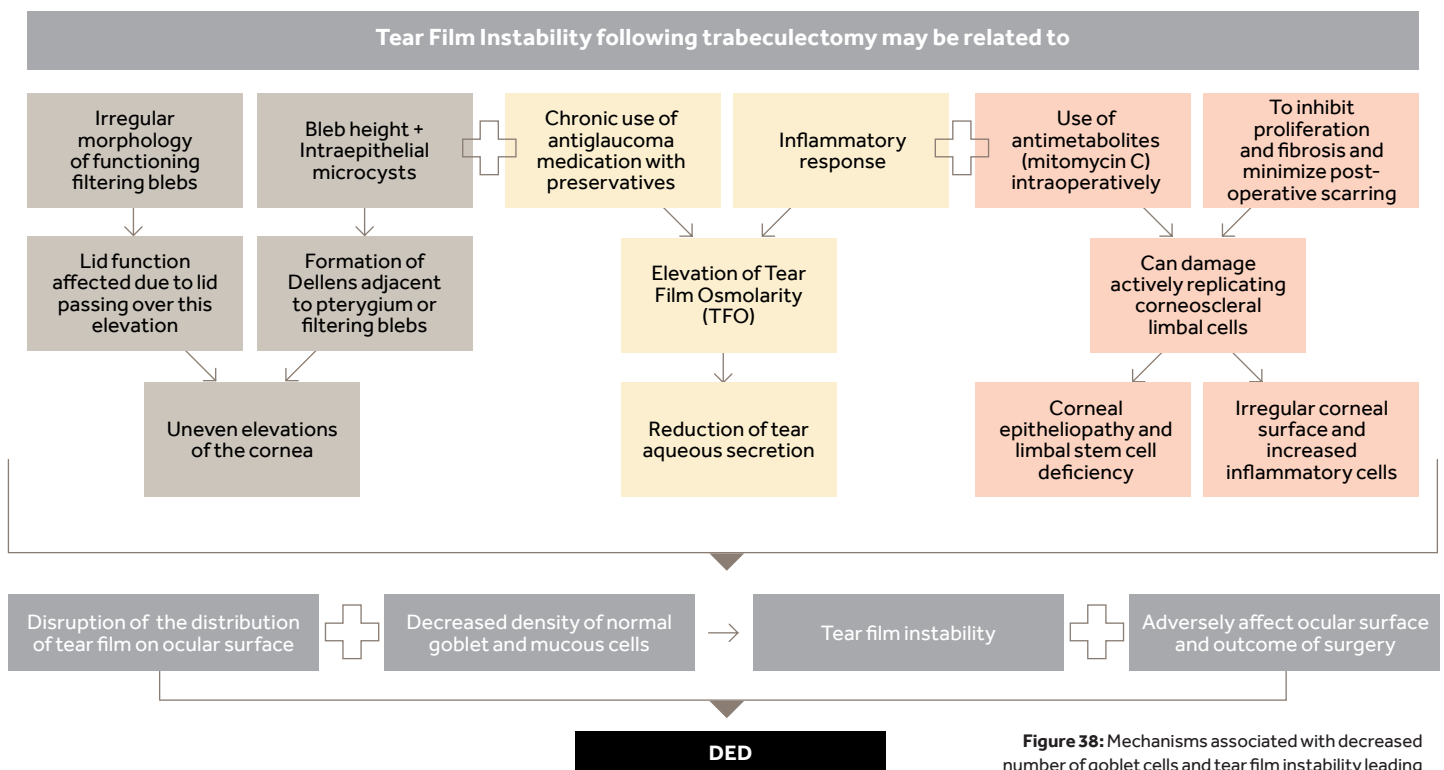


Figure 38: Mechanisms associated with decreased number of goblet cells and tear film instability leading to dry eye disease and adversely affect the outcome of glaucoma surgery. Constructed from (Baudouin et al. 1999, 2002; Ji et al. 2016; Lam et al 2015; Lee et al. 2013).

In a prospective study, patients with glaucoma filtering blebs from trabeculectomy experienced more dysesthesia (ocular pain, discomfort, burning, foreign body sensation, and tearing) compared with eyes without filtering blebs (Figure 39).

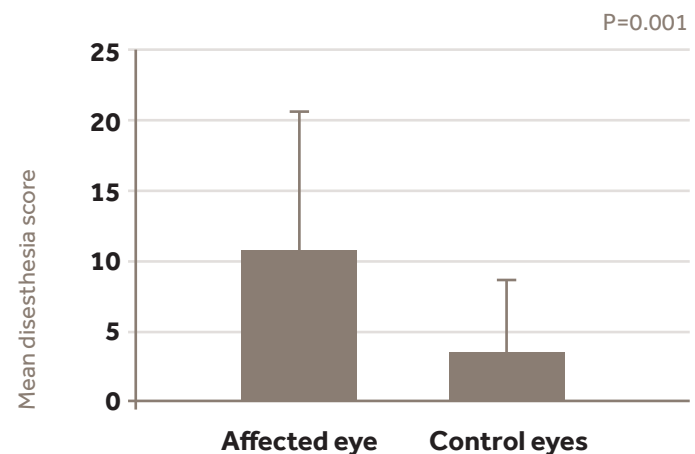


Figure 39: Total dysesthesia scores in post-trabeculectomy patients with glaucoma filtering blebs compared with patients without filtering blebs. Patients were asked to score the frequency (0 to 5) and severity (1 to 5) on dysesthesia symptoms. Adapted from (Budenz et al. 2001).

Below are examples showing slit-lamp examined patient with large glaucoma filtering bleb following trabeculectomy and application of mitomycin C (Figure 40) as well as the morphological and inflammatory changes in immunobiologically examined cornea and conjunctiva samples after use of glaucoma-preserved medication (Figure 41).

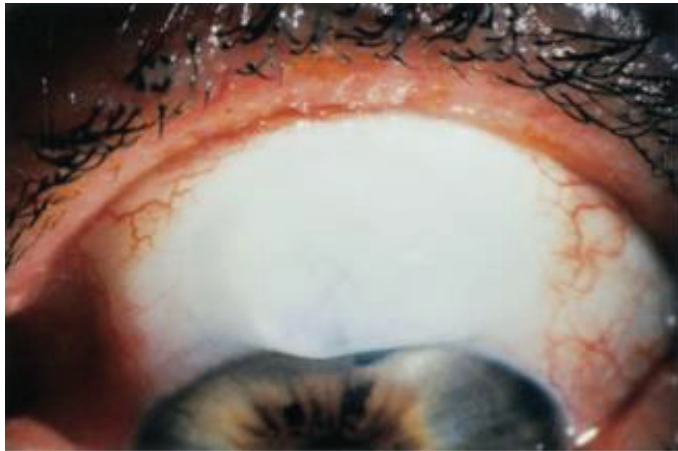


Figure 40: Slit-lamp photograph of the left eye of a patient 2 years after trabeculectomy with mitomycin C. Note large superior filtering bleb. Adapted from (Budenz et al. 2001).

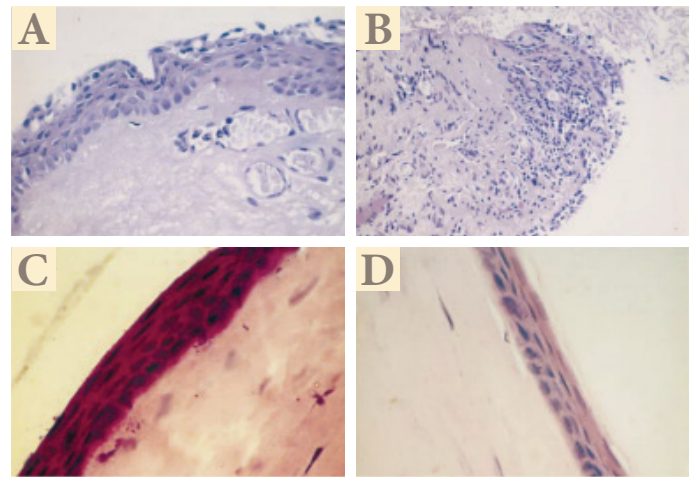


Figure 41: Specimens of conjunctiva and cornea taken at the time of filtering surgery were immunohistologically examined, using a series of inflammatory markers to confirm changes in long-term use of preserved versus preservative-free glaucomatous medication (adapted from Boudouin 1999). **(A)** Normal conjunctival biopsy specimen taken in a nontreated glaucomatous patient (hematoxylin, x500). **(B)** Inflammatory infiltrates in a conjunctival specimen from a multi-treated patient (hematoxylin, x200). **(C)** Normal cornea from a rat treated for 1 month with preservative-free 0.5% timolol (hematoxylin-eosin, x500). **(D)** Cornea treated with 0.01% BKA showing decreased number of epithelial layers (hematoxylin, x500). Adapted from (Baudouin et al. 1999).

High risk of developing DED has been associated with (see schematic below; (Baudouin 2012; Baudouin et al. 2013; Henry JC et al. 2008; Januleviciene 2012; Ji et al. 2016; Lee et al. 2013)):

- long-term use of pressure-lowering anti-glaucomatous medication containing preservatives
- post-trabeculectomy patients

Glaucoma patients with chronic use of preservative-containing pressure-lowering eye drops

51% of patients with glaucoma show significant DED, including mild to moderate in 30% of patients, and severe in 21% [Baudouin et al, 2013].

57% of patients with glaucoma for at least 10 years had ocular surface disease.

The prevalence of DED in patients treated with ocular medications was 71% with 3 or more medications, 54% in those with 2 medications, and 38% in patients treated with monotherapy [Baudouin et al, 2013].

Tear film osmolarity decreased significantly within 2 weeks after the patients switched from preserved to preservative-free topical anti-glaucoma medication [Januleviciene et al, 2012].

In a clinical study, patients treated with latanoprost or bimatoprost switching to BAK-free travoprost demonstrated significant improvement of ocular surface symptoms and hyperemia [Henry et al., 2008].

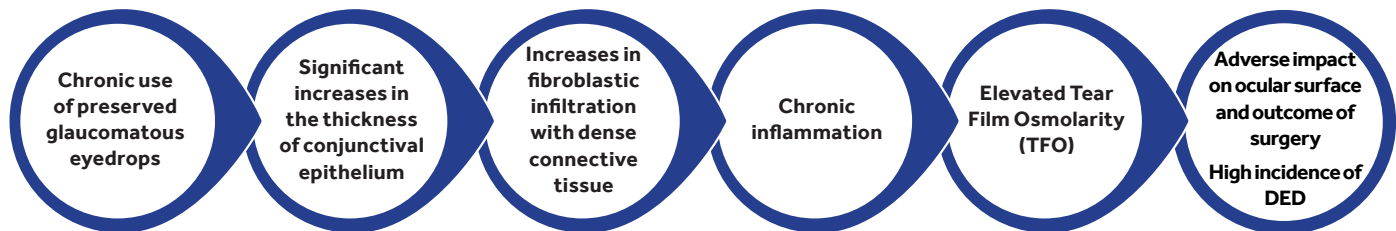
Patients undergone trabeculectomy

Trabeculectomy has been suggested to have deleterious effects on the ocular surface including conjunctival epithelial spongiosis and reduced number of conjunctival goblet cells [Baudouin, 2012; Lee et al, 2013].

In a prospective study, tear film osmolarity was shown to be increased in post-trabeculectomy patients even after 6 months without preserved medications as compared to subjects without glaucoma and DED.

Therefore, DED was relatively common in patients with functioning filtering blebs following trabeculectomy [Ji et al, 2016; Lee et al, 2013].

The effect of long-term use of anti-glaucoma medication containing preservatives, such as BAK, in triggering chronic inflammation and increasing tear film osmolarity, consequently affecting ocular surface, as depicted in the schematics below (Baudouin 2012; Baudouin et al. 1999, 2002; Jaenen et al. 2007).



Effect of Preservatives on the Ocular Surface

— A clinical study in patients who had been treated before surgery with preservative-free indomethacin 0.1% and preserved fluorometholone 0.1% eyedrops for at least 3 years demonstrated significantly decreased subclinical conjunctival inflammation [Baudouin et al, 2002].

— Intensity of DED was significantly less in patients with the use of preservative-free eye drops compared to patients using preserved glaucoma medications [Jaenen et al, 2007].

— Changing treatment from preserved timolol to the unpreserved drug increased breakup time, decreased epithelial permeability, reduced patient complaints, and improved individual tear turnover values in patients with glaucoma [Baudouin et al, 1999].

— The International Dry Eye Workshop has classified the use of anti-glaucoma medication as an extrinsic cause of evaporative dry eye.

Keypoints

Glaucoma therapy with preserved eye drops as well as in patients following trabeculectomy may contribute to DED.

Many studies indicate a direct correlation between the presence of preservatives and the dry eye symptoms experienced during antiglaucoma therapy.

(Jaenen et al 2007; Baudouin 2012; Baudouin et al 1999; 2002; Ji et al 2016; Lee et al 2013)

Multitherapy is likely to increase the incidence of dry eye symptoms in glaucoma patients (Figure 42).

An observational survey confirmed the higher prevalence of dry eye in glaucoma patients receiving more than one drop per day: 39% and 40% developed dry eye with two and three drops, respectively, whereas only 11% of patients who received one eye drop (Rossi et al. 2009).

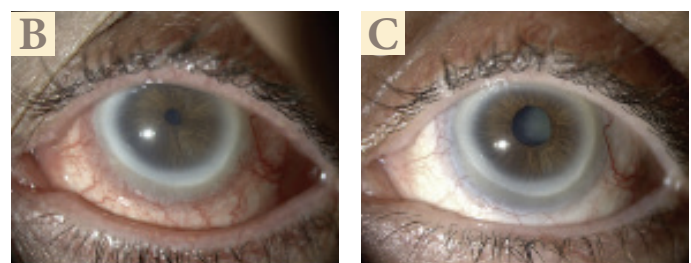
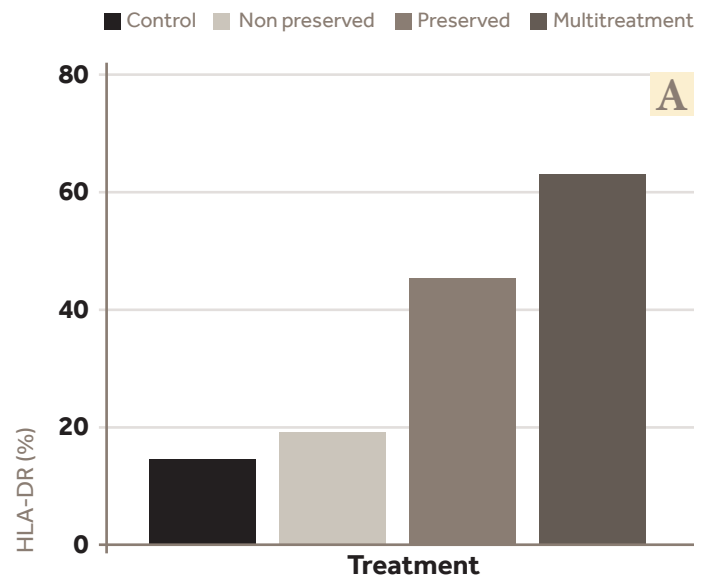


Figure 42: (A) Comparative expression of HLADR class II antigens using flow cytometry in impression cytology specimens in normal subjects and glaucomatous patients treated with unpreserved or preserved beta-blocker, or receiving multiple therapy. (B) Example of toxic reaction resulting from long term use of multiple treatment for glaucoma: note that limbus is distended, hyperemic from inflammatory infiltrates. (C) Few weeks after surgery and treatment, the ocular surface rapidly recovered. Adapted from (Baudouin et al. 2010).

Keypoints

Preservative free eyedrops may improve compliance and adherence in the medical treatment of glaucoma (Jaenen et al 2007).

Numerous studies have confirmed that removal or limited use of BAK substantially improved patient's ocular surface (Baudouin et al, 2010).

Several strategies are in effect of developing alternative approaches to reduce or eliminate the use of preservative-containing (e.g. BAK) anti-glaucoma eye drops (see schematic below; (Bagnis et al. 2011; Baudouin et al. 2010):

Approaches to reduce or eliminate BAK-related adverse effects

Remove BAK from eye drops (this raises industrial and regulatory concerns).

Reducing the number of drops while maintaining at least the same effect on IOP.

Multidose units' preservative-free preparations

Filtration of preservatives through and adsorption on a porous membrane or by a valve system that hinders penetration of bacteria into the bottle (ABAK® (Laboratoires Théa, France) and COMOD (Ursapharm, Germany) systems).

Combine quaternary ammoniums with emulsion of lipids

Emulsion optimizes the ocular surface homeostasis by its oily properties.

Management of DED pre-, intra- and post-Glaucoma Surgery

Several different classes of pressure-lowering medications are available (Table 7).

Class of Medication	Examples (active ingredient)	Preservative-Free (PF)
Prostaglandin analogs	Latanoprost, bimatoprost, travoprost, tafluprost	Latanoprost, travoprost, tafluprost Bimatoprost (as single unit dose)
beta-Adrenergic blockers	Timolol, levobunolol, carteolol, levobetaxolol, betaxolol, metipranolol	<i>Timolol levobunolol (as single unit dose)</i>
alpha-Adrenergic agonists	<i>Brimonidine, apraclonidine</i>	<i>Brimonidine</i>
<i>Carbonic anhydrase inhibitors</i>	<i>Dorzolamide, brinzolamide, Acetazolamide</i>	<i>Dorzolamide</i>
<i>Miotic agents or Cholinergic agonists</i>	<i>Pilocarpine, carbachol</i>	<i>Pilocarpine</i>

Preoperative management

Improvement of the ocular surface and reduction of inflammation prior to surgery should be considered (Broadway et al. 1996).

Use of preservatives should be avoided or reduced as much as possible in patients with severe glaucoma or requiring multiple therapy, most susceptible to undergo surgery, and those with clinically impaired ocular surface, like dry eye, allergic reactions, or blepharitis (Baudouin 2012).

Various studies have demonstrated the clinical advantage of non-preserved eyedrops prior to glaucoma surgery (Baudouin et al. 2002; Breusegem et al. 2010; Broadway et al. 1996).

Treatment before glaucoma surgery

Preoperative 1% fluorometholone eye drops one month before surgery can improve the ocular surface and the success rate of filtration surgery (Broadway et al, 1996).

Indomethacin (unpreserved) and fluorometholone (preserved) eye drops administered one month before filtering surgery in glaucomatous patients also reduced subclinical conjunctival inflammation as measured by ocular surface HLA-DR expression (Baudouin et al, 2002).

Ketorolac eye drops administered for one month in patients with uncontrolled IOP before surgery were shown to be associated with improved trabeculectomy outcome (Breusegem et al, 2010).

Intraoperative management

Use of intraoperative antimetabolites (to reduce bleb scarring and failure) challenges the healing process of the already dry eye-challenged conjunctival epithelium. Chronic dry eye-induced conjunctival inflammation may predispose the patient to bleb failure (*Cvenkel et al. 2013*).

Postoperative management

The ocular surface and the morphology of filtering blebs should be routinely evaluated in postoperative patients (*Waibel et al. 2019*).

In general, as initial management can be considered:

- Use of preservative-free tears.
- Avoidance of repeated exposure to BAK and anti-metabolites.
- Punctal occlusion.
- Topical steroid and antibiotics (preferably preservative-free) for up to 3 months after surgery and cyclosporine A for longer periods, if necessary (see schematic below; (*Fakhraie et al. 2009; Mudhol and Bansal 2021; Sen et al. 2021*).

Preservative-free eye drops

In a retrospective study, following trabeculectomy the group which was administered **trehalose and HA** had improved IOP control, postoperative complications, and bleb morphology compared (THEA STUDY, *Sen et al 2021*).

The absorbable biosynthetic cross-linked **HA** with HealaFlow® (Anteis S. A, Geneva, Switzerland) was equally safe and efficacious to low-dose MMC during trabeculectomy. Similar results on postoperative IOP reduction and bleb morphology over 1 week, 1 month, 3 months, 6 months, and 12 months (*Mudhol & Bansal, 2021*).

Cyclosporine A 0.05%

In an interventional, randomized study, patients receiving **cyclosporine A 0.05%** following trabeculectomy demonstrated after 6 months statistically significant decrease in OSDI with less severity of dry eye symptoms and significant reduction in ocular pain [*Fakhraie 2009*].

Incidence of DED in relation to Glaucoma Surgery

DED is relatively common in patients with functioning filtering blebs following trabeculectomy (Ji et al. 2016). Preoperative-compromised ocular surface and dry eye symptoms may be exacerbated after glaucoma filtration due to surgical disruption of the ocular surface (Lam et al. 2015).

The prevalence of dry eye symptoms in patients undergoing glaucoma is described below (Baudouin et al. 2013; Monjane and Makupa 2020; Mylla Boso et al. 2020).

Incidence of DED in relation to Glaucoma

Baudouin et al 2013

51% of patients with glaucoma show significant dry eye symptoms, including mild to moderate in 30% of patients, and severe in 21%.

57% of patients treated with ocular medications for glaucoma for at least 10 years had dry eye symptoms.

The prevalence of DED was 71% in patients treated with 3 or more medications, 54% in patients treated with 2 medications, and 38% in patients treated with monotherapy.

Monjane & Makupa, 2020

Prevalence of dry eye in patients with glaucoma was 79.7%.

Severity of DED was mild, moderate and severe for 22.1%, 16.0% and 61.9% of the patients, respectively.

Boso et al 2020

73.68% of the patients suffering from glaucoma reported severe symptoms of dry eye.

Summary Keypoints

Glaucoma is a very common eye condition, especially in the elderly, where pressure builds up on the retina which could damage the optic nerve and lead to loss of vision.

Trabeculectomy is the most common surgical procedure.

Pre-existing DED could significantly adversely affect the outcome of glaucoma surgery, therefore cautious preoperative examination and treatment should be considered.

Chronic use of antiglaucoma medication (BAK preservative) and trabeculectomy itself constitute high risk factors for developing DED.

(Jaenen et al 2007; Baudouin et al 2010; Baudouin et al 2013; Lee et al 2013)

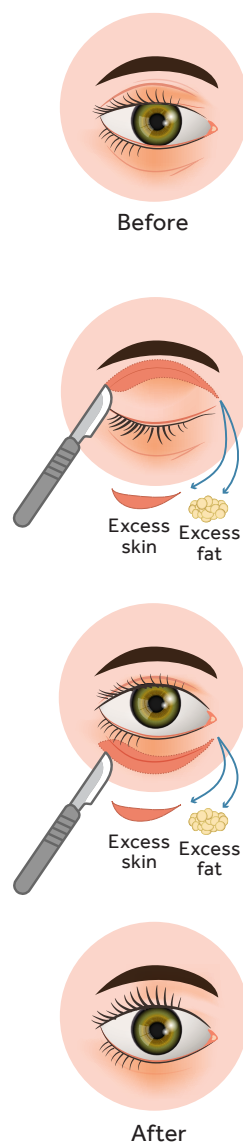
Eyelid Surgery

What is it?

Eyelid blepharoplasty is one of the most common procedures performed worldwide for both functional and cosmetic indications (Yang et al. 2017).

Blepharoplasty is a surgical procedure in which the eyelid skin, orbicularis oculi muscle, and orbital fat are excised, redraped, or sculpted to rejuvenate the esthetic look of the patient along with correction of any functional abnormality (Bhattacharjee et al. 2017).

Among others, some indications of upper eyelid blepharoplasty include dermatochalasis, epiblepharon with lash ptosis, blepharochalasis, inflammation and trauma (Bhattacharjee et al. 2017).



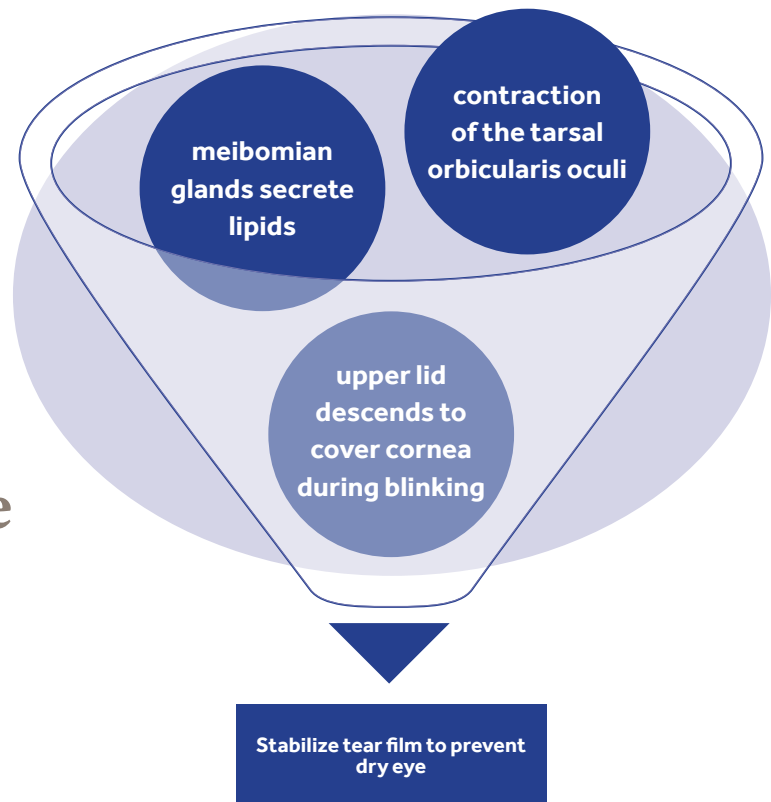
Aging causes eyelids to stretch, and the corresponding supporting muscles weaken and redundant skin folds and wrinkles appear. Loss of adnexal structural support of tarsus, canthal tendons, and orbicularis muscle with thinned skin leads to orbital fat prolapse. As a result, excess skin, muscle and/or fat may gather above and below your eyelids, causing sagging eyebrows, droopy upper lids and bags under your eyes. Age-related descent of the brow (brow ptosis) and attenuation of the levator muscle may cause involutional ptosis (Salvi 2006)

Blepharoplasty can be performed on the upper eyelid, lower eyelid, or both (see schematic opposite, adapted from https://www.123rf.com/photo_95846888_eyelid-surgery-procedure-before-after-illustration-with-main-steps-excess-skin-and-fat-removal-plast.html?vti=nmhrnldqs4i63j-l64u-1-1).

The surgical procedure involves the excision of varying amount of skin and the excision or repositioning of some orbicularis oculi muscle and/or eyelid fat. The aim is to achieve the best aesthetic result without compromising the function of the eyelids and maintaining a healthy and comfortable ocular surface (Leatherbarrow and Saha 2013).

Function of Eyelids and Relationship to Tear Film and Dry Eye

- Cosmetic appearance
- Mechanically protects the cornea
- Tear film stability and DED prevention (see schematic; *(Omari A and Shaheen KW 2021)*).



Below there is a depiction of an example of typical aging changes in the eyelid (Figure 43).

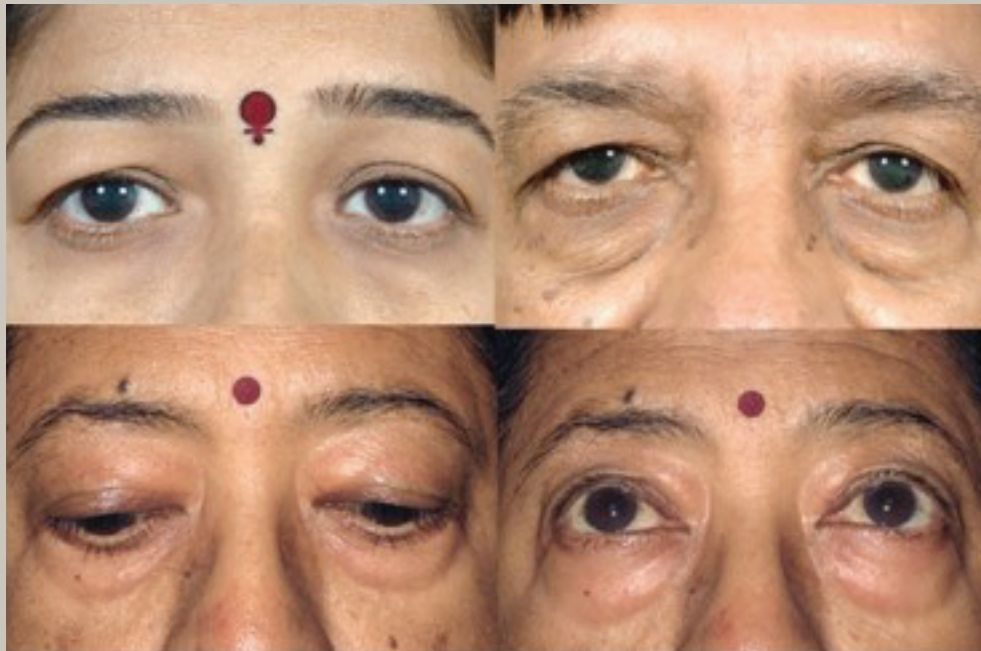

Figure 43: Overhanging upper eyelid skin (top left and right), with prominent orbital rim hollow and lower eyelid fat prolapse (top right). Anatomically, relaxation of the orbital septum, orbicularis muscle, and skin can cause protrusion of intraorbital fat leading to eyelid bags (top right) Lower eyelid fat prolapse becomes less prominent in downgaze (bottom left) and more prominent in upgaze (bottom right). Adapted from *(Naik et al. 2009)*.

Surgical procedure of upper eyelid blepharoplasty

Upper eyelid surgery may be needed due to loss of elasticity and support in the skin, which leads to the creation of folding of excess skin which subsequently impairs vision (Naik *et al.* 2009). The procedure is outlined below (Figure 44).

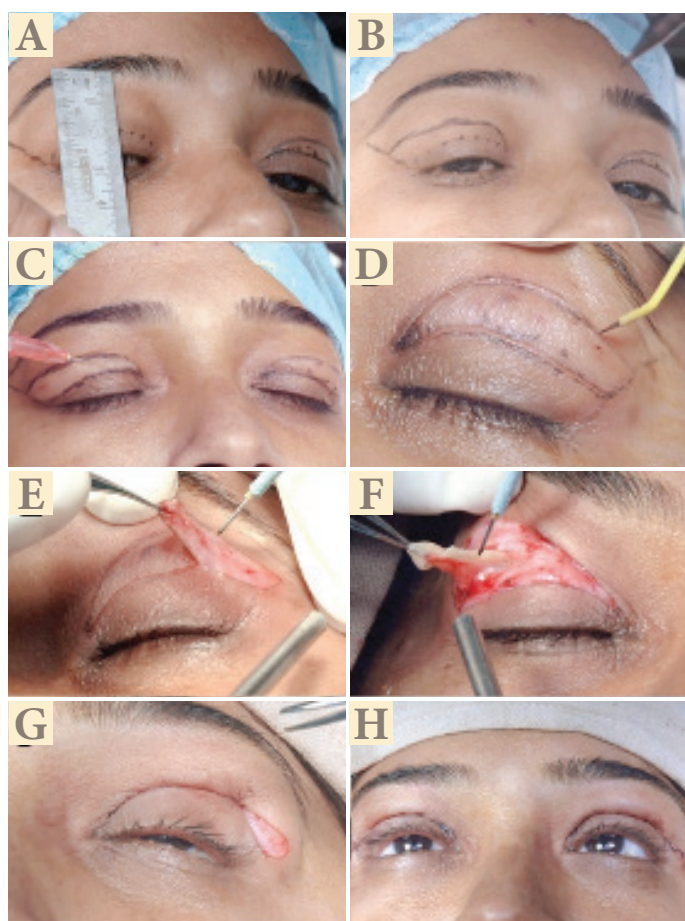

Figure 44: Surgical procedure of upper eyelid blepharoplasty (A) Measurement is performed to leave minimum 20 mm vertical lid height. (B) Skin marking for upper eyelid blepharoplasty. (C) Subcutaneous injection of local anesthetic agent. (D, E) Skin incision with radiofrequency fine monopolar empire tip. (F) Fat pad excision after incising the orbital septum. (G) Periosteal anchoring suture which helps in restoring brow fat pad fullness. (H) Skin closure with 6-0 Prolene™ continuous suture. Adapted from (Naik *et al.* 2009).

Transconjunctival lower lid blepharoplasty and fat repositioning

Some surgeons prefer a transcutaneous approach in patients who have hypertrophy of the orbicularis oculi muscle and therefore require muscle excision. It reduces chances of eyelid retraction, scleral show, and postoperative ectropion (Naik *et al.* 2009).

The surgical procedure and outcome of transcutaneous lower blepharoplasty is depicted below (Figure 45).

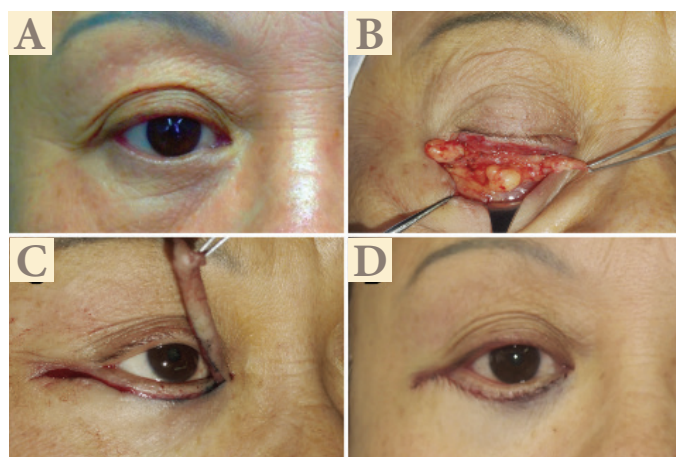


Figure 45: Surgical procedures of transcutaneous lower blepharoplasty. (A) Preoperative view. (B) The incision was made 2 mm below the lid margin in the subciliary crease. At least 3 mm pretarsal orbicularis oculi muscle was preserved, and the lateral, central, and medial fat compartments were exposed. (C) The redundant skin and muscle were excised. The orbicularis suspension suture was placed. (D) Postoperative view. Adapted from (Shao *et al.* 2014).

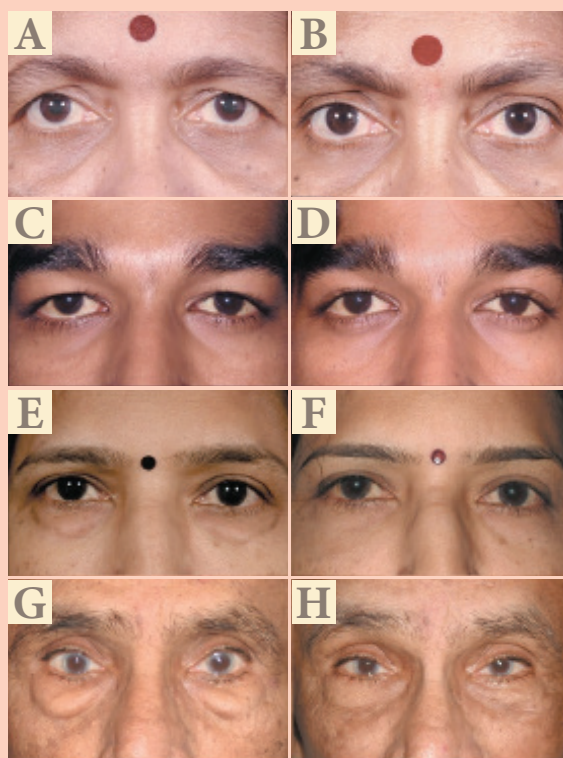


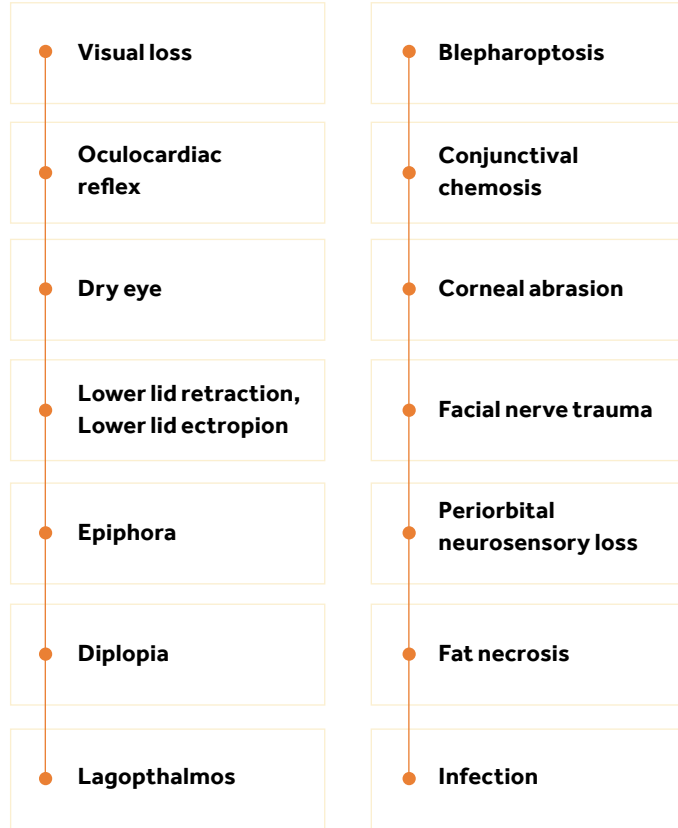
Figure 46: Examples of pre- and postoperative photographs following upper eyelid blepharoplasty (A-D) combined with external brow-lift (A,B) and upper eyelid blepharoplasty combined with retro-orbicularis oculi fat (ROOF) excision (C,D). Pre-and postoperative photographs following transconjunctival lower eyelid blepharoplasty (E-H) involving fat excision only (E,F) and transconjunctival lower eyelid fat repositioning (G,H). Adapted from (Naik et al. 2009).

Keypoints

Cosmetic transcutaneous lower blepharoplasty affects ocular surface and tear fluid, which leads to dryness, tearful eyes, and chemosis. However, this influence is temporary after surgery, and the symptoms resolve within 3 months (Shao et al 2014).

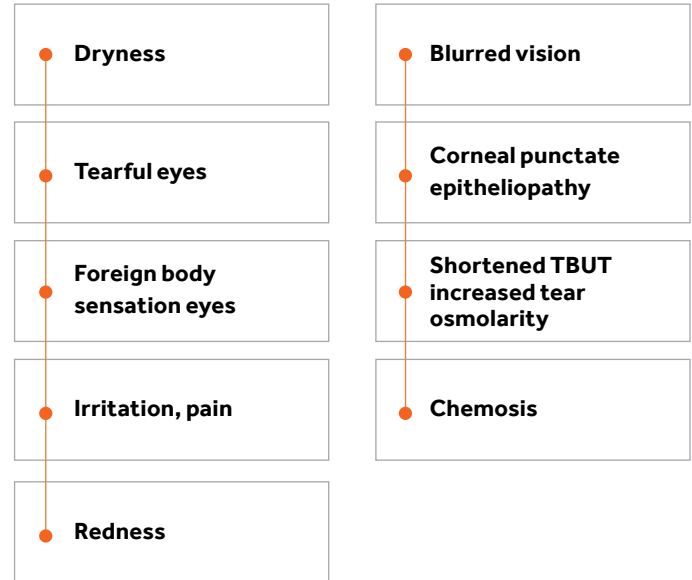
Complications of blepharoplasty surgery

[Leatherbarrow & Saha, 2013]



Signs and Symptoms of DED following Blepharoplasty

[Zhang et al, 2020; Shao et al, 2014]



Keypoint

Signs and symptoms of DED are generally transient and resolved within 3 months (Shao et al. 2014).

Risk Factors for DED Following Blepharoplasty

Numerous risk factors account for dry eye symptoms after blepharoplasty, as outlined below (Table 6; (Zhang et al. 2020)).

- Sexual
- Anatomical
- Environmental
- Systemic
- Pharmacological

Anatomical	Environmental	Systemic	Pharmacological
Negative vector orbit	Reduced humidity	Rheumatoid arthritis	Hormone replacement therapy
Negative lateral canthal tilt	Wind	Sjögren's syndrome	Diuretics
Scleral show	Allergens	Rosacea	Antihistamines
Lid laxity	Air conditioning	Amyloidosis	Anticholinergics
Lagophthalmos	Heating	Hemochromatosis	Antidepressants
Previous ophthalmic surgery (LASIK)	Drafts	Stevens-Johnson syndrome	Systemic retinoids

Careful clinical examination for presence of any of the above risk factors for DED is imperative to evaluate whether to proceed or delay with the surgical operation according to the degree of symptoms and risk. Additionally, the assessment will assist in the appropriate administration of a treatment either pre- or post-operatively (Hamawy et al. 2009).

Opposite, there is an example of a patient who presented multiple risk factors for DED development after surgery, and a description of the procedure of the blepharoplasty performed to avoid the occurrence of dry eye symptoms (Figure 47; (Hamawy et al. 2009)).

Surgical eyelid procedures that can exacerbate DED

Patients must be informed of previous or future surgical procedures that may alter their cornea's interference with the dispersion of tears which in turn may cause dry eye symptoms (see schematic below, (FAGIEN 2004; Fan et al. 2021)).

Previous upper blepharoplasty with lagophthalmos	Extensive skin-muscle flap
Extensive subperiosteal and orbicularis oculi muscle dissection	Canthopexy / canthoplasty
Transpalpebral resection of the corrugator muscles	Combined orbicularis repositioning with high extended superficial musculo aponeurotic plane (SMAS) due to denervation

Table 6: Risk factors for dry eye disease following cosmetic blepharoplasty.

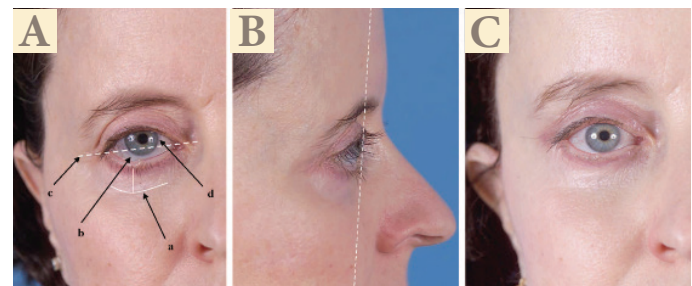


Figure 47: A patient who exhibits multiple risk factors. (A) shortened lower lid (a) with scleral show (b), conjunctival injection, and a negative lateral canthal tilt (c) and is wearing contact lenses (d). (B) lateral view confirms a negative vector orbit. (C) excision of 3 mm of redundant upper eyelid skin; the new supratarsal fold was set at 8mm. A lateral reticular canthopexy was performed to correct the lateral canthal sag and the negative vector aspect of her lower eyelid. Adapted from (Hamawy et al. 2009).

Procedures less likely associated with DED include (Fagien et al, 2007)

- Transconjunctival lower eyelid
- Transconjunctival upper eyelid
- Lower eyelid subciliary incision (especially with skin flap)

Patients prone to DED following blepharoplasty (Pacellae et al, 2010)

- Exophthalmos
- Horizontal lid laxity
- Negative vector orbit
- Ptosis

Pathogenic Mechanisms of DED Following Blepharoplasty

Multiple mechanistic pathways account for the inflammation, the increased tear evaporation, decreased mechanical tear film distribution and reduced tear drainage from the ocular surface leading to the decline of tear film stability, causing postoperative DED and supporting the vicious circles of chemosis and DED (Figure 48; (Bagheri et al. 2015; McCord et al. 2013; Prischmann et al. 2013; Shao et al. 2014; Zhang et al. 2020)).

Development of dry eye symptoms after blepharoplasty could be due to close interaction between the eyelids, tear film and ocular surface, thus affecting lubrication of the tear film (Zhang et al. 2020).

The resection of orbicularis oculi muscle leads to formation of scar affecting the innervation, thus resulting in incomplete reflex blink, decreased blink rate and lagophthalmos, and subsequently reducing lipid secretion from meibomian glands (Zhang et al. 2020).

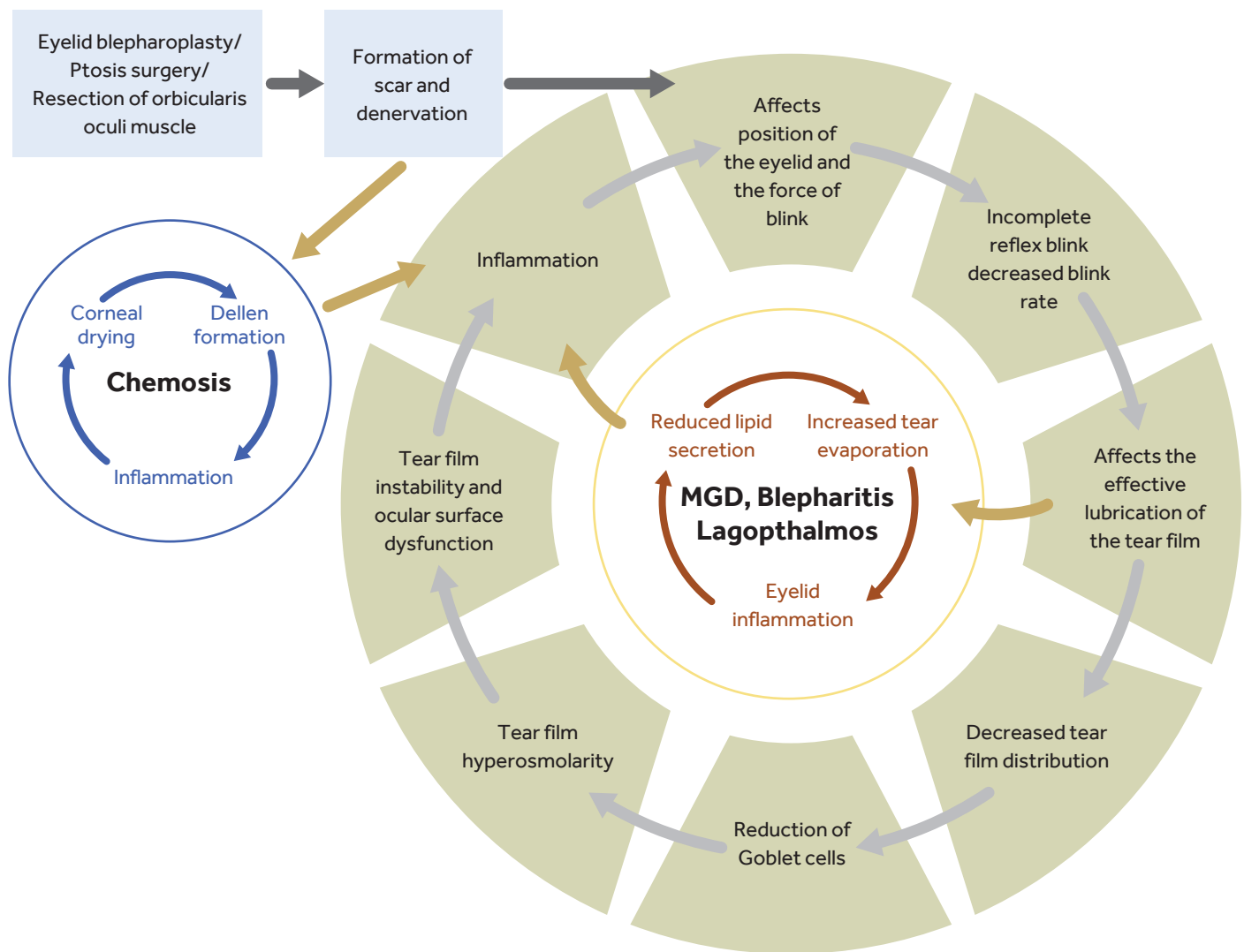


Figure 48: Blepharoplasty can result in anatomic distortion of the lid-corneal interface leading to a vicious cycle of chemosis which can enter the vicious cycle of DED. Surgery can also trigger inflammation leading to reduced quantity and quality of tears in operated eyes, and the associated changes in the lubrication of the tear film can enhance meibomian gland dysfunction (MGD), blepharitis or lagophthalmos which can positively feedback and exacerbate the postoperative dryness (constructed from (Bagheri et al. 2015; McCord et al. 2013; Prischmann et al. 2013; Shao et al. 2014; Zhang et al. 2020)).

Below is an example showing that the risk of developing dry eye symptoms (DES) and chemosis is enhanced after blepharoplasty with a depiction of the three different stages of chemosis (mild, moderate and severe) from a patient's eye (Figure 49).

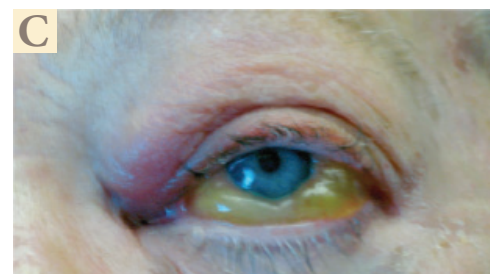
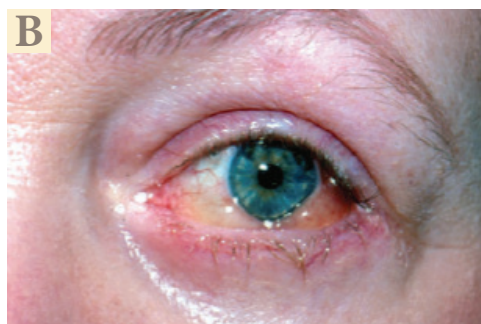
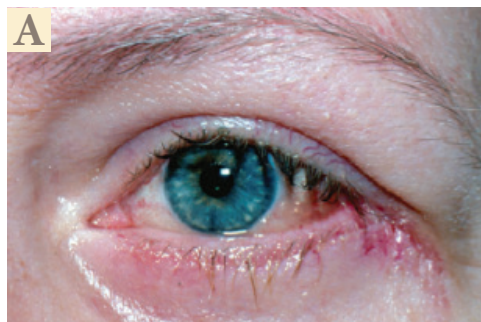
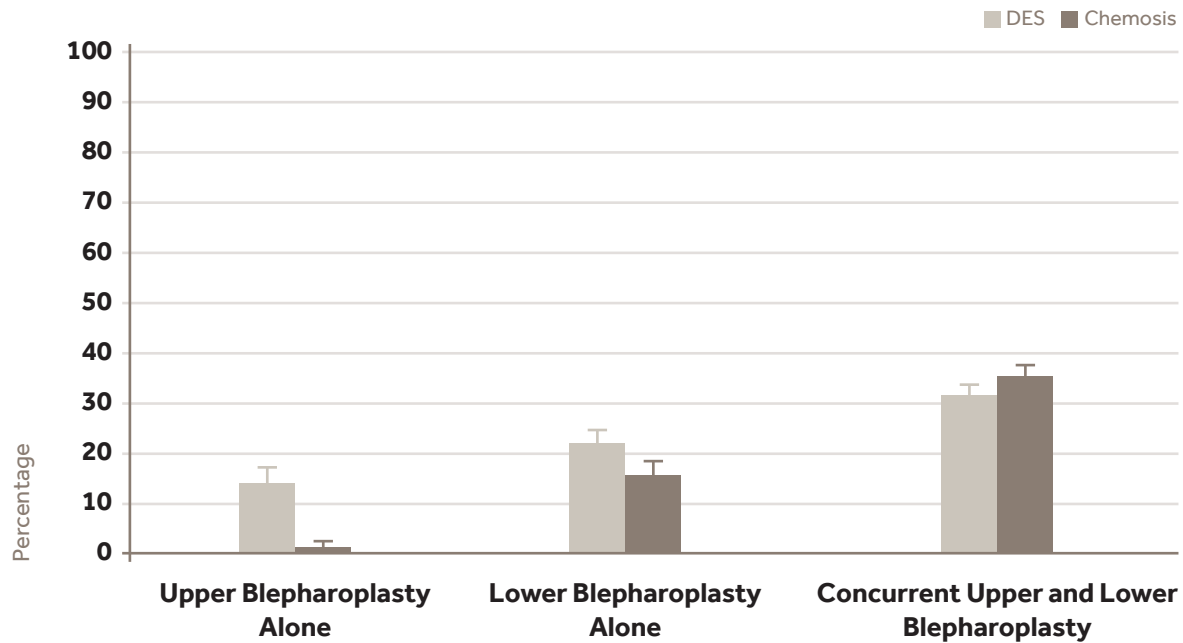
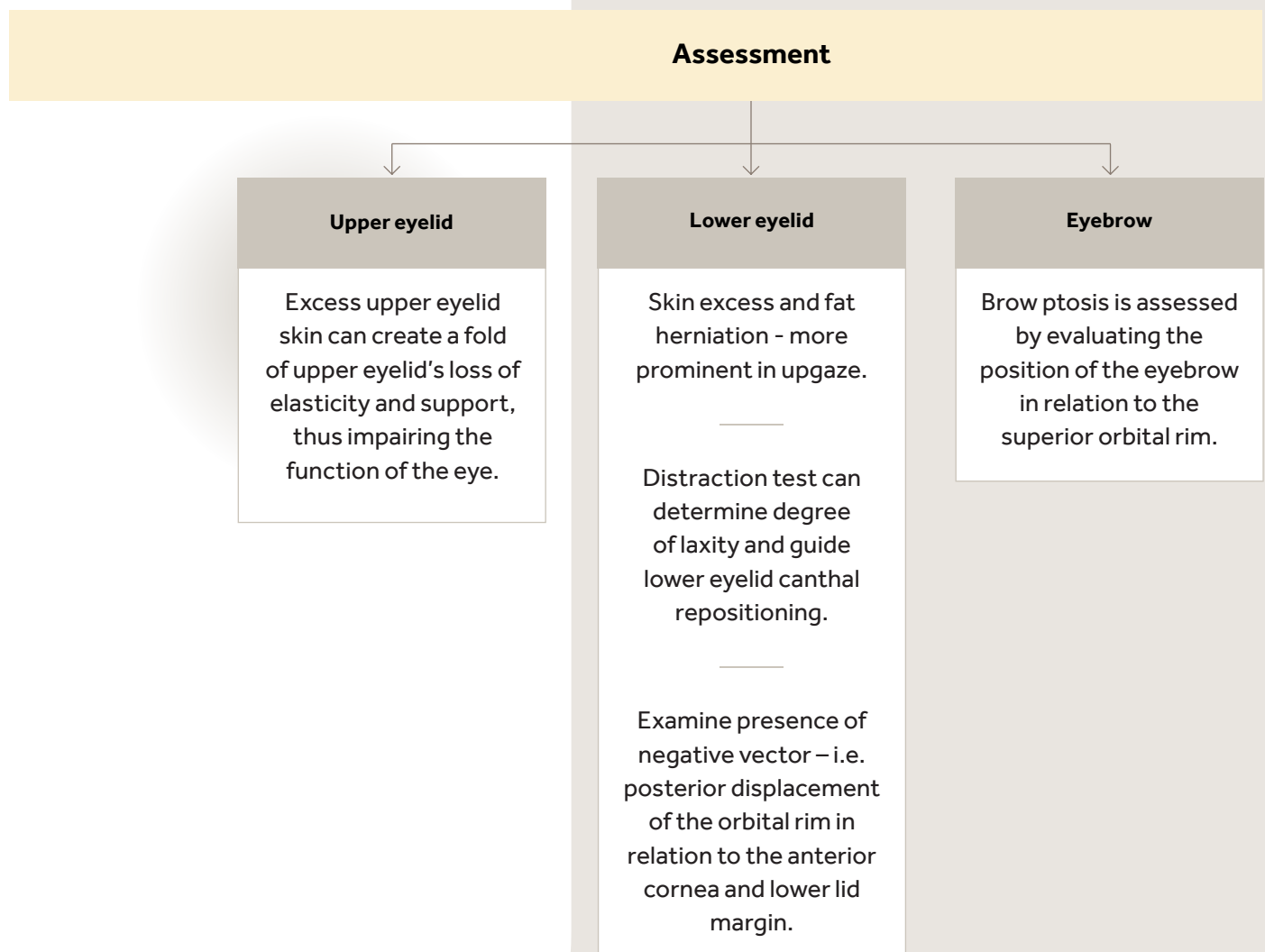


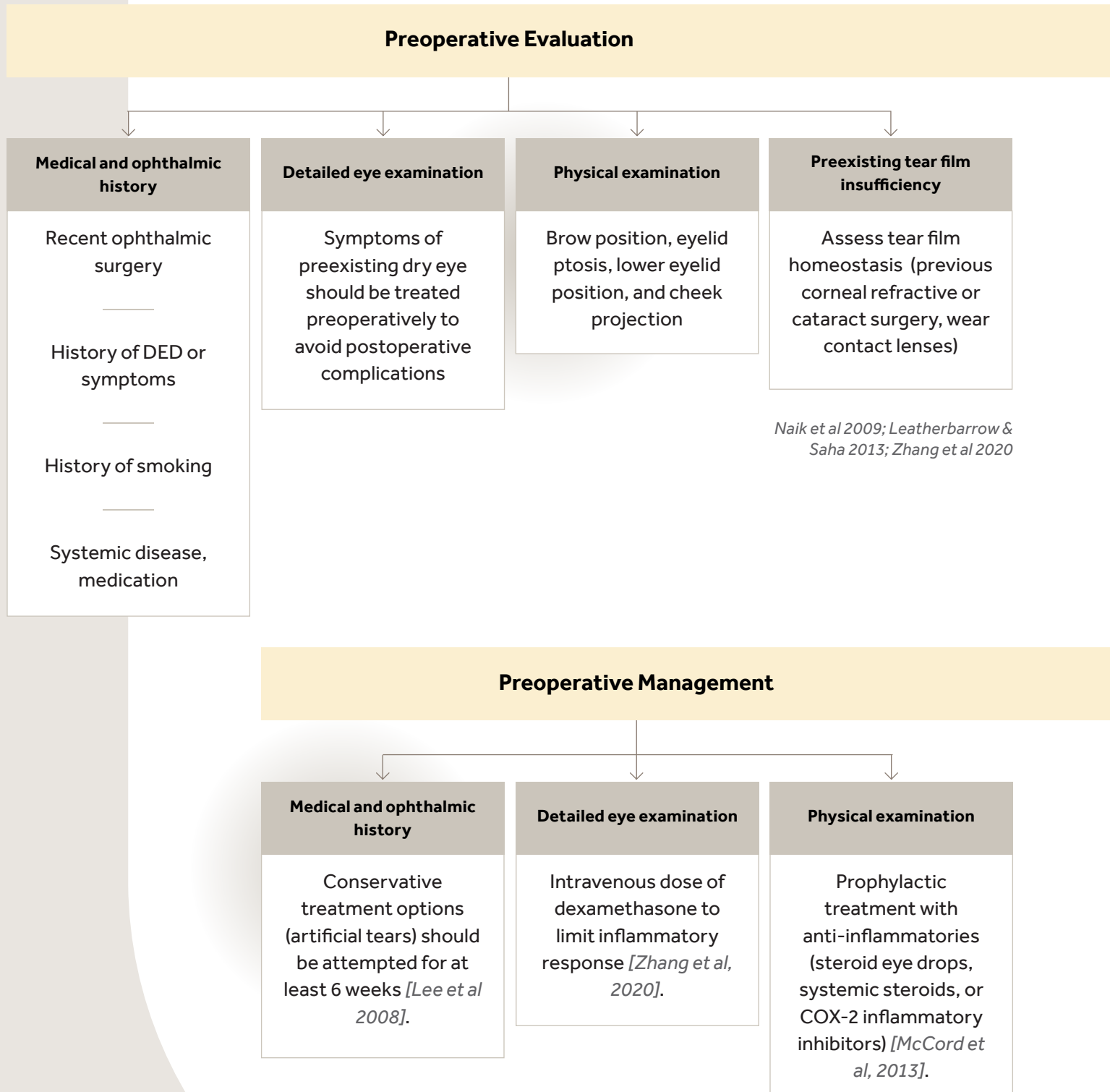
Figure 49: On the top panel, dry eye symptoms and chemosis follow eyelid blepharoplasty (adapted from Prischman et al 2013). On the bottom panel, an example of a woman demonstrating (A) mild, acute chemosis 1 week after lower blepharoplasty. (B) Moderate, acute chemosis 1 week after lower blepharoplasty. Conjunctival swelling obscures the meibomian gland orifices of the lower lid. Eyelid closure is not impaired. (C) Moderate to severe, acute chemosis 1 week after lower blepharoplasty. The eyelids cannot close completely due to prominent conjunctival edema. Adapted from (McCord et al. 2013).

Management of DED pre-, intra- and post- Blepharoplasty

The typical assessment of a candidate patient for blepharoplasty is comprised of three areas; the upper eyelid, lower eyelid and eyebrow (see schematic below, (Naik et al. 2009)).



Before surgery, there are certain factors that should be evaluated (Leatherbarrow and Saha 2013; Naik et al. 2009; Zhang et al. 2020) and if the patient reveals symptoms of preoperative DED, then alternative prophylactic treatments can be administered for managing DED (see schematics below; (Lee et al. 2008; McCord et al. 2013; Zhang et al. 2020)).



An algorithm for evaluating preoperative dry eye symptoms and whether surgery will be performed, is illustrated below (Figure 50).

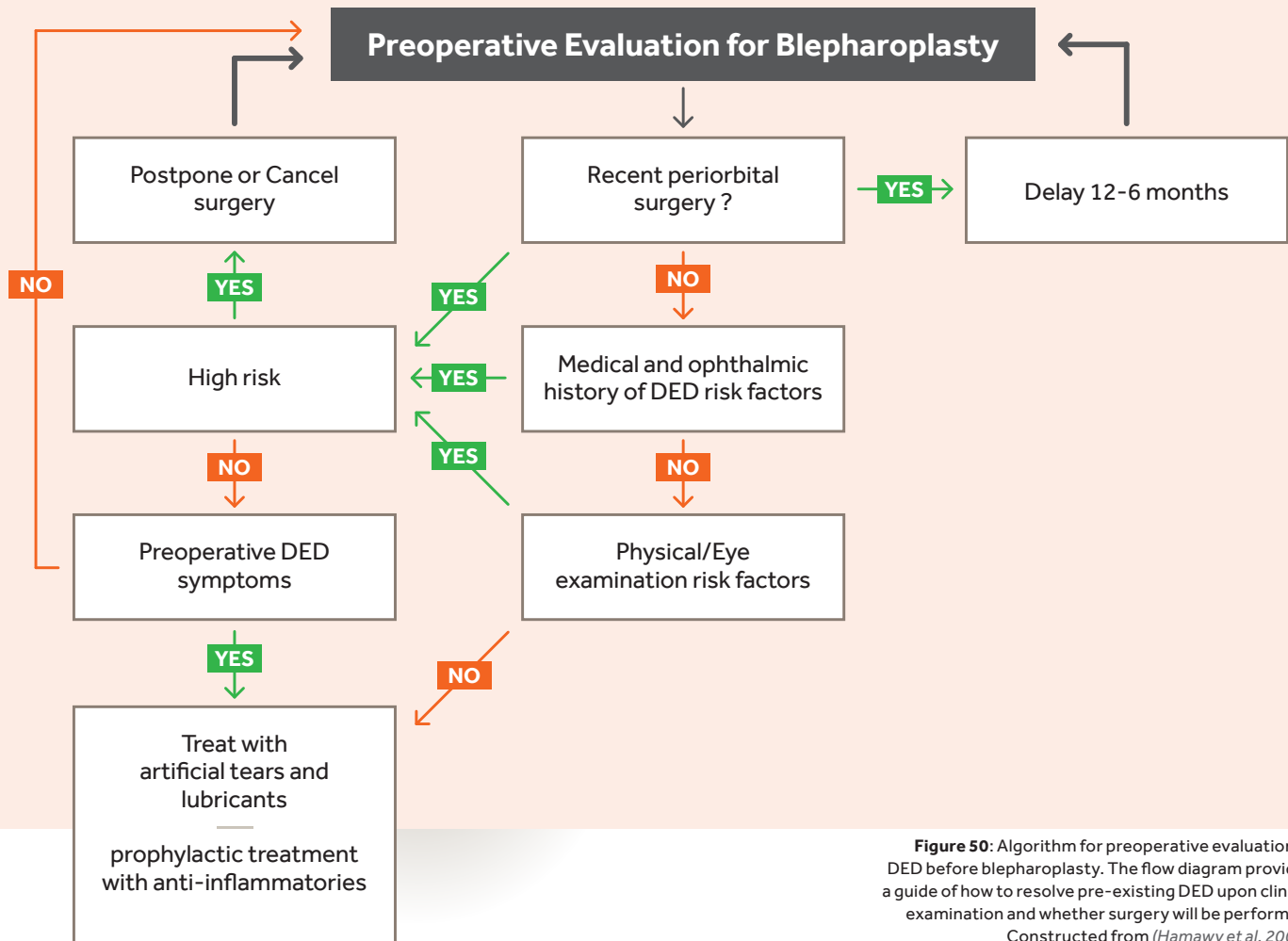


Figure 50: Algorithm for preoperative evaluation of DED before blepharoplasty. The flow diagram provides a guide of how to resolve pre-existing DED upon clinical examination and whether surgery will be performed. Constructed from (Hamawy et al. 2009).

The schematic below highlights the five factors that are taken under consideration during surgery.

Intraoperative management

<p>Corneal protection Trauma or prolonged exposure can lead to corneal abrasion or ulceration. Lubrication or corneal shields should be used during the operation.</p>	<p>Orbicularis oculi muscle and its innervation protected to avoid damage and decrease of blink rate and cause evaporative tear loss.</p>
<p>Conservative excision Upper blepharoplasty: Accurate measurement with a caliper [8-9 mm in pretarsal fold]. Lower blepharoplasty: conservative skin resection [to avoid lower lid retraction and ectropion].</p>	<p>Inflammation should be controlled by minimizing the trauma.</p> <p>Lacrimal gland Care should be taken to protect it.</p>

Zhang et al 2020; Hamawy et al 2009

An algorithm for evaluating and managing post-operative dry eye symptoms is illustrated below (Figure 51).

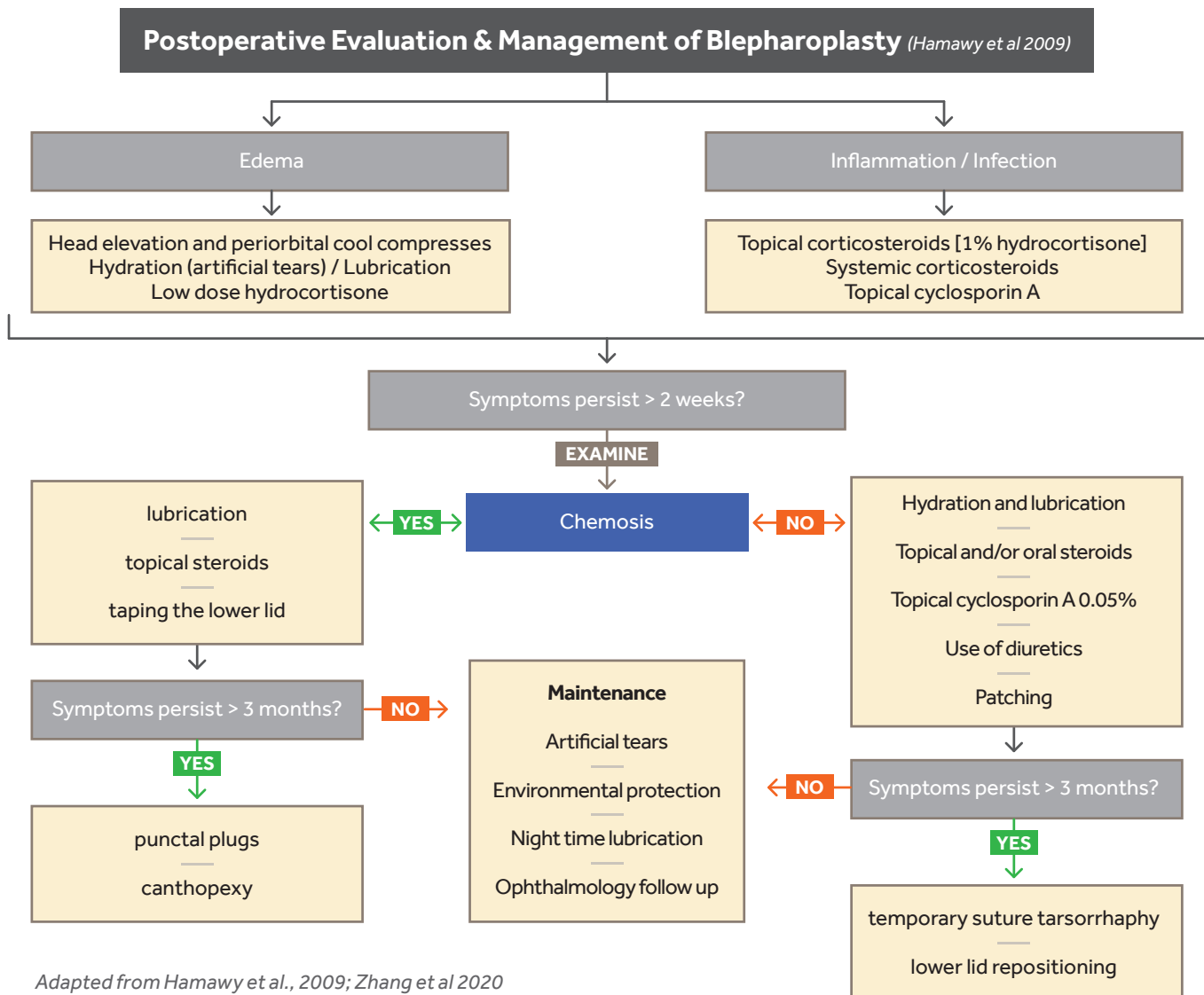


Figure 51: The flow diagram provides a guide on certain therapeutic approaches for post-operative management of DED depending on the time interval of persistence of symptoms. Constructed from (Hamawy et al. 2009).

Keypoints

Dry eye symptoms and chemosis are common following blepharoplasty (Thakker et al 2005).

In most patients, postoperative chemosis following cosmetic blepharoplasty typically resolves spontaneously.

Incidence of DED Pre-, Intra- and Post Blepharoplasty

The prevalence of developing dry eye symptoms and chemosis in relation to eyelid surgery is described below (*Hamawy et al. 2009; Prischmann et al. 2013; Shao et al. 2014; Yan et al. 2020*).

Incidence of DED (and Chemosis) Following Blepharoplasty

Prischmann et al 2013

DED occurred in 26.5% of patients following blepharoplasty in a retrospective study.

Simultaneous upper and lower blepharoplasty (31.3%) were more likely to cause DED compared to simple upper blepharoplasty (12.9%) and simple lower blepharoplasty (21.4%).

26.3% of patients developed chemosis following blepharoplasty.

Hamawy et al 2009

Persistent chemosis occurred in 68.2% who had symptomatic dry eyes.

In a retrospective review patients who underwent upper and/or lower blepharoplasty showed dry eyes persisting longer than 2 weeks after surgery in 10.9% and longer than 2 months in 2 % of them.

Yan et al, 2020

Double-eyelid blepharoplasty affects tear film dynamics and aggravates dry eye symptoms in young Asian females.

The incident rate of dry eyes at 1 week, 1 month and 3 months were 12.5%, 32.5%, and 16.7%.

Shao et al, 2014

A prospective observational study showed that incidence of dry eye and chemosis at 1 week following transcutaneous lower blepharoplasty was 16.7% and 15.0%, respectively.

Summary Keypoints

Blepharoplasty may affect tear film stability and trigger ocular surface inflammation leading to the development of dry eye symptoms.

Clinical examination before surgery is critical to determine whether to proceed with the surgery and administer the appropriate treatment both before and after surgery.

Eyelid surgery may distort the lid-corneal interface leading to chemosis and entering the vicious cycle of DED, and thus affecting tear quality.

Most patients develop dry eye symptoms and/or chemosis after surgery which tends to resolve after 2-3 months.

(Hamawy et al 2009; McCord et al 2013; Zhang et al 2020)

Conclusion/ Summary

In summary, as depicted in Figure 52, this handbook presents:

— **the impact/incidence between dry eye and different surgeries (refractive, cataract, glaucoma and blepharoplasty). Specifically:**

- the incidence of dry eye development following surgery.
- the risk factors and pathogenic mechanisms of different surgeries on the development of dry eye (pre-, intra-, or postoperatively).
- the impact of pre-existing dry eye on the outcome and efficacy of surgery and on the development of post-operative dry eye.

— **the different management approaches in treating dry eye (pre-, intra-, or postoperatively) with emphasis on:**

- the superiority of using preservative-free over preservative-containing eye drops in reducing dry eye symptoms both before and after surgery.
- the importance of avoiding chronic use of preservative-containing eye drops, such as BAK, especially in medication treating glaucoma, to minimize the possibility of developing glaucoma itself and/or DED.
- the use of trehalose, hyaluronic acid and hydrocortisone as soft corticosteroid either alone or in combination with standard medication (e.g. anti-inflammatory) in improving the ocular surface.

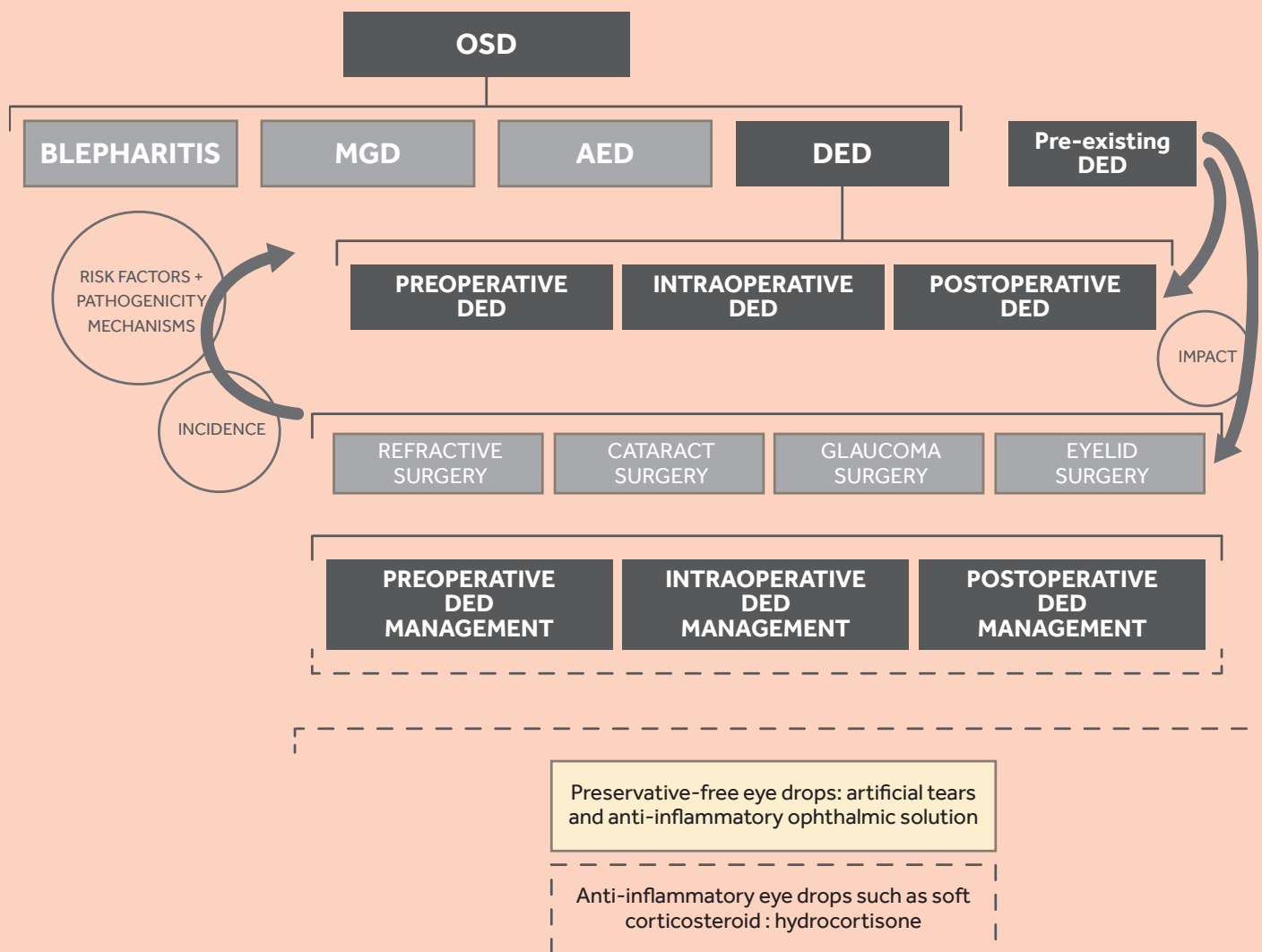


Figure 52: Summarized schematic of this handbook. Abbreviations used: OSD (Ocular Surface Disorder), MGD (Meibomian Gland Dysfunction), AED (Allergic Eye Disease), DED (Dry Eye Disease).

Acknowledgements

We greatly appreciate the expertise and assistance of Creative Pharma & HR Services S.M.S.A. in conceptualizing, editing and revising the content.

Supplementary table incorporating THEA STUDIES with information on author, number of patients that participated, as well as on treatment, posology and duration, and the corresponding conclusion.

Study	Number of patients	Treatment, posology & duration	Conclusion
Schmidl D et al 2015. Tear film thickness after treatment with artificial tears in patients with moderate dry eye disease. <i>Cornea</i> . 2015 Apr;34(4):421-6.	60	<p>Patients received a single dose of either unpreserved trehalose 30 mg/mL and sodium hyaluronate 1.5 mg/mL (TH-SH, Thealoz® Duo, Laboratoires Thea, Clermont Ferrand, France), unpreserved sodium hyaluronate, 0.15% (HA, Hyabak®, Laboratoires Thea, Clermont Ferrand, France) or sodium chloride, 0.9% (NaCl, Hydrabak®, (Laboratoires Thea, Clermont Ferrand, France) eye drops.</p> <p>On the study day, after baseline measurement of tear film thickness (TFT) with OCT, 1 of the 3 agents was administered. Three minutes after administration, patient's feeling on instillation was assessed. Measurements of TFT were repeated 10, 20, 40, 60, 120, and 240 minutes after instillation.</p>	The findings of this study indicate that single instillation of TH-SH and HA eye drops increases TFT in patients with dry eye disease. The data also indicate longer corneal residence of the TH-containing eye drops. The effect of multiple instillation and long-term use of artificial tears on TFT warrants further investigation.
Fondi K et al 2018. Effect of Hyaluronic Acid/Trehalose in Two Different Formulations on Signs and Symptoms in Patients with Moderate to Severe Dry Eye Disease. <i>J Ophthalmol</i> . 2018 Aug 1;2018:4691417.	40	In one group, patients received a mixture of sodium hyaluronate and trehalose (HT, Thealoz® Duo, Laboratoires Thea, Clermont Ferrand, France) for use during the day. In the other group, patients received a more viscous formulation consisting of hyaluronic acid, trehalose, and carbomer (HTC-gel, Thealoz® Duo Gel, Laboratoires Thea, Clermont Ferrand, France) to use pro re nata. The following treatments were compared: one group received HT instilled pro re nata during the day for one week. The second treatment group received a HTC-gel again instilled pro re nata for one week. Both treatment groups were asked to instill the HTC-gel at night time before going to sleep. After the first treatment period, the patients crossed over to the alternative treatment. During HT treatment, the frequency of instillation was 3.2 ± 2.6 times per day. When treated with HTC-gel, the frequency of instillation was significantly lower 1.9 ± 2.2 times per day compared to the HT treatment.	The results show improvement in signs and symptoms of DED in both groups. While instillation of HTC-gel resulted in a lower instillation frequency, both formulations of trehalose showed good clinical efficacy.
Chiambaretta F et al 2017. A randomized, controlled study of the efficacy and safety of a new eye drop formulation for moderate to severe dry eye syndrome. <i>Eur J Ophthalmol</i> . 2017 Jan 19;27(1):1-9.	105	Moderate to severe dry eye disease patients received either trehalose (3%) solution (HA-trehalose; Thealoz Duo®, Laboratoires Théa, Clermont-Ferrand, France (n = 52)) or sodium hyaluronate solution (HA; Visméd®, Horus Pharma, Saint-Laurent-du-Var, France) (n = 53) 3-6 times per day for 84 days.	Hyaluronic acid-trehalose is effective and safe, with better patient satisfaction, than existing HA only eye drops particularly from the first month of treatment, and offers a therapeutic advancement in the treatment of moderate to severe DED

Study	Number of patients	Treatment, posology & duration	Conclusion
Kallab M et al 2019. Topical Low Dose Preservative-Free Hydrocortisone Reduces Signs and Symptoms in Patients with Chronic Dry Eye: A Randomized Clinical Trial. <i>Adv Ther.</i> 2020 Jan;37(1):329-341.	60	Patients were randomized to receive either preservative-free hydrocortisone 0.335% (Softacort, Laboratoires Thea, Clermont Ferrand, France) for 12 days four times daily followed by 2 days twice daily instillation (intense treatment group) or 8 days three times daily followed by 3 days twice daily treatment (standard treatment group). Study duration was 28 days.	Treatment with low dose hydrocortisone 0.335% reduced ocular inflammation and decreased OSDI score. No change in IOP was observed in either of the two treatment schedules. Because of its good safety profile, low dose Treatment with low dose hydrocortisone 0.335% reduced ocular inflammation and decreased OSDI score. No change in IOP was observed in either of the two treatment schedules. Because of its good safety profile, low dose hydrocortisone may be an interesting alternative to standard corticosteroid treatment in DED.
Kuzmanović Elabjer B et al 2020. A Retrospective Data Review Confirms That Topical Preservative-Free Hydrocortisone Improves Inflammation in Dry Eye Disease. <i>Clin Ophthalmol.</i> 2020 Oct 30;14:3691-3697.	15	This retrospective data review included 15 patients with mild to moderate Dry Eye Disease (DED, 13-32 points), treated twice a day with preservative-free hydrocortisone 0.335% (PFH, Softacort®, Laboratoires Théa, France).	Topical PFH twice daily for 2 weeks significantly improves clinical signs and symptoms in patients with mild to moderate DED with no safety issues.
Caretti L et al 2019. Efficacy of carbomer sodium hyaluronate trehalose vs hyaluronic acid to improve tear film instability and ocular surface discomfort after cataract surgery. <i>Clin Ophthalmol.</i> 2019 Jul 9;13:1157-1163.	60	The study was a single center prospective randomized case-control study from August 2017 to May 2018. After surgery, 30 eyes received carbomer sodium hyaluronate trehalose eye drops (Thealoz® Gel, Thea Laboratoires, Clermont-Ferrand, France) (trehalose group), while the other 30 eyes were treated with sodium hyaluronate (Hydrabak®, Thea Laboratoires, Clermont-Ferrand, France) (Hyaluronate group, HG). Patients in both groups administered the treatment 2 times a day for one month after the surgery in association with topical steroid-antibiotic combination and topical nonsteroidal anti-inflammatory drugs (NSAIDs).	Carbomer sodium hyaluronate trehalose (CHT) was effective and well tolerated in reducing dry eye disease symptoms and improving the clinical outcome after cataract surgery. On some parameters (BUT, OSDI), this new formulation was more effective than commonly used sodium hyaluronate in treating ocular irritation and tear film alterations
Cagini C et al 2021. Trehalose/sodium hyaluronate eye drops in post-cataract ocular surface disorders. <i>Int Ophthalmol.</i> 2021 Sep;41(9):3065-3071.	130	This prospective, randomised, open-label, comparative study involved patients undergoing cataract surgery. The patients' pupils were dilated by a phenylephrine and tropicamide insert (Mydriaser®t, Laboratoires Thea, Clermont Ferrand, France) about 60 min before surgery. Once discharged, all patients were treated with ofloxacin eye drops (Oftaquix®, Santen, Italy) q.i.d for the first week, chloramphenicol 0,25% and dexamethasone 0.13% eye drops (Betabiopital®, Laboratoires Thea, Clermont Ferrand, France) q.i.d for two weeks, and preservative-free 1% diclofenac eye drops (Voltaren Oftabak®, Laboratoires Thea) q.i.d for four weeks. Patients in Group A received a fixed combination of unpreserved trehalose and HA eye drops (Thealoz® gel, Laboratoires Thea, Clermont Ferrand, France), whilst patients in Group B received unpreserved 0.9% sodium chloride eye drops (Hydrabak®, Laboratoires Thea, Clermont Ferrand, France) b.i.d for four weeks.	Trehalose/sodium hyaluronate eye drops were effective in reducing signs and symptoms of dry eye and improving tear film stability

Study	Number of patients	Treatment, posology & duration	Conclusion
Mateo Orobia AJ et al 2017. Effects of 3% trehalose as an adjuvant treatment after LASIK. Clin Ophthalmol. 2017;11:347-353. Published 2017 Feb 16.	13 patients (26 eyes)	Patients were assigned randomly to two treatment groups of different lubricants. In group 1, lubricating drops with hyaluronic acid (HA; 0.15%, Hyabak®, Laboratoires Thea, Clermont Ferrand, France) were given every 2 hours during the first 10 days and 6 times a day from day 11 until 3 months postsurgery. In group 2, the same dosage of Hyabak plus an aqueous ophthalmic solution of 3% trehalose (Thealoz®, Laboratoires Thea, Clermont Ferrand, France) was prescribed 4 times a day, always administered 5 minutes before the HA-rich solution and starting the application 3 days before surgery. Preoperative and postoperative examination I during 90 days.	The results of this exploratory study indicate that the adjuvant treatment with 3% trehalose could be superior with respect to the standard treatment, with improvements in the objective and subjective parameters of tear quality.

Agar, Ashish, Shaojuan Li, Neeraj Agarwal, Minas T. Coroneo, and Mark A. Hill. 2006. "Retinal Ganglion Cell Line Apoptosis Induced by Hydrostatic Pressure." *Brain Research* 1086(1):191–200. doi: 10.1016/j.brainres.2006.02.061.

Agarwal, Priyanka, Jennifer P. Craig, and Ilva D. Rupenthal. 2021. "Formulation Considerations for the Management of Dry Eye Disease." *Pharmaceutics* 13(2):1–19.

Bagnis, Alessandro, Marina Papadia, Riccardo Scotto, and Carlo E. Traverso. 2011. "Antiglaucoma Drugs: The Role of Preservative-Free Formulations." *Saudi Journal of Ophthalmology* 25(4). doi: 10.1016/j.sjopt.2011.08.004.

Baudouin, Christophe. 2012. "Ocular Surface and External Filtration Surgery: Mutual Relationships." *Developments in Ophthalmology* 50. doi: 10.1159/000334791.

Baudouin, Christophe, Antoine Labbé, Hong Liang, Aude Pauly, and Françoise Brignole-Baudouin. 2010. "Preservatives in Eyedrops: The Good, the Bad and the Ugly." *Progress in Retinal and Eye Research* 29(4):312–34.

Baudouin, Christophe, Jean Philippe Nordmann, Philippe Denis, Catherine Creuzot-Garcher, Catherine Allaire, and Claude Trinquand. 2002. "Efficacy of Indomethacin 0.1% and Fluorometholone 0.1% on Conjunctival Inflammation Following Chronic Application of Antiglaucomatous Drugs." *Graefes' Archive for Clinical and Experimental Ophthalmology* 240(11):929–35. doi: 10.1007/s00417-002-0581-9.

Baudouin, Christophe, Pierre-Jean Pisella, Kathleen Fillacier, Marie Goldschild, Frank Becquet, Magda De, and Alain Béchetoille. 1999. *Ocular Surface Inflammatory Changes Induced by Topical Antiglaucoma Drugs Human and Animal Studies*. Vol. 106.

Baudouin, Christophe, Jean-Paul Renard, Jean-Philippe Nordmann, Philippe Denis, Yves Lachkar, Eric Sellem, Jean-François Rouland, Viviane Jeanbat, and Stéphane Bouée. 2013. "Prevalence and Risk Factors for Ocular Surface Disease among Patients Treated over the Long Term for Glaucoma or Ocular Hypertension." *European Journal of Ophthalmology* 23(1). doi: 10.5301/ejo.5000181.

Begley, Carolyn, Barbara Caffery, Robin Chalmers, Ping Situ, Trefford Simpson, and J. Daniel Nelson. 2019. "Review and Analysis of Grading Scales for Ocular Surface Staining." *Ocular Surface* 17(2):208–20.

Benitez-Del-Castillo, Jose M., Teresa del Rio, Teresa Iradier, Jose L. Hernández, Alfredo Castillo, and Julian Garcia-Sanchez. 2001. *Decrease in Tear Secretion and Corneal Sensitivity After Laser In Situ Keratomileusis*. Vol. 20.

Bernardes, Taliana Freitas, and Adriana Alvim Bonfioli. 2010. "Blepharitis." *Seminars in Ophthalmology* 25(3):79–83. doi: 10.3109/08820538.2010.488562.

References

Albietz, Julie M., Suzanne G. McLennan, and Lee M. Lenton. 2003. "Ocular Surface Management of Photorefractive Keratectomy and Laser in Situ Keratomileusis." *Journal of Refractive Surgery (Thorofare, N.J.: 1995)* 19(6).

Alfawaz, Abdullah M., Saeed Algeheda, Sabah S. Jastaneiah, Samir Al-Mansouri, Ahmed Mousa, and Abdullah Al-Assiri. 2014. "Efficacy of Punctal Occlusion in Management of Dry Eyes after Laser In Situ Keratomileusis for Myopia." *Current Eye Research* 39(3). doi: 10.3109/02713683.2013.841258.

Ali Al-Rajhi. 2018. "Dry Eye Syndrome Preferred Practice PAttern." *American Academy of Ophthalmology*.

Ambrosio R, Tervo T, and Wilson S. 2008. "LASIK-Associated Dry Eye and Neurotrophic Epitheliopathy: Pathophysiology and Strategies for Prevention and Treatment." *Journal of Refractive Surgery* 24(4). doi: 10.3928/1081597X-20080401-14.

Aragona, Pasquale, Giuseppe Giannaccare, Rita Mencucci, Pierangela Rubino, Emilia Cantera, and Maurizio Rolando. 2021. "Modern Approach to the Treatment of Dry Eye, a Complex Multifactorial Disease: A P.I.C.A.S.S.O. Board Review." *British Journal of Ophthalmology* 105(4):446–53.

Bagheri, Abbas, Hadi Najmi, Reza Erfanian Salim, and Shahin Yazdani. 2015. "Tear Condition Following Unilateral Ptosis Surgery." Pp. 66–71 in *Orbit*. Vol. 34. Informa Healthcare.

- Bhattacharjee, Kasturi, DivaKant Misra, and Nilutparna Deori. 2017. "Updates on Upper Eyelid Blepharoplasty." *Indian Journal of Ophthalmology* 65(7):551. doi: 10.4103/ijo.IJO_540_17.
- Bielory, Leonard, Eli O. Meltzer, Kelly K. Nichols, Ron Melton, Randall K. Thomas, and Jimmy D. Bartlett. 2013. "An Algorithm for the Management of Allergic Conjunctivitis." *Allergy and Asthma Proceedings* 34(5). doi: 10.2500/aap.2013.34.3695.
- Bower, Kraig S., Rose K. Sia, Denise S. Ryan, Michael J. Mines, and Darlene A. Dartt. 2015. "Chronic Dry Eye in Photorefractive Keratotomy and Laser in Situ Keratomileusis: Manifestations, Incidence, and Predictive Factors." *Journal of Cataract and Refractive Surgery* 41(12):2624–34. doi: 10.1016/j.jcrs.2015.06.037.
- Breusegem, Christophe, Leigh Spielberg, Rita van Ginderdeuren, Evelien Vandewalle, Charlotte Renier, Sara van de Veire, Steffen Fieuws, Thierry Zeyen, and Ingeborg Stalmans. 2010. "Preoperative Nonsteroidal Anti-Inflammatory Drug or Steroid and Outcomes after Trabeculectomy." *Ophthalmology* 117(7). doi: 10.1016/j.ophtha.2009.11.038.
- Broadway, D. C., I. Grierson, J. Stürmer, and R. A. Hitchings. 1996. "Reversal of Topical Antiglaucoma Medication Effects on the Conjunctiva." *Archives of Ophthalmology (Chicago, Ill. : 1960)* 114(3). doi: 10.1001/archophth.1996.01100130258004.
- Bron, Anthony J., Victoria E. Evans, and Janine A. Smith. 2003. "Grading Of Corneal and Conjunctival Staining in the Context of Other Dry Eye Tests." *Cornea* 22(7). doi: 10.1097/00003226-200310000-00008.
- Bron, Anthony J., Cintia S. de Paiva, Sunil K. Chauhan, Stefano Bonini, Eric E. Gabison, Sandeep Jain, Erich Knop, Maria Markoulli, Yoko Ogasawa, Victor Perez, Yuichi Uchino, Norihiko Yokoi, Driss Zoukhrri, and David A. Sullivan. 2017. "TFOS DEWS II Pathophysiology Report." *Ocular Surface* 15(3):438–510.
- Budenz, Donald L., Kara Hoffman, and Anthony Zacchei. 2001. *Glaucoma Filtering Bleb Dysesthesia*.
- Caffery, Barbara, Sruthi Srinivasan, Christopher J. Reaume, Aren Fischer, D. Cappadocia, C. Siffel, and Clara C. Chan. 2019. "Prevalence of Dry Eye Disease in Ontario, Canada: A Population-Based Survey." *Ocular Surface* 17(3). doi: 10.1016/j.jtos.2019.02.011.
- Cagini, Carlo, Giovanni Torroni, Marco Mariniello, Giampiero di Lascio, Gianluca Martone, and Angelo Balestrazzi. 2021a. "Trehalose/Sodium Hyaluronate Eye Drops in Post-Cataract Ocular Surface Disorders." *International Ophthalmology* 41(9):3065–71. doi: 10.1007/s10792-021-01869-z.
- Cagini, Carlo, Giovanni Torroni, Marco Mariniello, Giampiero di Lascio, Gianluca Martone, and Angelo Balestrazzi. 2021b. "Trehalose/Sodium Hyaluronate Eye Drops in Post-Cataract Ocular Surface Disorders." *International Ophthalmology* 41(9). doi: 10.1007/s10792-021-01869-z.
- Caretti, L., A. la Gloria Valerio, R. Piermarocchi, G. Badin, G. Verzola, F. Masarà, T. Scalora, and Cristina Monterosso. 2019. "Efficacy of Carbomer Sodium Hyaluronate Trehalose vs Hyaluronic Acid to Improve Tear Film Instability and Ocular Surface Discomfort after Cataract Surgery." *Clinical Ophthalmology Volume 13*. doi: 10.2147/OPHT.S208256.
- Cetinkaya, Servet, Emine Mestan, Nursen Oncel Acir, Yasemin Fatma Cetinkaya, Zeynep Dadaci, and Halil Ibrahim Yener. 2015. "The Course of Dry Eye after Phacoemulsification Surgery." *BMC Ophthalmology* 15(1). doi: 10.1186/s12886-015-0058-3.
- Chang, Jessica R., Euna Koo, Elvira Agrón, Joelle Hallak, Traci Clemmons, Dimitri Azar, Robert D. Sperduto, Frederick L. Ferris, and Emily Y. Chew. 2011. "Risk Factors Associated with Incident Cataracts and Cataract Surgery in the Age-Related Eye Disease Study (AREDS)." *Ophthalmology* 118(11):2113–19. doi: 10.1016/j.ophtha.2011.03.032.
- Chiambaretta, Frédéric, Serge Doan, Marc Labetoulle, Nicolas Rocher, Lamia el Fekih, Riadh Messaoud, Moncef Khairallah, and Christophe Baudouin. 2017. "A Randomized, Controlled Study of the Efficacy and Safety of a New Eyedrop Formulation for Moderate to Severe Dry Eye Syndrome." *European Journal of Ophthalmology* 27(1). doi: 10.5301/ejo.5000836.
- Chien, Kaung-Jen, Chi-Ting Horng, Yu-Syuan Huang, Yi-Hsien Hsieh, Chau-Jong Wang, Jai-Sing Yang, Chi-Cheng Lu, and Fu-An Chen. 2017. "Effects of Lycium Barbarum (Goji Berry) on Dry Eye Disease in Rats." *Molecular Medicine Reports*. doi: 10.3892/mmr.2017.7947.
- Cho, Yang Kyeung, and Man Soo Kim. 2009. "Dry Eye After Cataract Surgery and Associated Intraoperative Risk Factors." *Korean Journal of Ophthalmology* 23(2). doi: 10.3341/kjo.2009.23.2.65.
- Cochener, Béatrice, Albane Cassan, and Laura Omiel. 2018. "Prevalence of Meibomian Gland Dysfunction at the Time of Cataract Surgery." *Journal of Cataract and Refractive Surgery* 44(2). doi: 10.1016/j.jcrs.2017.10.050.
- Cohen, Eyal, and Oriël Spierer. 2018. "Dry Eye Post-Laser-Assisted in Situ Keratomileusis: Major Review and Latest Updates." *Journal of Ophthalmology* 2018.
- Craig, Jennifer P., J. Daniel Nelson, Dimitri T. Azar, Carlos Belmonte, Anthony J. Bron, Sunil K. Chauhan, Cintia S. de Paiva, José A. P. Gomes, Katherine M. Hammitt, Lyndon Jones, Jason J. Nichols, Kelly K. Nichols, Gary D. Novack, Fiona J. Stapleton, Mark D. P. Willcox, James S. Wolffsohn, and David A. Sullivan. 2017. "TFOS DEWS II Report Executive Summary." *Ocular Surface* 15(4):802–12.
- Craig, Jennifer P., Kelly K. Nichols, Esen K. Akpek, Barbara Caffery, Harminder S. Dua, Choun Ki Joo, Zuguo Liu, J. Daniel Nelson, Jason J. Nichols, Kazuo Tsubota, and Fiona Stapleton. 2017. "TFOS DEWS II Definition and Classification Report." *Ocular Surface* 15(3):276–83.
- Cui, Lian, Ying Li, Hyo Seok Lee, Jee Myung Yang, Won Choi, and Kyung Chul Yoon. 2018. "Effect of Diquafosol Tetrasodium 3% on the Conjunctival Surface and Clinical Findings after Cataract Surgery in Patients with Dry Eye." *International Ophthalmology* 38(5):2021–30. doi: 10.1007/s10792-017-0693-1.
- Cvenkel, Barbara, Andreja Nataša Kopitar, and Alojz Ihan. 2013. "Correlation Between Filtering Bleb Morphology, Expression of Inflammatory Marker HLA-DR by Ocular Surface, and Outcome of Trabeculectomy." *Journal of Glaucoma* 22(1):15–20. doi: 10.1097/IJG.0b013e3182254051.
- Donnenfeld, Eric D., Renée Solomon, Calvin W. Roberts, John R. Wittpenn, Marguerite B. McDonald, and Henry D. Perry. 2010. "Cyclosporine 0.05% to Improve Visual Outcomes after Multifocal Intraocular Lens Implantation." *Journal of Cataract and Refractive Surgery* 36(7). doi: 10.1016/j.jcrs.2009.12.049.
- D'Souza, Sharon, Edwin James, Rishi Swarup, Sheetal Mahuvakar, Aditya Pradhan, and Krati Gupta. 2020. "Algorithmic Approach to Diagnosis and Management of Post-Refractive Surgery Dry Eye Disease." *Indian Journal of Ophthalmology* 68(12):2888–94. doi: 10.4103/ijo.IJO_1957_20.

- Elabjer, Biljana Kuzmanović, Leon Marković, Mirjana Bjeloš, Mladen Bušić, Daliborka Miletić, and Eva Kos. 2020. "A Retrospective Data Review Confirms That Topical Preservative-Free Hydrocortisone Improves Inflammation in Dry Eye Disease." *Clinical Ophthalmology* 14. doi: 10.2147/OPTH.S283655.
- FAGIEN, S. 2004. "Reducing the Incidence of Dry Eye Symptoms after Blepharoplasty." *Aesthetic Surgery Journal* 24(5). doi: 10.1016/j.asj.2004.07.001.
- Fakhraie, Ghasem, Joao F. Lopes, George L. Spaeth, Juliana Almodin, Parul Ichhpujani, and Marlene R. Moster. 2009. "Effects of Postoperative Cyclosporine Ophthalmic Emulsion 0.05% (Restasis) Following Glaucoma Surgery." *Clinical & Experimental Ophthalmology* 37(9). doi: 10.1111/j.1442-9071.2009.02134.x.
- Fan, Wanlin, Alexander C. Rokohl, Yongwei Guo, and Ludwig M. Heindl. 2021. "Ocular Surface and Tear Film Changes after Eyelid Surgery." *Annals of Eye Science* 6. doi: 10.21037/aes-20-98.
- Farrand, Kimberly F., Moshe Fridman, Ipek Özer Stillman, and Debra A. Schaumberg. 2017. "Prevalence of Diagnosed Dry Eye Disease in the United States Among Adults Aged 18 Years and Older." *American Journal of Ophthalmology* 182. doi: 10.1016/j.ajo.2017.06.033.
- Favuzza, Eleonora, Michela Cennamo, Lidia Vicchio, Fabrizio Giansanti, and Rita Mencucci. 2020. "Protecting the Ocular Surface in Cataract Surgery: The Efficacy of the Perioperative Use of a Hydroxypropyl Guar and Hyaluronic Acid Ophthalmic Solution." *Clinical Ophthalmology* Volume 14. doi: 10.2147/OPTH.S259704.
- Fogagnolo, Paolo, Eleonora Favuzza, Daniele Marchina, Michela Cennamo, Roberto Vignapiano, Chiara Quisiana, Luca Rossetti, and Rita Mencucci. 2020. "New Therapeutic Strategy and Innovative Lubricating Ophthalmic Solution in Minimizing Dry Eye Disease Associated with Cataract Surgery: A Randomized, Prospective Study." *Advances in Therapy* 37(4). doi: 10.1007/s12325-020-01288-z.
- Fondi, Klemens, Kata Miháلتz, and Pia Veronika Vécsei-Marlovits. 2021. "Efficacy of Topical Hydrocortisone in Combination with Topical Cyclosporin A for the Treatment of Dry Eye Disease in Patients with Sjögren Syndrome." *Journal of Ophthalmology* 2021:1–8. doi: 10.1155/2021/7584370.
- Fondi, Klemens, Piotr A. Wozniak, Doreen Schmidl, Ahmed M. Bata, Katarzyna J. Witkowska, Alina Popa-Cherecheanu, Leopold Schmetterer, and Gerhard Garhöfer. 2018. "Effect of Hyaluronic Acid/Trehalose in Two Different Formulations on Signs and Symptoms in Patients with Moderate to Severe Dry Eye Disease." *Journal of Ophthalmology* 2018. doi: 10.1155/2018/4691417.
- Gipson, Ilene K. 2007. "The Ocular Surface: The Challenge to Enable and Protect Vision." *Investigative Ophthalmology & Visual Science* 48(10). doi: 10.1167/iovs.07-0770.
- Gomes, José Alvaro P., Dimitri T. Azar, Christophe Baudouin, Nathan Efron, Masatoshi Hirayama, Jutta Horwath-Winter, Terry Kim, Jodhbir S. Mehta, Elisabeth M. Messmer, Jay S. Pepose, Virender S. Sangwan, Alan L. Weiner, Steven E. Wilson, and James S. Wolffsohn. 2017. "TFOS DEWS II Iatrogenic Report." *Ocular Surface* 15(3):511–38.
- Gonzalez-Andrades, Miguel, Pablo Argüeso, and Ilene Gipson. 2019. "Corneal Anatomy." Pp. 3–12 in.
- Gupta, Divakar, and Philip P. Chen. 2016. "Glaucoma." *American Family Physician* 93(8):668–74.
- Hamada, Samer, Tara C. B. Moore, Jonathan E. Moore, Madonna G. Al-Dreih, Anas Anbari, and Sunil Shah. 2016. "Assessment of the Effect of Cyclosporine-A 0.05% Emulsion on the Ocular Surface and Corneal Sensation Following Cataract Surgery." *Contact Lens and Anterior Eye* 39(1). doi: 10.1016/j.clae.2015.07.003.
- Hamawy, Adam H., Jordan P. Farkas, Steven Fagien, and Rod J. Rohrich. 2009a. "Preventing and Managing Dry Eyes after Periorbital Surgery: A Retrospective Review." *Plastic & Reconstructive Surgery* 123(1). doi: 10.1097/PRS.0b013e31819346ea.
- Hamawy, Adam H., Jordan P. Farkas, Steven Fagien, and Rod J. Rohrich. 2009b. "Preventing and Managing Dry Eyes after Periorbital Surgery: A Retrospective Review." *Plastic and Reconstructive Surgery* 123(1):353–59. doi: 10.1097/PRS.0b013e31819346ea.
- Han, Kyung Eun, Sang Chul Yoon, Ji Min Ahn, Sang Min Nam, R. Doyle Stulting, Eung Kweon Kim, and Kyoung Yul Seo. 2014. "Evaluation of Dry Eye and Meibomian Gland Dysfunction after Cataract Surgery." *American Journal of Ophthalmology* 157(6). doi: 10.1016/j.ajo.2014.02.036.
- Hassan, Ziad, Eszter Szalai, Andras Berta, Laszlo Modis, and Gabor Nemeth. 2013. "Assessment of Tear Osmolarity and Other Dry Eye Parameters in Post-LASIK Eyes." *Cornea* 32(7). doi: 10.1097/ICO.0b013e318290496d.
- Henry JC, Peace JH, Stewart JA, and Stewart CW. 2008. "Efficacy, Safety, and Improved Tolerability of Travoprost BAK-Free Ophthalmic Solution Compared with Prior Prostaglandin Therapy." *Clinical Ophthalmology*. doi: 10.2147/OPTH.S3881.
- Hovanesian, John, Alice Epitropoulos, Eric D. Donnenfeld, and Jack T. Holladay. 2020. "The Effect of Lifitegrast on Refractive Accuracy and Symptoms in Dry Eye Patients Undergoing Cataract Surgery." *Clinical Ophthalmology* Volume 14. doi: 10.2147/OPTH.S264520.
- Iglesias, Eugenia, Ravin Sajjani, Roy C. Levitt, Constantine D. Sarantopoulos, and Anat Galor. 2018. "Epidemiology of Persistent Dry Eye-Like Symptoms After Cataract Surgery." *Cornea* 37(7). doi: 10.1097/ICO.0000000000001491.
- Jaenen, N., C. Baudouin, P. Pouliquen, G. Manni, A. Figueiredo, T. Zeyen, Uz Sint Rafaël, and Leuven -Belgium. 2007. *Ocular Symptoms and Signs with Preserved and Preservative-Free Glaucoma Medications*.
- Januleviciene, Ingrida. 2012. "Effects of Preservative-Free Tafluprost on Tear Film Osmolarity, Tolerability, and Intraocular Pressure in Previously Treated Patients with Open-Angle Glaucoma." *Clinical Ophthalmology*. doi: 10.2147/OPTH.S28104.
- Jee, Donghyun, Minji Park, Hee Jin Lee, Man Soo Kim, and Eun Chul Kim. 2015. "Comparison of Treatment with Preservative-Free versus Preserved Sodium Hyaluronate 0.1% and Fluorometholone 0.1% Eyedrops after Cataract Surgery in Patients with Preexisting Dry-Eye Syndrome." *Journal of Cataract and Refractive Surgery* 41(4). doi: 10.1016/j.jcrs.2014.11.034.
- Ji, Hong, Yingting Zhu, Yingying Zhang, Zuohong Li, Jian Ge, and Yehong Zhuo. 2016. "Dry Eye Disease in Patients with Functioning Filtering Blebs after Trabeculectomy." *PLoS ONE* 11(3). doi: 10.1371/journal.pone.0152696.
- Jiang, Donghong, Xiangqian Xiao, Tongsheng Fu, Alireza Mashaghi, Qinghuai Liu, and Jiayu Hong. 2016. "Transient Tear Film Dysfunction after Cataract Surgery in Diabetic Patients." *PLOS ONE* 11(1). doi: 10.1371/journal.pone.0146752.


- Jones, Lyndon, Laura E. Downie, Donald Korb, Jose M. Benítez-del-Castillo, Reza Dana, Sophie X. Deng, Pham N. Dong, Gerd Geerling, Richard Yudi Hida, Yang Liu, Kyoung Yul Seo, Joseph Tauber, Tais H. Wakamatsu, Jianjiang Xu, James S. Wolffsohn, and Jennifer P. Craig. 2017. "TFOS DEWS II Management and Therapy Report." *Ocular Surface* 15(3):575–628.
- Jun, Ikhyun, Seonghee Choi, Geun Young Lee, Young Joon Choi, Hyung Keun Lee, Eung Kweon Kim, Kyoung Yul Seo, and Tae-im Kim. 2019. "Effects of Preservative-Free 3% Diquafosol in Patients with Pre-Existing Dry Eye Disease after Cataract Surgery: A Randomized Clinical Trial." *Scientific Reports* 9(1). doi: 10.1038/s41598-019-49159-0.
- Jung, Ji Won, Soo Jung Han, Sang Min Nam, Tae-im Kim, Eung Kweon Kim, and Kyoung Yul Seo. 2016. "Meibomian Gland Dysfunction and Tear Cytokines after Cataract Surgery According to Preoperative Meibomian Gland Status." *Clinical & Experimental Ophthalmology* 44(7). doi: 10.1111/ceo.12744.
- Kagkellaris, Kostas A., Olga E. Makri, Constantine D. Georgakopoulos, and George D. Panayiotakopoulos. 2018. "An Eye for Azithromycin: Review of the Literature." *Therapeutic Advances in Ophthalmology* 10:251584141878362. doi: 10.1177/2515841418783622.
- Kallab, Martin, Stephan Szegedi, Nikolaus Hommer, Hannes Stegmann, Semira Kaya, René M. Werkmeister, Doreen Schmidl, Leopold Schmetterer, and Gerhard Garhöfer. 2020. "Correction to: Topical Low Dose Preservative-Free Hydrocortisone Reduces Signs and Symptoms in Patients with Chronic Dry Eye: A Randomized Clinical Trial (Advances in Therapy, (2020), 37, 1, (329-341), 10.1007/S12325-019-01137-8)." *Advances in Therapy* 37(1).
- kanellopoulos, anastasios john. 2019. "Incidence and Management of Symptomatic Dry Eye Related to LASIK for Myopia, with Topical Cyclosporine A." *Clinical Ophthalmology Volume 13*. doi: 10.2147/OPTH.S188521.
- Kasetsuwan, Ngamjit, Vannarat Satitpitakul, Theerapa Changul, and Supharat Jariyakosol. 2013. "Incidence and Pattern of Dry Eye after Cataract Surgery." *PLoS ONE* 8(11). doi: 10.1371/journal.pone.0078657.
- Khanal, Santosh, Alan Tomlinson, Leonard Esakowitz, Priya Bhatt, David Jones, Shahriar Nabili, and Subhanjan Mukerji. 2008. "Changes in Corneal Sensitivity and Tear Physiology after Phacoemulsification." *Ophthalmic and Physiological Optics* 28(2). doi: 10.1111/j.1475-1313.2008.00539.x.
- Khanna, Rohit C. 2017. "Ocular Surface Disorders." *Community Eye Health* 30(99).
- Kim, Sangyoon, Jonghoon Shin, and Ji Eun Lee. 2021. "A Randomised, Prospective Study of the Effects of 3% Diquafosol on Ocular Surface Following Cataract Surgery." *Scientific Reports* 11(1). doi: 10.1038/s41598-021-88589-7.
- Kim, Yeseul, Chan Hee Moon, Bo Yeon Kim, and Sun Young Jang. 2019. "Oral Hyaluronic Acid Supplementation for the Treatment of Dry Eye Disease: A Pilot Study." *Journal of Ophthalmology* 2019. doi: 10.1155/2019/5491626.
- King, A., A. Azuara-Blanco, and A. Tuulonen. 2013. "Glaucoma." *BMJ* 346(jun11 1):f3518–f3518. doi: 10.1136/bmj.f3518.
- Kobashi, Hidenaga, Kazutaka Kamiya, and Kimiya Shimizu. 2017. "Dry Eye After Small Incision Lenticule Extraction and Femtosecond Laser-Assisted LASIK." *Cornea* 36(1). doi: 10.1097/ICO.0000000000000999.
- Koh, Shizuka. 2015. "Clinical Utility of 3% Diquafosol Ophthalmic Solution in the Treatment of Dry Eyes." *Clinical Ophthalmology*. doi: 10.2147/OPTH.S69486.
- Labetoulle, Marc, Christophe Baudouin, Margarita Calonge, Jesús Merayo-Llodes, Kostas G. Boboridis, Yonca A. Akova, Pasquale Aragona, Gerd Geerling, Elisabeth M. Messmer, and José Benítez-del-Castillo. 2019. "Role of Corneal Nerves in Ocular Surface Homeostasis and Disease." *Acta Ophthalmologica* 97(2):137–45.
- Lam, Janice, Tina T. Wong, and Louis Tong. 2015. "Ocular Surface Disease in Posttrabeculectomy/Mitomycin C Patients." *Clinical Ophthalmology* 9:187–91. doi: 10.2147/OPTH.S70721.
- Leatherbarrow, Brian, and Konal Saha. 2013. "Complications of Blepharoplasty." *Facial Plastic Surgery: FPS* 29(4). doi: 10.1055/s-0033-1349362.
- Lee, Jang Hoon, In Seok Song, Kyoung Lae Kim, and Sam Young Yoon. 2016. "Effectiveness and Optical Quality of Topical 3.0% Diquafosol versus 0.05% Cyclosporine A in Dry Eye Patients Following Cataract Surgery." *Journal of Ophthalmology* 2016. doi: 10.1155/2016/8150757.
- Lee, Ji Hwan, Kyung Min, Se Kyung Kim, Eung Kweon Kim, and Tae im Kim. 2014. "Inflammatory Cytokine and Osmolarity Changes in the Tears of Dry Eye Patients Treated with Topical 1% Methylprednisolone." *Yonsei Medical Journal* 55(1). doi: 10.3349/ymj.2014.55.1.203.
- Lee, S. Y., T. T. Wong, J. Chua, C. Boo, Y. F. Soh, and L. Tong. 2013. "Effect of Chronic Anti-Glaucoma Medications and Trabeculectomy on Tear Osmolarity." *Eye (Basingstoke)* 27(10):1142–50. doi: 10.1038/eye.2013.144.
- Lee, W. Barry, Clinton D. McCord, Naveen Somia, and Haideh Hirmand. 2008. "Optimizing Blepharoplasty Outcomes in Patients with Previous Laser Vision Correction." *Plastic and Reconstructive Surgery* 122(2). doi: 10.1097/PRS.0b013e31817d61d9.
- Lemp MA. 2007. "The Definition and Classification of Dry Eye Disease: Report of the Definition and Classification Subcommittee of the International Dry Eye Workshop (2007)." *The Ocular Surface* 5(2). doi: 10.1016/S1542-0124(12)70081-2.
- Lenton, L. M., and J. M. Albietz. 1999. "Effect of Carmellose-Based Artificial Tears on the Ocular Surface in Eyes after Laser in Situ Keratomileusis." *Journal of Refractive Surgery (Thorofare, N.J.: 1995)* 15(2 Suppl):S227-31.
- Levitt, Alexandra E., Anat Galor, Jayne S. Weiss, Elizabeth R. Felix, Eden R. Martin, Dennis J. Patin, Konstantinos D. Sarantopoulos, and Roy C. Levitt. 2015. "Chronic Dry Eye Symptoms after LASIK: Parallels and Lessons to Be Learned from Other Persistent Post-Operative Pain Disorders." *Molecular Pain* 11(1).
- Li, Meiyang, Lingling Niu, Bing Qin, Zimei Zhou, Katherine Ni, Qihua Le, Jun Xiang, Anji Wei, Weiping Ma, and Xingtao Zhou. 2013. "Confocal Comparison of Corneal Reinnervation after Small Incision Lenticule Extraction (SMILE) and Femtosecond Laser in Situ Keratomileusis (FS-LASIK)." *PLoS ONE* 8(12). doi: 10.1371/journal.pone.0081435.
- Li, Xin, Ye He, Ting Su, Ying Tian, Yujue Wang, Xiaobo Xia, and Weitao Song. 2018. "Comparison of Clinical Outcomes between Cystotome-Assisted Prechop Phacoemulsification Surgery and Conventional Phacoemulsification Surgery for Hard Nucleus Cataracts." *Medicine* 97(46). doi: 10.1097/MD.00000000000013124.
- Li, Xue-Min, Lizhong Hu, Jinping Hu, and Wei Wang. n.d. Investigation of Dry Eye Disease and Analysis of the Pathogenic Factors in Patients after Cataract Surgery.

- Liu, Ting, Guanting Lu, Kaijian Chen, Qiuxia Kan, and Ji Bai. 2019. "Visual and Optical Quality Outcomes of SMILE and FS-LASIK for Myopia in the Very Early Phase after Surgery." *BMC Ophthalmology* 19(1). doi: 10.1186/s12886-019-1096-z.
- Marsh, P. 1999. "Topical Nonpreserved Methylprednisolone Therapy for Keratoconjunctivitis Sicca in Sjögren Syndrome." *Ophthalmology* 106(4). doi: 10.1016/S0161-6420(99)90171-9.
- McCord, Clinton D., Peter Kreymerman, Foad Nahai, and Joseph D. Walrath. 2013. "Management of Postblepharoplasty Chemosia." *Aesthetic Surgery Journal* 33(5):654–61. doi: 10.1177/1090820X13487016.
- Mélik Parsadaniantz, Stéphane, Annabelle Réaux-le Goazigo, Anaïs Sapienza, Christophe Habas, and Christophe Baudouin. 2020. "Glaucoma: A Degenerative Optic Neuropathy Related to Neuroinflammation?" *Cells* 9(3):535. doi: 10.3390/cells9030535.
- Mencucci, Rita, Carlotta Boccalini, Roberto Caputo, and Eleonora Favuzza. 2015. "Effect of a Hyaluronic Acid and Carboxymethylcellulose Ophthalmic Solution on Ocular Comfort and Tear-Film Instability after Cataract Surgery." *Journal of Cataract and Refractive Surgery* 41(8). doi: 10.1016/j.jcrs.2014.12.056.
- Mencucci, Rita, Eleonora Favuzza, Giulia Decandia, Michela Cennamo, and Fabrizio Giansanti. 2021. "Hyaluronic Acid/Trehalose Ophthalmic Solution in Reducing Post-Cataract Surgery Dry Eye Signs and Symptoms: A Prospective, Interventional, Randomized, Open-Label Study." *Journal of Clinical Medicine* 10(20):4699. doi: 10.3390/jcm10204699.
- Mencucci, Rita, Roberto Vignapiano, Pierangela Rubino, Eleonora Favuzza, Emilia Cantera, Pasquale Aragona, and Maurizio Rolando. 2021a. "Iatrogenic Dry Eye Disease: Dealing with the Conundrum of Post-Cataract Discomfort. A P.I.C.A.S.S.O. Board Narrative Review." *Ophthalmology and Therapy* 10(2):211–23.
- Mencucci, Rita, Roberto Vignapiano, Pierangela Rubino, Eleonora Favuzza, Emilia Cantera, Pasquale Aragona, and Maurizio Rolando. 2021b. "Iatrogenic Dry Eye Disease: Dealing with the Conundrum of Post-Cataract Discomfort. A P.I.C.A.S.S.O. Board Narrative Review." *Ophthalmology and Therapy* 10(2):211–23.
- Messmer, Elisabeth M. 2015. "The Pathophysiology, Diagnosis, and Treatment of Dry Eye Disease." *Deutsches Aerzteblatt Online*. doi: 10.3238/arztebl.2015.0071.
- Messmer, Elisabeth M. 2015. "The Pathophysiology, Diagnosis, and Treatment of Dry Eye Disease." *Deutsches Arzteblatt International* 112(5). doi: 10.3238/arztebl.2015.0071.
- Mian, Shahzad I., Amy Y. Li, Satavisha Dutta, David C. Musch, and Roni M. Shtein. 2009. "Dry Eyes and Corneal Sensation after Laser in Situ Keratomileusis with Femtosecond Laser Flap Creation. Effect of Hinge Position, Hinge Angle, and Flap Thickness." *Journal of Cataract and Refractive Surgery* 35(12):2092–98. doi: 10.1016/j.jcrs.2009.07.009.
- Milner, Mark S., Kenneth A. Beckman, Jodi I. Luchs, Quentin B. Allen, Richard M. Awdeh, John Berdahl, Thomas S. Boland, Carlos Buznego, Joseph P. Gira, Damien F. Goldberg, David Goldman, Raj K. Goyal, Mitchell A. Jackson, James Katz, Terry Kim, Parag A. Majmudar, Ranjan P. Malhotra, Marguerite B. McDonald, Rajesh K. Rajpal, Tal Raviv, Sheri Rowen, Neda Shamie, Jonathan D. Solomon, Karl Stonecipher, Shachar Tauber, William Trattler, Keith A. Walter, George O. Waring, Robert J. Weinstock, William F. Wiley, and Elizabeth Yeu. 2016. "Dysfunctional Tear Syndrome: Dry Eye Disease and Associated Tear Film Disorders - New Strategies for Diagnosis and Treatment." *Current Opinion in Ophthalmology* 27:3–47.
- Miura, Maria, Takenori Inomata, Masahiro Nakamura, Jaemyoung Sung, Ken Nagino, Akie Midorikawa-Inomata, Jun Zhu, Keiichi Fujimoto, Yuichi Okumura, Kenta Fujio, Kunihiko Hirose, Yasutsugu Akasaki, Mizu Kuwahara, Atsuko Eguchi, Hurrarnhon Shokirova, and Akira Murakami. 2022. "Prevalence and Characteristics of Dry Eye Disease After Cataract Surgery: A Systematic Review and Meta-Analysis." *Ophthalmology and Therapy*. doi: 10.1007/s40123-022-00513-y.
- Miyake, Kensaku, and Norihiko Yokoi. 2017. "Influence on Ocular Surface after Cataract Surgery and Effect of Topical Diquafosol on Postoperative Dry Eye: A Multicenter Prospective Randomized Study." *Clinical Ophthalmology Volume 11*. doi: 10.2147/OPHT.S129178.
- Monjane, Mário J., and William Makupa. 2020. "Prevalence and Associated Factors of Dry Eye among Glaucoma Patients at KCMC Eye Department." *Open Journal of Ophthalmology* 10(02). doi: 10.4236/ojoph.2020.102017.
- Mori, Yosai, Ryohei Nejima, Ayami Masuda, Yoko Maruyama, Keiichiro Minami, Kazunori Miyata, and Shiro Amano. 2014. "Effect of Diquafosol Tetrasodium Eye Drop for Persistent Dry Eye After Laser In Situ Keratomileusis." *Cornea* 33(7). doi: 10.1097/ICO.000000000000136.
- Moshirfar, Majid, Udit M. Bhavsar, Kathryn M. Durnford, Shannon E. McCabe, Yasmyne C. Ronquillo, Adam L. Lewis, and Phillip C. Hoopes. 2021. "Neuropathic Corneal Pain Following LASIK Surgery: A Retrospective Case Series." *Ophthalmology and Therapy* 10(3):677–89. doi: 10.1007/s40123-021-00358-x.
- Movahedan, Asadolah, and Ali R. Djalilian. 2012. "Cataract Surgery in the Face of Ocular Surface Disease." *Current Opinion in Ophthalmology* 23(1). doi: 10.1097/ICU.0b013e32834d90b7.
- Mudhol, Rekha, and Rolika Bansal. 2021. "Cross-Linked Hyaluronic Acid Viscoelastic Scleral Implant in Trabeculectomy." *Indian Journal of Ophthalmology* 69(5). doi: 10.4103/ijo.IJO_2462_20.
- Murakami, Yohko, and Edward E. Manche. 2012. "Prospective, Randomized Comparison of Self-Reported Postoperative Dry Eye and Visual Fluctuation in LASIK and Photorefractive Keratectomy." *Ophthalmology* 119(11). doi: 10.1016/j.ophtha.2012.06.013.
- Mylla Boso, Ana Luiza, Erica Gasperi, Leticia Fernandes, Vital Paulino Costa, and Monica Alves. 2020. "Impact of Ocular Surface Disease Treatment in Patients with Glaucoma." *Clinical Ophthalmology Volume 14*. doi: 10.2147/OPHT.S229815.
- Naderi, Khayam, Jack Gormley, and David O'Brart. 2020a. "Cataract Surgery and Dry Eye Disease: A Review." *European Journal of Ophthalmology* 30(5):840–55.
- Naderi, Khayam, Jack Gormley, and David O'Brart. 2020b. "Cataract Surgery and Dry Eye Disease: A Review." *European Journal of Ophthalmology* 30(5):840–55.
- Naik, Milind N., Santosh G. Honavar, Sima Das, Savari Desai, and Niteen Dhepe. 2009. "Blepharoplasty: An Overview." *Journal of Cutaneous and Aesthetic Surgery* 2(1). doi: 10.4103/0974-2077.53092.
- Nettune, Gregory R., and Stephen C. Pflugfelder. 2010. "Post-LASIK Tear Dysfunction and Dysesthesia." *The Ocular Surface* 8(3). doi: 10.1016/s1542-0124(12)70224-0.
- Nizami, Adnan A., and Arun C. Gulani. 2022. *Cataract*.
- Ntonti, Panagiota, Eirini-Kanella Panagiotopoulou, Georgios Karastiras, Nektarios Breyannis, Sevasti Tsironi, and Georgios Labiris. 2019. "Impact of 0.1% Sodium Hyaluronate and 0.2% Sodium Hyaluronate Artificial Tears on Postoperative Discomfort Following Cataract Extraction Surgery: A Comparative Study." *Eye and Vision* 6(1). doi: 10.1186/s40662-019-0131-8.

- Omari A, and Shaheen KW. 2021. "Upper Eyelid Reconstruction." StatPearls.
- Pacella, Salvatore J., and Mark A. Codner. 2010. "Minor Complications after Blepharoplasty: Dry Eyes, Chemosis, Granulomas, Ptosis, and Scleral Show." *Plastic and Reconstructive Surgery* 125(2):709–18. doi: 10.1097/PRS.0b013e3181c830c7.
- de Paiva, Cintia S., Zhuo Chen, Douglas D. Koch, M. Bowes Hamill, Francis K. Manuel, Sohela S. Hassan, Kirk R. Wilhelmus, and Stephen C. Pflugfelder. 2006. "The Incidence and Risk Factors for Developing Dry Eye After Myopic LASIK." *American Journal of Ophthalmology* 141(3). doi: 10.1016/j.ajo.2005.10.006.
- Park, Yuli, Hyung bin Hwang, and Hyun Seung Kim. 2016. "Observation of Influence of Cataract Surgery on the Ocular Surface." *PLOS ONE* 11(10). doi: 10.1371/journal.pone.0152460.
- Peyman GA, Sanders DR, Battle JF, Feliz R, and Cabrera G. 2008. "Cyclosporine 0.05% Ophthalmic Preparation to Aid Recovery From Loss of Corneal Sensitivity After LASIK." *Journal of Refractive Surgery* 24(4):337–43. doi: 10.3928/1081597X-20080401-04.
- Pinho Tavares, Fabiana de, Raphael Stehling Fernandes, Taliana Freitas Bernardes, Adriana Alvim Bonfili, and Eduardo Jorge Carneiro Soares. 2010. "Dry Eye Disease." *Seminars in Ophthalmology* 25(3):84–93. doi: 10.3109/08820538.2010.488568.
- Pleyer, Uwe, Paul G. Ursell, and Paolo Rama. 2013. "Intraocular Pressure Effects of Common Topical Steroids for Post-Cataract Inflammation: Are They All the Same?" *Ophthalmology and Therapy* 2(2):55–72. doi: 10.1007/s40123-013-0020-5.
- Prischmann, Jess, Ahmed Sufyan, Jonathan Y. Ting, Chad Ruffin, and Stephen W. Perkins. 2013. "Dry Eye Symptoms and Chemosis Following Blepharoplasty: A 10-Year Retrospective Review of 892 Cases in a Single-Surgeon Series." *JAMA Facial Plastic Surgery* 15(1):39–46.
- Quinto, Guilherme G., Walter Camacho, and Ashley Behrens. 2008. "Postrefractive Surgery Dry Eye." *Current Opinion in Ophthalmology* 19(4). doi: 10.1097/ICU.0b013e3283009ef8.
- Rangarajan, Rekha, Brian Kraybill, Abayomi Ogundele, and Howard A. Ketelson. 2015. "Effects of a Hyaluronic Acid/Hydroxypropyl Guar Artificial Tear Solution on Protection, Recovery, and Lubricity in Models of Corneal Epithelium." *Journal of Ocular Pharmacology and Therapeutics* 31(8):491–97. doi: 10.1089/jop.2014.0164.
- Reinstein, Dan Z., Timothy J. Archer, and Marine Gobbe. 2014. "Small Incision Lenticule Extraction (SMILE) History, Fundamentals of a New Refractive Surgery Technique and Clinical Outcomes." *Eye and Vision* 1(1). doi: 10.1186/s40662-014-0003-1.
- Rodriguez, Alexandra E., Jose L. Rodriguez-Prats, Islam M. Hamdi, Ahmed Galal, Mohamed Awadalla, and Jorge L. Alio. 2007. "Comparison of Goblet Cell Density after Femtosecond Laser and Mechanical Microkeratome in LASIK." *Investigative Ophthalmology and Visual Science* 48(6):2570–75. doi: 10.1167/iovs.06-1259.
- Rossi, Gemma Caterina Maria, Carmine Tinelli, Gian Maria Pasinetti, Giovanni Milano, and Paolo Emilio Bianchi. 2009. "Dry Eye Syndrome-Related Quality of Life in Glaucoma Patients." *European Journal of Ophthalmology* 19(4). doi: 10.1177/112067210901900409.
- Sajjani, Ravin, Sophia Raia, Allister Gibbons, Victoria Chang, Carol L. Karp, Constantine D. Sarantopoulos, Roy C. Levitt, and Anat Galor. 2018. "Epidemiology of Persistent Postsurgical Pain Manifesting as Dry Eye-Like Symptoms After Cataract Surgery." *Cornea* 37(12). doi: 10.1097/ICO.0000000000001741.
- Salib, George M., Marguerite B. McDonald, and Michael Smolek. 2006. "Safety and Efficacy of Cyclosporine 0.05% Drops versus Unpreserved Artificial Tears in Dry-Eye Patients Having Laser in Situ Keratomileusis." *Journal of Cataract and Refractive Surgery* 32(5). doi: 10.1016/j.jcrs.2005.10.034.
- Salman, İlknur Akyol, and Cemal Gündoğdu. 2010. "Epithelial Healing in Experimental Corneal Alkali Wounds with Nondiluted Autologous Serum Eye Drops." *Cutaneous and Ocular Toxicology* 29(2). doi: 10.3109/15569521003709558.
- Salomão, Marcella Q., Renato Ambrósio, and Steven E. Wilson. 2009. "Dry Eye Associated with Laser in Situ Keratomileusis: Mechanical Microkeratome versus Femtosecond Laser." *Journal of Cataract and Refractive Surgery* 35(10). doi: 10.1016/j.jcrs.2009.05.032.
- Salvi, S. M. 2006. "Ageing Changes in the Eye." *Postgraduate Medical Journal* 82(971). doi: 10.1136/pgmj.2005.040857.
- Sambhi, Raman-Deep Singh, Gagan Deep Singh Sambhi, Rookaya Mather, and Monali S. Malvankar-Mehta. 2020. "Dry Eye after Refractive Surgery: A Meta-Analysis." *Canadian Journal of Ophthalmology* 55(2). doi: 10.1016/j.cjco.2019.07.005.
- Sambursky, Robert, and Terrence P. O'Brien. 2011. "MMP-9 and the Perioperative Management of LASIK Surgery." *Current Opinion in Ophthalmology* 22(4). doi: 10.1097/ICU.0b013e32834787bb.
- Sánchez, M. A., P. Arriola-Villalobos, P. Torralbo-Jiménez, N. Girón, B. de la Heras, R. Herrero Vanrell, A. Álvarez-Barrientos, and J. M. Benítez-del-Castillo. 2010. "The Effect of Preservative-Free HP-Guar on Dry Eye after Phacoemulsification: A Flow Cytometric Study." *Eye* 24(8). doi: 10.1038/eye.2010.24.
- Schmidl, Doreen, Leopold Schmetterer, Katarzyna J. Witkowska, Angelika Unterhuber, Valentin Aranha dos Santos, Semira Kaya, Johannes Nepp, Carina Baar, Peter Rosner, René M. Werkmeister, and Gerhard Garhofer. 2015. Tear Film Thickness After Treatment With Artificial Tears in Patients With Moderate Dry Eye Disease.
- Schuster, Alexander K., Carl Erb, Esther M. Hoffmann, Thomas Dietlein, and Norbert Pfeiffer. 2020. "The Diagnosis and Treatment of Glaucoma." *Deutsches Ärzteblatt International*. doi: 10.3238/arztebl.2020.0225.
- Seddon, Johanna, Donald Fong, Sheila K. West, and Charles T. Valmadrid. 1995. "Epidemiology of Risk Factors for Age-Related Cataract." *Survey of Ophthalmology* 39(4):323–34. doi: 10.1016/S0039-6257(05)80110-9.
- Sen, Emine, Ufuk Elgin, Osman Ozen, and Fikriye Gozde Ozturk. 2021. "The Efficacy and Safety of Trehalose in Primary Trabeculectomy with Mitomycin C: A Report of Early Findings." *Clinical Ophthalmology Volume* 15. doi: 10.2147/OPHTH.S311524.
- Shaheen, Mohamed Shafik, Amir AbouSamra, Hany Ahmed Helaly, Amr Said, and Ahmed Elmassry. 2020. "Comparison between Refractive Outcomes of Femtosecond Laser-Assisted Cataract Surgery and Standard Phacoemulsification." *BMC Ophthalmology* 20(1). doi: 10.1186/s12886-019-1277-9.
- Shao, Chunyi, Yao Fu, Linna Lu, Junzhao Chen, Qin Shen, Huimin Zhu, and Xianqun Fan. 2014. "Dynamic Changes of Tear Fluid after Cosmetic Transcutaneous Lower Blepharoplasty Measured by Optical Coherence Tomography." *American Journal of Ophthalmology* 158(1). doi: 10.1016/j.ajo.2014.03.016.
- Shao, Dewang, Xiaquan Zhu, Wei Sun, Peng Cheng, Wei Chen, and Hua Wang. 2018. "Effects of Femtosecond Laser-assisted Cataract Surgery on Dry Eye." *Experimental and Therapeutic Medicine*. doi: 10.3892/etm.2018.6862.

- She, Yujing, Jinyang Li, Bing Xiao, Huihui Lu, Haixia Liu, Peter A. Simmons, Joseph G. Vehige, and Wei Chen. 2015. "Evaluation of a Novel Artificial Tear in the Prevention and Treatment of Dry Eye in an Animal Model." *Journal of Ocular Pharmacology and Therapeutics* 31(9):525–30. doi: 10.1089/jop.2015.0042.
- Shen, Zeren, Yanan Zhu, Xiaohui Song, Jie Yan, and Ke Yao. 2016. "Dry Eye after Small Incision Lenticule Extraction (SMILE) versus Femtosecond Laser-Assisted in Situ Keratomileusis (FS-LASIK) for Myopia: A Meta-Analysis." *PLOS ONE* 11(12). doi: 10.1371/journal.pone.0168081.
- Shentu, Xingchao, Xin Zhang, Xiajing Tang, and Xiaoning Yu. 2016. "Coaxial Microincision Cataract Surgery versus Standard Coaxial Small-Incision Cataract Surgery: A Meta-Analysis of Randomized Controlled Trials." *PLOS ONE* 11(1). doi: 10.1371/journal.pone.0146676.
- Sherwood, Mark B., Ian Grierson, Lynn Milgar, and Roger A. Hitchings. 1989. "Long-Term Morphologic Effects of Antiglaucoma Drugs on the Conjunctiva and Tenon's Capsule in Glaucomatous Patients." *Ophthalmology* 96(3). doi: 10.1016/S0161-6420(89)32888-0.
- Shtein, Roni M. 2011. "Post-LASIK Dry Eye." *Expert Review of Ophthalmology* 6(5). doi: 10.1586/eop.11.56.
- Simmons, Peter A., Haixia Liu, Cindy Carlisle-Wilcox, and Joseph G. Vehige. 2015. "Efficacy and Safety of Two New Formulations of Artificial Tears in Subjects with Dry Eye Disease: A 3-Month, Multicenter, Active-Controlled, Randomized Trial." *Clinical Ophthalmology* 9:665–75. doi: 10.2147/OPHTH.S78184.
- Sitompul, Ratna, Grace S. Sancoyo, Johan A. Hutauruk, and Tjahjono D. Gondhowiardjo. 2008. *Sensitivity Change in Cornea and Tear Layer Due to Incision Difference on Cataract Surgery with Either Manual Small-Incision Cataract Surgery or Phacoemulsification*. Vol. 27.
- Smith JA. 2007. "The Epidemiology of Dry Eye Disease: Report of the Epidemiology Subcommittee of the International Dry Eye Workshop (2007)." *The Ocular Surface* 5(2). doi: 10.1016/S1542-0124(12)70082-4.
- Song, Jong S. uk, Joon Y. oung Hyon, Doh Lee, Euisang Chung, Chulyoung Choi, Jeongbok Lee, and Hyo M. yung Kim. 2014. "Current Practice Pattern for Dry Eye Patients in South Korea: A Multicenter Study." *Korean Journal of Ophthalmology: KJO* 28(2):115–21. doi: 10.3341/kjo.2014.28.2.115.
- Souchier, M., N. Buron, P. O. Lafontaine, A. M. Bron, C. Baudouin, and C. Creuzot-Garcher. 2006. "Trefol Factor Family 1, MUC5AC and Human Leucocyte Antigen-DR Expression by Conjunctival Cells in Patients with Glaucoma Treated with Chronic Drugs: Could These Markers Predict the Success of Glaucoma Surgery?" *British Journal of Ophthalmology* 90(11). doi: 10.1136/bjo.2006.094912.
- Speaker, Mark G., Florence A. Milch, Mahendra K. Shah, William Eisner, and Barry N. Kreiswirth. 1991. "Role of External Bacterial Flora in the Pathogenesis of Acute Postoperative Endophthalmitis." *Ophthalmology* 98(5). doi: 10.1016/S0161-6420(91)32239-5.
- Stapleton, Fiona, Monica Alves, Vatinee Y. Bunya, Isabelle Jalbert, Kaevalin Lekhanont, Florence Malet, Kyung-Sun Na, Debra Schaumberg, Miki Uchino, Jelle Vehof, Eloy Viso, Susan Vitale, and Lyndon Jones. 2017. "TFOS DEWS II Epidemiology Report." *The Ocular Surface* 15(3). doi: 10.1016/j.jtos.2017.05.003.
- Starr, Christopher E., Preeya K. Gupta, Marjan Farid, Kenneth A. Beckman, Clara C. Chan, Elizabeth Yeu, José A. P. Gomes, Brandon D. Ayers, John P. Berdahl, Edward J. Holland, Terry Kim, and Francis S. Mah. 2019a. "An Algorithm for the Preoperative Diagnosis and Treatment of Ocular Surface Disorders." *Journal of Cataract and Refractive Surgery* 45(5). doi: 10.1016/j.jcrs.2019.03.023.
- Starr, Christopher E., Preeya K. Gupta, Marjan Farid, Kenneth A. Beckman, Clara C. Chan, Elizabeth Yeu, José A. P. Gomes, Brandon D. Ayers, John P. Berdahl, Edward J. Holland, Terry Kim, and Francis S. Mah. 2019b. "An Algorithm for the Preoperative Diagnosis and Treatment of Ocular Surface Disorders." *Journal of Cataract and Refractive Surgery* 45(5). doi: 10.1016/j.jcrs.2019.03.023.
- Stephenson Michelle. 2007. "The Relationship Between Dry Eye and Cataract Surgery." <https://www.reviewofophthalmology.com/article/the-relationship-between-dry-eye-and-cataract-surgery>, November 21.
- Thakker, M. M., Tarbet, K. J., & Sires, B. S. (2005). Postoperative Chemosis After Cosmetic Eyelid Surgery. *Archives of Facial Plastic Surgery*, 7(3), 185–188. <https://doi.org/10.1001/archfaci.7.3.185>
- Thompson, Jay, and Naheed Lakhani. 2015. "Cataracts." *Primary Care: Clinics in Office Practice* 42(3):409–23. doi: 10.1016/j.pop.2015.05.012.
- Toda, Ikuko. 2002. "Laser-Assisted In Situ Keratomileusis for Patients With Dry Eye." *Archives of Ophthalmology* 120(8). doi: 10.1001/archophth.120.8.1024.
- Toda, Ikuko. 2018. "Dry Eye after Lasik." *Investigative Ophthalmology and Visual Science* 59(14 Special Issue):DES109–15. doi: 10.1167/iovs.17-23538.
- Toda, Ikuko, Takeshi Ide, Teruki Fukumoto, Yoshiyuki Ichihashi, and Kazuo Tsubota. 2014. "Combination Therapy With Diquafosol Tetrasodium and Sodium Hyaluronate in Patients With Dry Eye After Laser In Situ Keratomileusis." *American Journal of Ophthalmology* 157(3). doi: 10.1016/j.ajo.2013.11.017.
- Tong, Louis, Roger Beuerman, Susan Simonyi, David A. Hollander, and Michael E. Stern. 2016. "Effects of Punctal Occlusion on Clinical Signs and Symptoms and on Tear Cytokine Levels in Patients with Dry Eye." *The Ocular Surface* 14(2). doi: 10.1016/j.jtos.2015.12.004.
- Tong, Louis, Yang Zhao, and Ryan Lee. 2013. "Corneal Refractive Surgery-Related Dry Eye: Risk Factors and Management." *Expert Review of Ophthalmology* 8(6):561–75.
- Trattler, William B., Parag A. Majmudar, Eric D. Donnenfeld, Marguerite McDonald, Karl C. Stonecipher, and Damien Goldberg. 2017. "The Prospective Health Assessment of Cataract Patients' Ocular Surface (PHACO) Study: The Effect of Dry Eye." *Clinical Ophthalmology Volume 11*. doi: 10.2147/OPHTH.S120159.
- Vaede, D., C. Baudouin, J. M. Warnet, and F. Brignole-Baudouin. 2010. "Les Conservateurs Des Collyres : Vers Une Prise de Conscience de Leur Toxicité." *Journal Français d'Ophtalmologie* 33(7). doi: 10.1016/j.jfo.2010.06.018.
- Versura, Piera, Giuseppe Giannaccare, Marco Pellegrini, Stefano Sebastiani, and Emilio C. Campos. 2018. "Neurotrophic Keratitis: Current Challenges and Future Prospects." *Eye and Brain Volume 10*:37–45. doi: 10.2147/EB.S117261.
- Waibel, Soeren, Eberhard Spoerl, Olga Furashova, Lutz E. Pillunat, and Karin R. Pillunat. 2019. "Bleb Morphology After Mitomycin-C Augmented Trabeculectomy." *Journal of Glaucoma* 28(5):447–51. doi: 10.1097/IJG.0000000000001206.

- Wallerstein, Avi, W. Bruce Jackson, Jeffrey Chambers, Amir M. Moezzi, Hugh Lin, and Peter A. Simmons. 2018. "Management of Post-LASIK Dry Eye: A Multicenter Randomized Comparison of a New Multi-Ingredient Artificial Tear to Carboxymethylcellulose." *Clinical Ophthalmology* Volume 12. doi: 10.2147/OPTH.S163744.
- Weinreb, Robert N., Tin Aung, and Felipe A. Medeiros. 2014a. "The Pathophysiology and Treatment of Glaucoma." *JAMA* 311(18). doi: 10.1001/jama.2014.3192.
- Weinreb, Robert N., Tin Aung, and Felipe A. Medeiros. 2014b. "The Pathophysiology and Treatment of Glaucoma: A Review." *JAMA - Journal of the American Medical Association* 311(18):1901–11.
- Wolffsohn, James S., Reiko Arita, Robin Chalmers, Ali Djalilian, Murat Dogru, Kathy Dumbleton, Preeya K. Gupta, Paul Karpecki, Sihem Lazreg, Heiko Pult, Benjamin D. Sullivan, Alan Tomlinson, Louis Tong, Edoardo Villani, Kyung Chul Yoon, Lyndon Jones, and Jennifer P. Craig. 2017. "TFOS DEWS II Diagnostic Methodology Report." *Ocular Surface* 15(3):539–74.
- Woods, Jill, Jalaiah Varikooty, Desmond Fonn, and Lyndon W. Jones. 2018. "A Novel Scale for Describing Corneal Staining." *Clinical Ophthalmology* 12:2369–75. doi: 10.2147/OPTH.S178113.
- Xue, Wenwen, Ming-ming Zhu, Bi-jun Zhu, Jian-nan Huang, Qian Sun, Yu-yu Miao, and Hai-dong Zou. 2019. "Long-Term Impact of Dry Eye Symptoms on Vision-Related Quality of Life after Phacoemulsification Surgery." *International Ophthalmology* 39(2). doi: 10.1007/s10792-018-0828-z.
- Yan, Yan, Yixiong Zhou, Siyi Zhang, Chang Cui, Xuefei Song, Xiangyang Zhu, and Yao Fu. 2020. "Impact of Full-Incision Double-Eyelid Blepharoplasty on Tear Film Dynamics and Dry Eye Symptoms in Young Asian Females." *Aesthetic Plastic Surgery* 44(6). doi: 10.1007/s00266-020-01874-0.
- Yang, Patrick, Audrey C. Ko, Don O. Kikkawa, and Bobby S. Korn. 2017. "Upper Eyelid Blepharoplasty: Evaluation, Treatment, and Complication Minimization." *Seminars in Plastic Surgery* 31(1). doi: 10.1055/s-0037-1598628.
- Yao, Ke, Yongzhen Bao, Jian Ye, Yi Lu, Hongsheng Bi, Xin Tang, Yune Zhao, Jinsong Zhang, and Jinling Yang. 2015. "Efficacy of 1% Carboxymethylcellulose Sodium for Treating Dry Eye after Phacoemulsification: Results from a Multicenter, Open-Label, Randomized, Controlled Study." *BMC Ophthalmology* 15(1). doi: 10.1186/s12886-015-0005-3.
- Yazdani, Mazyar, Katja Benedikte Prestø Elgstøen, Helge Rootwelt, Aboulghassem Shahdadfar, Øygunn Aass Utheim, and Tor Paaske Utheim. 2019. "Tear Metabolomics in Dry Eye Disease: A Review." *International Journal of Molecular Sciences* 20(15).
- Yu, Edward Y. W., Alfred Leung, Srinivas Rao, and Dennis S. C. Lam. 2000. "Effect of Laser in Situ Keratomileusis on Tear Stability." *Ophthalmology* 107(12). doi: 10.1016/S0161-6420(00)00388-2.
- Yu, Yinhui, Huixia Hua, Menghan Wu, Yibo Yu, Wangshu Yu, Kairan Lai, and Ke Yao. 2015. "Evaluation of Dry Eye after Femtosecond Laser-Assisted Cataract Surgery." *Journal of Cataract and Refractive Surgery* 41(12). doi: 10.1016/j.jcrs.2015.06.036.
- Yung, Yang Hao, Ikuko Toda, Chikako Sakai, Atsushi Yoshida, and Kazuo Tsubota. 2012. "Punctal Plugs for Treatment of Post-LASIK Dry Eye." *Japanese Journal of Ophthalmology* 56(3). doi: 10.1007/s10384-012-0125-8.
- Yusufu, Maierhaba, Xin Liu, Tianyu Zheng, Fan Fan, Jianjiang Xu, and Yi Luo. 2018. "Hydroxypropyl Methylcellulose 2% for Dry Eye Prevention during Phacoemulsification in Senile and Diabetic Patients." *International Ophthalmology* 38(3). doi: 10.1007/s10792-017-0590-7.
- Zeev, Maya Salomon-Ben, Darby Douglas Miller, and Robert Latkany. 2014. "Diagnosis of Dry Eye Disease and Emerging Technologies." *Clinical Ophthalmology (Auckland, N.Z.)* 8. doi: 10.2147/OPTH.S45444.
- Zhang, Si Yi, Yan Yan, and Yao Fu. 2020. "Cosmetic Blepharoplasty and Dry Eye Disease: A Review of the Incidence, Clinical Manifestations, Mechanisms and Prevention." *International Journal of Ophthalmology* 13(3):488–92.



Théa

Laboratoires Théa
12 Rue Louis Blériot - ZI du Brézet
63017 Clermont-Ferrand cedex 2 - France
Tel. : +33 473 98 14 36 - Fax : +33 473 98 14 38
www.laboratoires-thea.com



Collection Librairie Médicale Théa



Laboratoires Théa
12 Rue Louis Blériot - ZI du Brézet
63017 Clermont-Ferrand cedex 2 - France
Tél. +33 (0)4 73 98 14 36 - Fax +33 (0)4 73 98 14 38
www.laboratoires-thea.com