

GLAUCOMA STORIES

Professor **Florent APTEL**

Professor **Jean-François ROULAND**



GLAUCOMA STORIES

Professor **Florent APTEL**

Professor **Jean-François ROULAND**



EDITION:

Edited by:

Laboratoires Théa
12, rue Louis Blériot
63000 Clermont-Ferrand
Tel: +33 4 73 981 436



Dear Readers,

The content of this book presents the point of view of the authors and does not necessarily reflect the opinion of Thea Laboratories.

All rights to reproduce, translate, and adapt in any shape or form are reserved for all countries.

All reproduction or representation in whole or in part, in any shape or form whatsoever, of the pages published in this work, made without the prior written consent of the publisher is illegal and prohibited and constitutes an infringement. Only the following are permitted: 1) reproduction which is strictly for the purpose of the private use of the person making the copy and not intended for collective use, and 2) brief reviews and citations justified by the scientific or pedagogical purpose of the work in which they are incorporated (Articles 40 and 41, Law of 11 March 1957 and Art. 425 of the Penal Code).

Preface

Once upon a time.....

Until recently, there was a common condition potentially causing blindness. Sometimes, however, it remains unrecognised or diagnosed at a late stage, despite the wide range of effective treatments available to slow down its progression and prevent the loss of vision.

Primary open-angle glaucoma is the most common form, but there are many other forms of open-angle or angle-closure glaucoma, without any particular aetiologic factors that are called primary, or secondary to ocular or systemic abnormalities. These different forms of glaucoma often have their own particular symptoms, clinical presentation, pattern of progression and diagnostic strategies and management.

This book presents illustrated case histories of twenty primary and secondary forms of glaucoma, each with a brief referenced assessment. We have selected them for their typical features, noteworthy imaging characteristics or pedagogical value invoking clinical presentation, diagnostic tests, follow-up and management procedures. Our aim in writing this book is to help you manage these different forms of glaucoma, by adopting an approach similar to the one we use with our patients.

We wish to thank Théa Laboratories for their assistance from creation to publication of this book. This book will enrich the collection of literature on ophthalmology and glaucoma much appreciated by French-speaking health care providers who actively participate in the training of our young colleagues.

Happy reading!

Professor Florent APTEL
(Michallon Hospital,
Grenobles-Alpes University Hospital)

Professor Jean-François ROULAND
(Claude Huriez Hospital, Lille
Regional University Hospital)

Table of Contents

1. Deep anterior chamber, yes indeed!	9
2. The sooner the better	23
3. Young people under pressure	41
4. More than just glaucoma	53
5. Indented iris	67
6. Details are in the angle	75
7. A specific etiology	87
8. Not a good mix	101
9. Head upside down	111
10. Myopia or glaucoma	123
11. Glaucoma as the final blow	133
12. Frozen eye	143
13. Did you say normal?	155
14. Rare but intelligent	169
15. An ice storm	179
16. Trivial	195
17. So young	207



1

Deep anterior chamber...
yes indeed!

Case report

Mrs. B, 41 year old was referred by a physician colleague for bilateral ocular hypertension, associated with the presence of anterior synechiae revealed upon gonioscopic examination. In his mail, he writes that he suspects a primary bilateral angle closure glaucoma, but is surprised by the significant deepness of the anterior chamber.

Mrs. B had history of asthma, which appeared a few year before. She was treated with inhaled corticosteroids when symptoms appeared.

On examination visual acuity is 20/40 in the right eye and 20/20 in the left eye with a correction of -2.50 diopters in both eyes. Intraocular pressure without treatment is 32 mmHg on the right and 18 mmHg on the left without treatment.

The gonioscopic examination reveals numerous peripheral anterior synechiae on the right and only a few on the left with deep anterior chambers in the center (Figure 1).

Multiple choice question

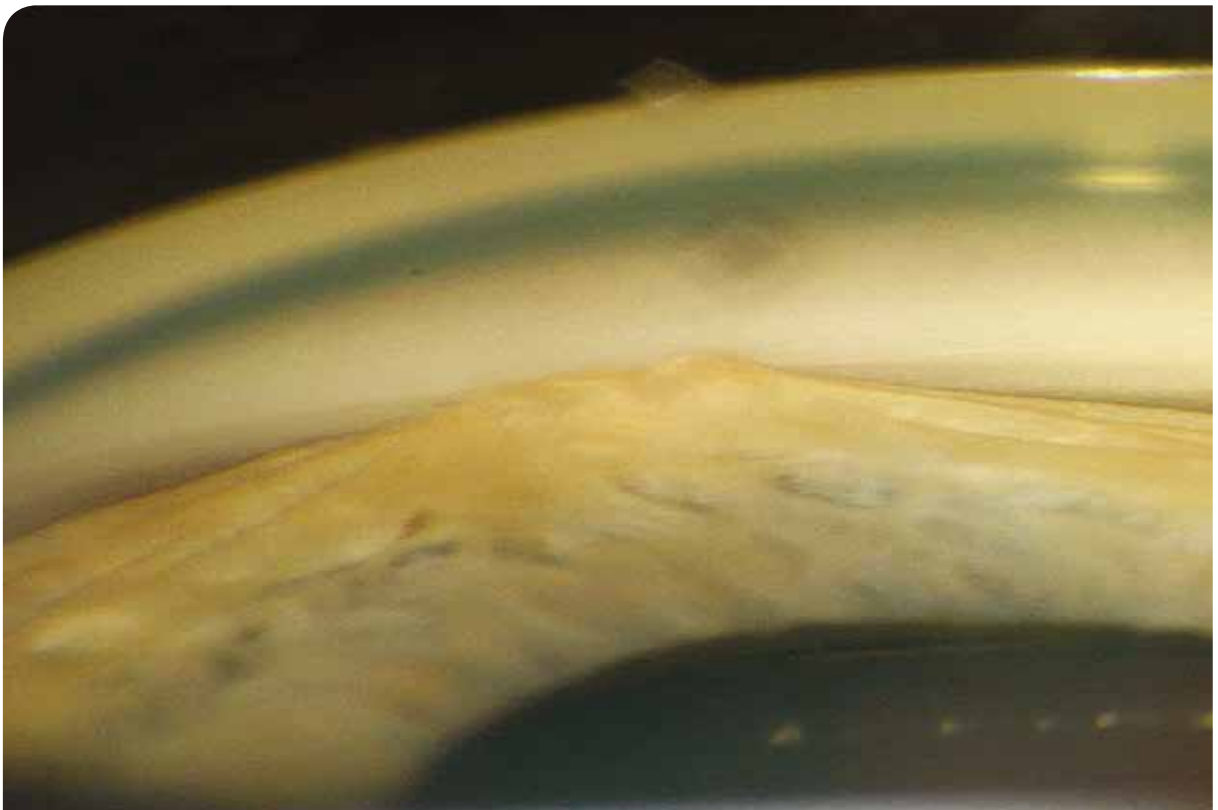


Figure 1: Peripheral anterior synechiae of the right eye.

What condition can explain the presence of anterior synechiae in this patient (one correct answer)

- A. Primary angle-closure glaucoma
- B. Chronic anterior uveitis
- C. Neovascular glaucoma
- D. Pupillary seclusion
- E. Plateau iris syndrome

Answer to the MCQ on page 21

Complete case report and answer to the question

On examination visual acuity is 20/40 in the right and 20/20 in the left eye with a correction of -2.50 diopters in both eyes.

Intraocular pressure without treatment is 32 mmHg on the right and 18 mmHg on the left without treatment.

The examination of the anterior segment reveals the presence of some bilateral granulomatous retro-descemetometric precipitates. The anterior chambers are quiet and deep. Numerous irido-crystalline synechiae are present on the right and very minimal on the left (Figure 2).

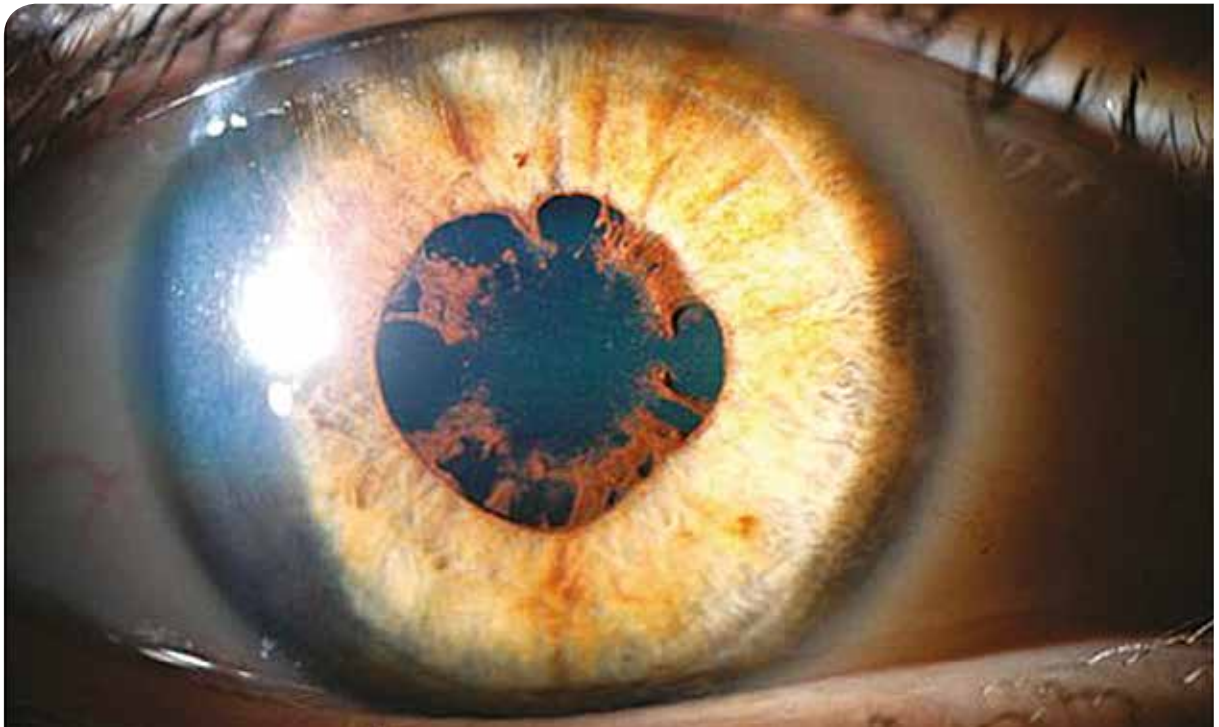

Figure 2: Numerous irido-crystalline synechiae.

A highly magnified examination shows the presence of nodules on the iris margin (Koepple nodules) and on the iris stroma (Busacca nodules) (Figures 3 and 4).

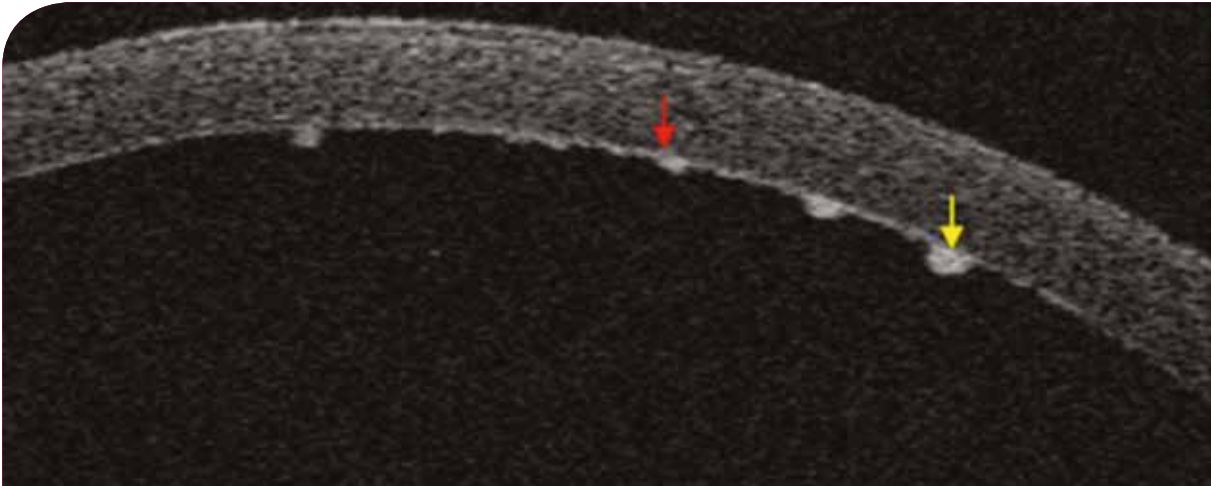


Figure 3: Iris nodules.

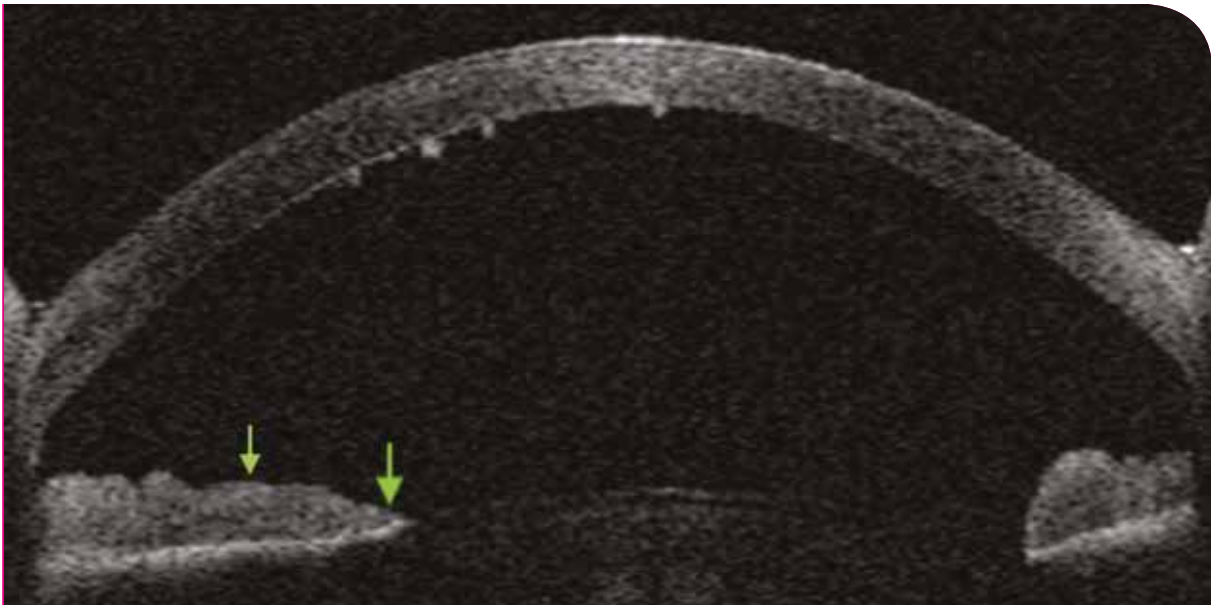


Figure 4: Retro-descemetes precipitates in OCT.

The gonioscopic examination reveals fairly extended peripheral anterior synechiae, numerous on the right and few on the left.

These synechiae exceed the anterior limit of the trabecular meshwork, concealing half of the its circumference on the right (Figure 5).

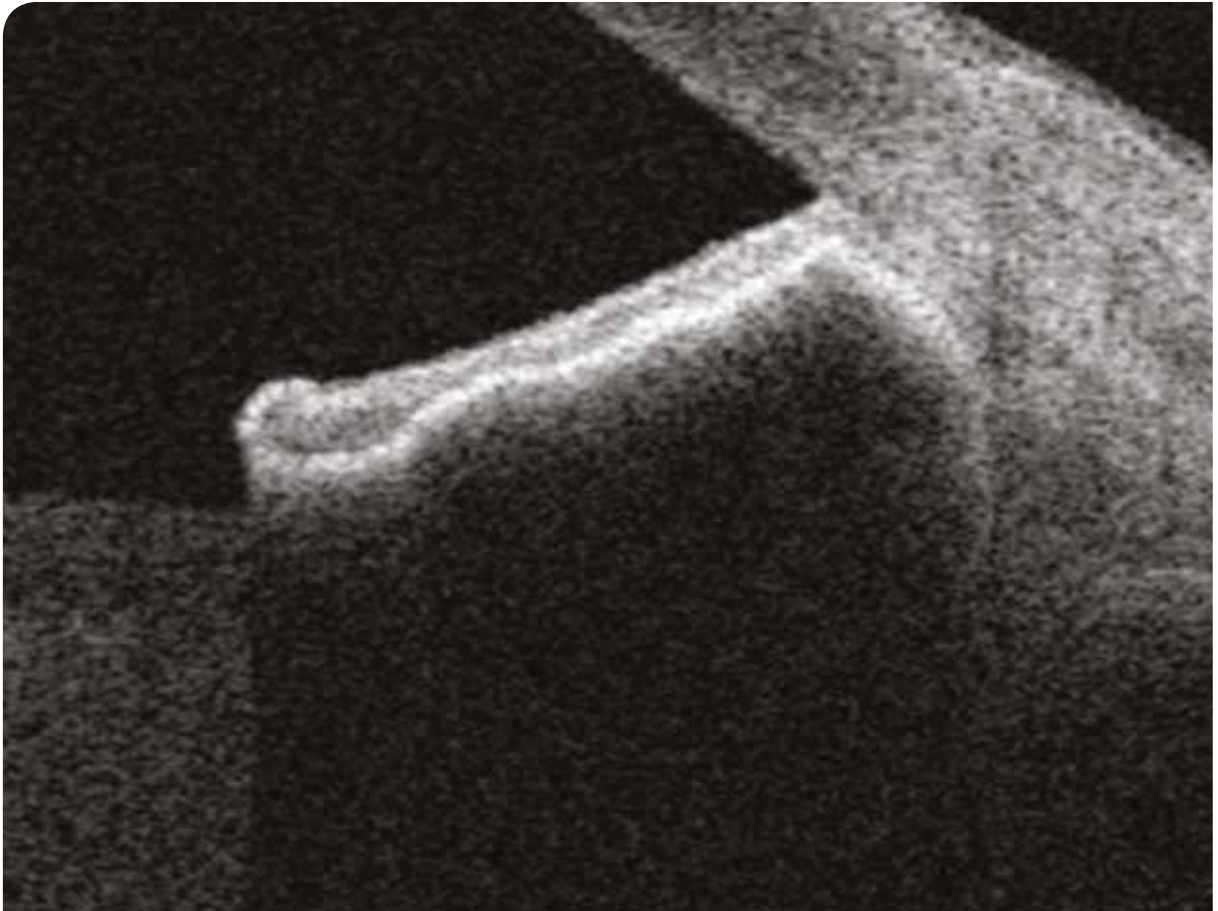


Figure 5: Cross-section of a peripheral anterior synechia.

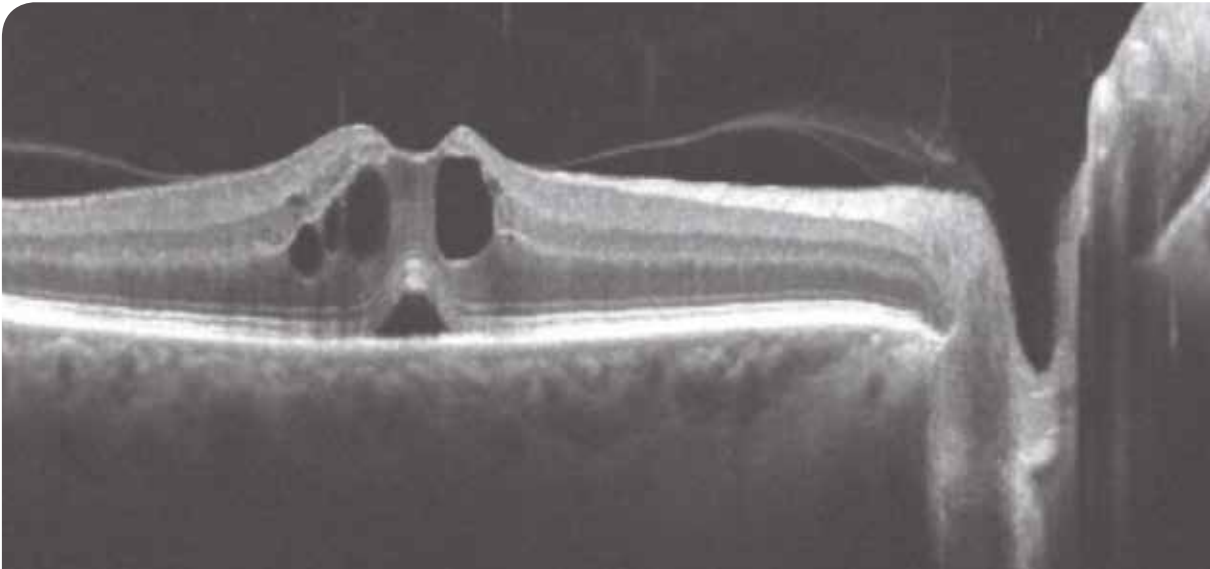


Figure 6: Right macular edema.

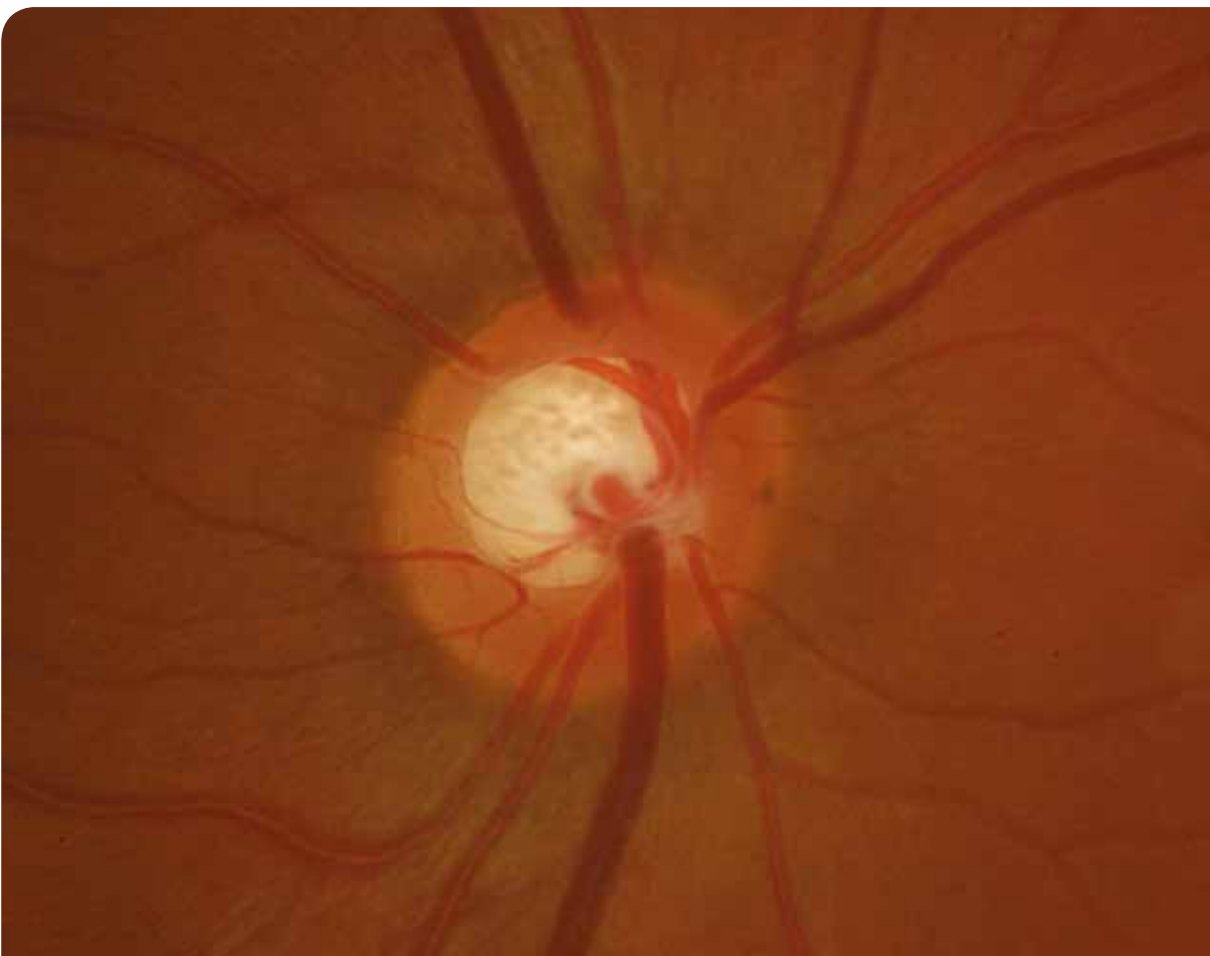

Figure 7 : Non-excavated right disc.

The fundus examination shows a vitritis not concealing the details of the retina on the right (1+) and clear vitreous on the left.

The discs do not appear excavated with a vertical cup/disc ratio of 0.5 and a normal neuroretina rim following the ISNT rule.

There appears to be a macular edema on the right, which will be confirmed by the OCT (central macular thickness of 420 μm in the right eye and 255 μm in the left eye). (Figures 6 and 7).

OCT of optic disc is within normal limits and standard SITA 24-2 white-on-white visual field testing normal.

A granulomatous uveitis work up is performed, in particular of infectious serologies (HIV, syphilis), an intradermal tuberculin reaction test, an analysis of serum lysozyme and angiotensin converting enzyme and a chest scan.

The laboratory exam showed an increase in calcium serum levels, serum lysozyme and plasma angiotensin converting enzyme. The intradermal tuberculin reaction was negative. The chest scan noted the presence of numerous mediastinal adenopathies, infiltrates and interstitial pulmonary micronodules and suggested sarcoidosis (stage 2).

An additional exam performed by an internist (respiratory functional exploration, bronchial fibroscopy with broncho-alveolar lavage and bronchial spur biopsy) confirmed the diagnosis of sarcoidosis (lymphocyte alveolitis CD4+ at lavage and presence of giant cell and epithelioid granulomas without caseous necrosis in the biopsy).

A topical treatment with carbonic anhydrase inhibitor + beta-blocker fixed-combination was initiated on the right eye enabling normalization of intraocular pressure. The intravitreal injection of an implant of prolonged-release corticosteroids was discussed for the right eye (macular edema).

Due to the recent increase of IOP and frequent breathing difficulty, oral corticotherapy was preferred, which enabled a complete regression of the macular edema and functional respiratory signs after several months.

Overview of the topic discussed in the case

1. What are the mechanisms of an increase in intraocular pressure during uveitis?

The mechanisms that can lead to an increase in intraocular pressure in case of uveitis are numerous and sometimes intricately linked in the same patient (1-5). The gonioscopic examination is fundamental to identify the mechanism(s) and guide therapeutic management.

When the iridocorneal angle is open, the following may occur:

- An increase of aqueous secretion, for example in the context of Posner-Schlossman syndrome (recurrent episodes of severe unilateral hypertension, typical in young patients, often with few symptoms and with few signs of inflammation upon clinical examination).
- An inflammation of the trabecular meshwork causing a decrease in its permeability to aqueous humor (example of viral uveitis, herpes family virus).
- An obstruction of the trabecular meshwork by inflammatory cells or by a hyphema (significant inflammation with hypopyon, spontaneous bleeding or after puncture of the anterior chamber).
- A steroid-induced hypertension, a common mechanism invoked when hypertonia appears secondary to or does not regress when the inflammation decreases, proportionally to the dose and the duration of the anti-inflammatory treatment, and more often following local rather than systemic administration of corticosteroids (topical, subconjunctival, subtenonian, intravitreal).

When the iridocorneal angle is closed or synechiated:

- A significant inflammation can cause the development of circumferential irido-crystalline synechiae (situation of pupillary seclusion), resulting in bulging of the iris forward due to the obstruction of aqueous humor flow and secondary iridocorneal angle-closure "tomato-like appearance".
- A significant and/or prolonged inflammation can also lead to the development of peripheral anterior synechiae - adhesion of the iris to the iridocorneal angle - forming an obstacle to the trabecular outflow of aqueous humor. These synechiae can form even when the anterior chamber is deep and the angle anatomically open. The risk of ocular hypertension is proportional to the extent of the synechiae (low when less of the circumference is affected, present when one-half to three-quarters of the circumference are affected, and very high for over three-quarters of the circumference).
- Some forms of uveitis, especially retinal vasculitis (Behçet's disease, etc.), can become complicated by a retinal neovascularization and/or of the anterior segment, with a situation of neovascular glaucoma and angle-closure by a shrinking neovascular membrane.
- Some forms of posterior uveitis (Vogt-Koyanagi-Harada disease) can be complicated by an uveal effusion leading to angle-closure by anterior rotation of the ciliary body. This situation is shown by an examination of the eye fundus or by ocular ultrasound and generally rapidly reversible after the systemic administration of corticotherapy.

2. Frequency and etiology of hypertensive uveitis

The onset of ocular hypertension is not rare in a subject with chronic inflammatory eye disease. Studies have estimated that 5% to 20% of acute or chronic uveitis cases become complicated by ocular hypertension⁽¹⁻²⁾.

The forms of uveitis often associated with ocular hypertension are^(4,5) :

- Infectious uveitis:
 - viral (herpes, CMV, VZV)
 - bacterial (BK, Syphilis)
 - toxoplasmosis
- Fuchs syndrome (rubella?)
- Posner-Schlossman syndrome (CMV?)
- Sarcoidosis
- Uveitis HLA B27+
- Chronic juvenile arthritis

3. Management of hypertensive uveitis

Treatment obviously depends on the mechanism of pressure increase⁽⁶⁾.

An aqueous hypersecretion, an inflammation of the trabecular meshwork or an obstruction of the trabecular meshwork by inflammatory material will be managed with a local or systemic inflammatory treatment.

On the other hand, a steroid-induced hypertension will require a rapid decrease of treatment with corticosteroids or replacement by other immunomodulatory therapy.

Medical treatment

The following therapeutic classes can be used without particular restraint: beta-blockers, carbonic anhydrase inhibitors and alpha-2 agonists.

Prostaglandin analogues must be avoided in cases of active inflammation (risk of cystoid macular edema, increase of inflammation). They can be used in cases of uveitis without active inflammation (extensive anterior synechiae, etc.) and are effective in cases of steroid-induced hypertension.

Laser trabeculoplasty

Selective laser trabeculoplasty (SLT) must be avoided in the case of active inflammation, is not effective in the event of extensive anterior synechiae or iridocorneal angle-closure, is possible in the case of uveitis without active inflammation and without anterior synechiae and is effective in the case of steroid-induced hypertension.

Argon laser trabeculoretraction (ALTR) may induce intraocular inflammation and must be avoided.

Surgical treatment

Filtration surgery is sometimes envisaged in the case of hypertension resistant to medical treatment.

It must be performed if possible after an inflammatory episode and hedged with prolonged anti-inflammatories treatment.

The risk of fibrosis is reduced by the preoperative use of antimetabolites (mitomycin C, 5-fluorouracil) that is quasi systematic.

In the absence of angular synechiae or in the case of steroid-induced hypertension, a deep sclerectomy can be performed. When the angle is closed, a trabeculectomy or the insertion of a drain such as Molteno, Ahmed, Baerveldt, are preferred.

Cyclocoagulation procedures

Diode laser cyclocoagulation can be used in the case of glaucoma resistant to other medical and surgical treatments.

The choice of parameters (potency and application time) must be safe.

In the short term, the risk of an inflammatory reaction and spikes of ocular hypertension are frequent.

In the medium and long term, the risk of chronic hypertension and phthisis is significant.

Specific treatments

Numerous treatments other than steroid and non-steroid anti-inflammatories can be used to control inflammation and avoid recurrence of inflammation, while reducing ocular and systematic side effects of the treatment (biotherapies, immunosuppressants).

In the case of infectious uveitis, an etiologic treatment is often possible (antiviral, antibiotic).

Lastly, steroid-induced hypertonia can be managed by the use of mild hypertonic corticosteroids (fluorometholone, rimexolone), sometimes by the lavage of crystalline triamcinolone deposits in the anterior chamber or the removal of a vitreous implant by means of vitrectomy.



References

1. Herbert HM, Viswanathan A, Jackson H, Lightman SL. Risk factors for elevated intraocular pressure in uveitis. *J Glaucoma*. 2004 Apr; 13(2): 96-9.
2. Merayo-Llodes J, Power WJ, Rodriguez A, Pedroza-Seres M, Foster CS. Secondary glaucoma in patients with uveitis. *Ophthalmologica*. 1999; 213(5): 300-4.
3. Lachkar Y, Brasnu E, Orignac I. Glaucome, hypertension et uvéites. Uvéites. Rapport SFO, 2010.
4. Moorthy RS, Mermoud A, Baerveldt G, Minckler DS, Lee PP, Rao NA. Glaucoma associated with uveitis. *Surv Ophthalmol*. 1997 Mar-Apr; 41(5): 361-94.
5. Kok H, Barton K. Uveitic glaucoma. *Ophthalmol Clin North Am*. 2002 Sep; 15 (3): 375-87.
6. Auer C, LeHoang P, Herbert CP, Mermoud A. Glaucoma Associated with Uveitis: Review on Its Appraisal, Management and New Surgical Prospects. *Comprehensive Ophthalmology Update* 2003; 5 (4): 203-10.

Answer to the MCQ on page 11: B



2

The sooner the better

Case report

Mr. A, 56-year-old, without known medical history, was referred by a colleague for an additional exam for isolated hypertension found during a routine eye examination. Refraction is as follows:

- Right: 20/20 with +1.5(-1.0)60° diopter
- Left: 20/20 with +1.00 diopter

Intraocular pressure measured with the Noncontact tonometer was 22 mmHg in the right eye and 20 mmHg in the left. The eye fundus is reported normal in both eyes.

The referring doctor included an OCT of the retinal fibers done during this consultation that he considered as being normal (Figure 1).

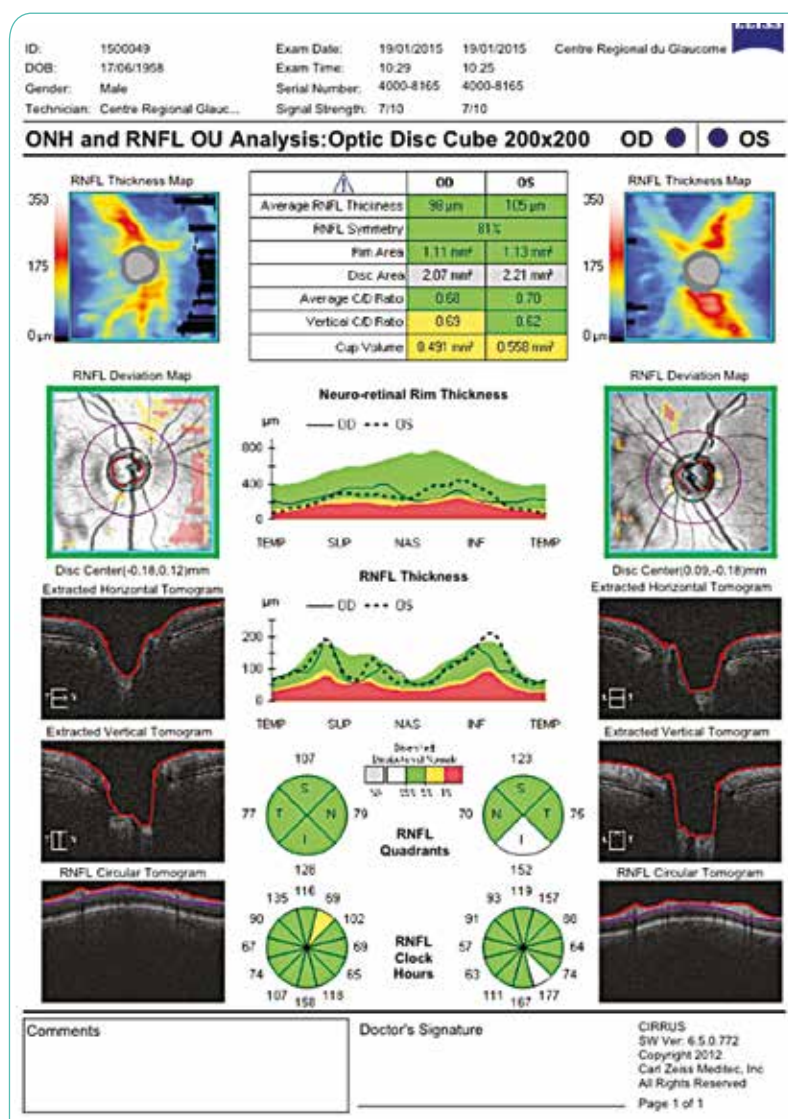


Figure 1: Cirrus OCT RNFL normal.

Multiple choice question

What is your attitude faced with this frequent request for a complementary exam? (one correct answer)

- A. There is no sense of urgency, you will schedule the exam in 8 months.
- B. Not enough clinical data but the OCT is normal. You will schedule it in 6 months.
- C. The OCT alone is not enough, but it is normal. You will call the patient in 3 months.
- D. Only one IOP measurement, no pachymetry test or gonioscopy, and oct artefacts seen on the right eye, so no time to waste. You decide to call the patient within the month.
- E. You wonder why this patient, with normal results, was even referred.

Answer to the MCQ on page 39

An examination is carried out in the month following the request.

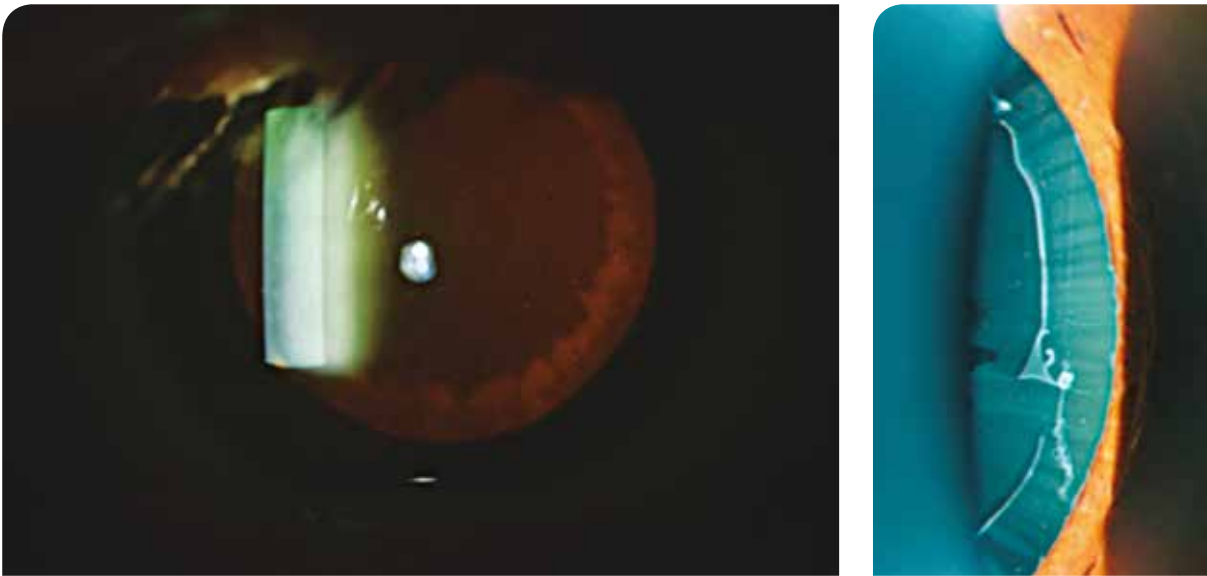
Visual acuity is indeed 20/20 with the prescribed correction.

IOP without treatment measured twice is 23 mmHg in the right and 20 mmHg in the left eye. Ultrasonic pachymetry measured in the right eye is 475 μm and 480 μm in the left eye.

The biomicroscopic exam (Figures 2, 3 and 4).

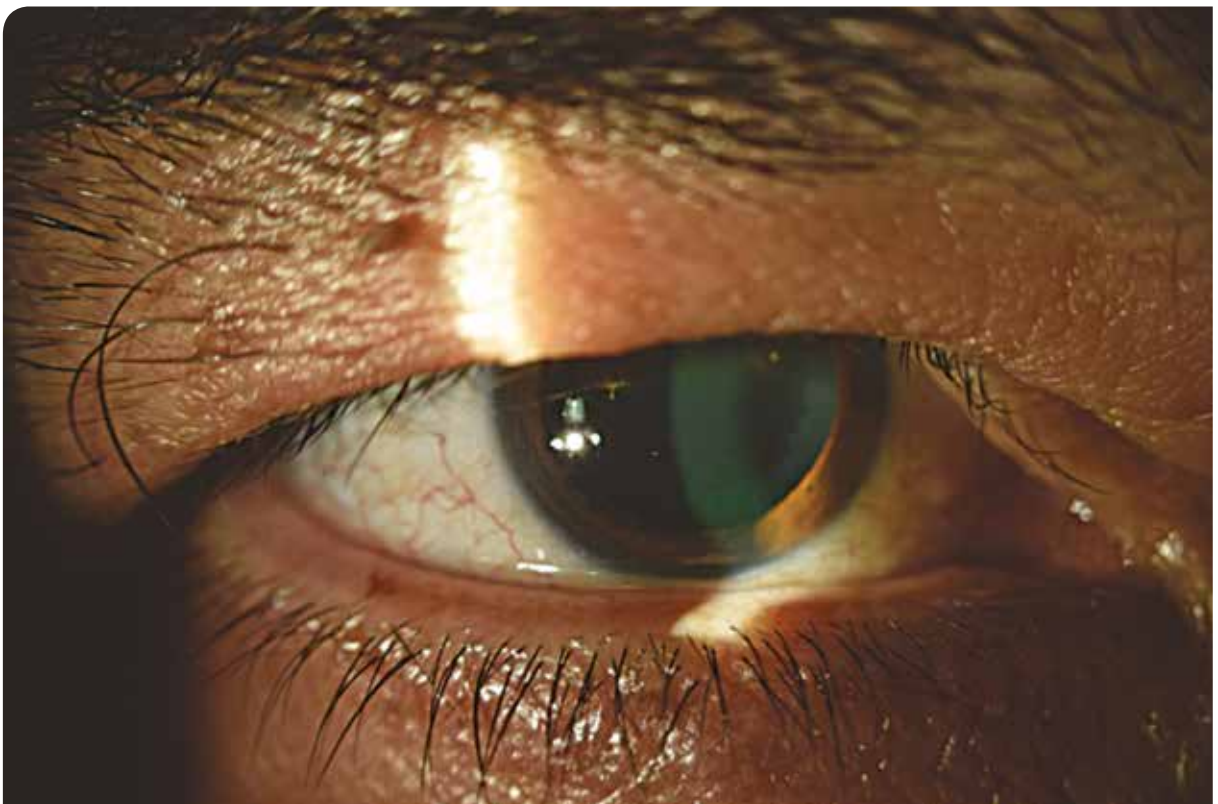

Figure 2: Small transparent membrane on the anterior crystalloid invoking pseudo-capsular exfoliation.



Figures 3 and 4: Confirmation of pseudo-capsular exfoliation.

Bilateral gonioscopy finds a Sampaolesi line and 4 elements visible on the four quadrants of both eyes (Figure 5).



Figure 5: Pigmented Sampaolesi line in an open angle.

Retinal photographs of the two optic discs need to be taken (Figures 6 and 7).

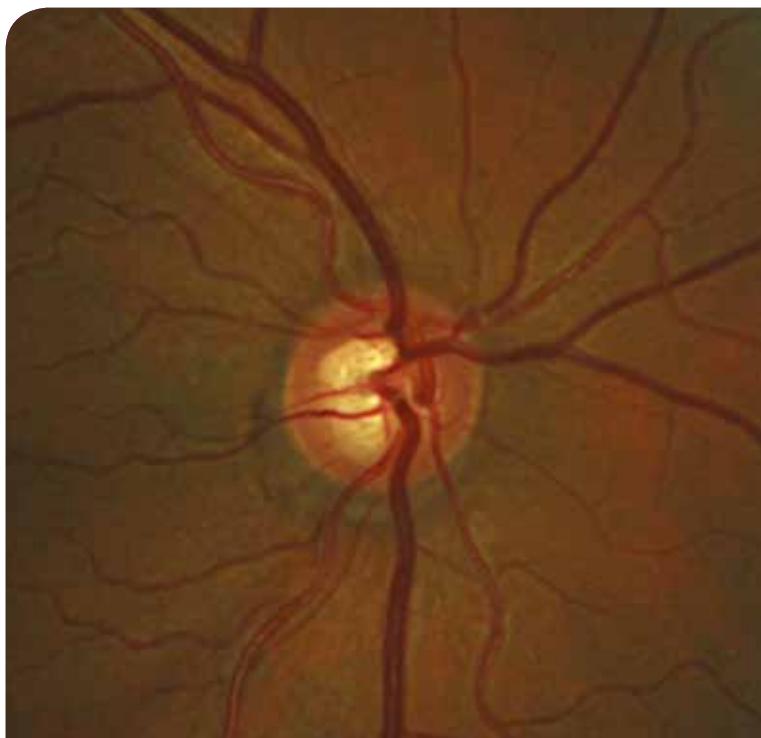

Figure 6: Right optic disc.

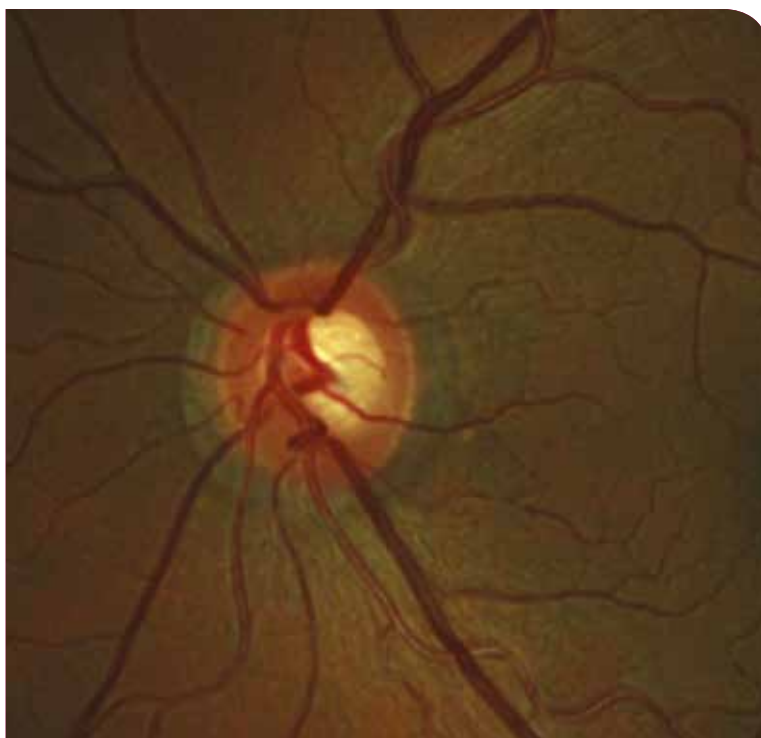


Figure 7: Left optic disc.

First standard measurement of visual field (Figures 8 and 9).




Figure 8: Right visual field.

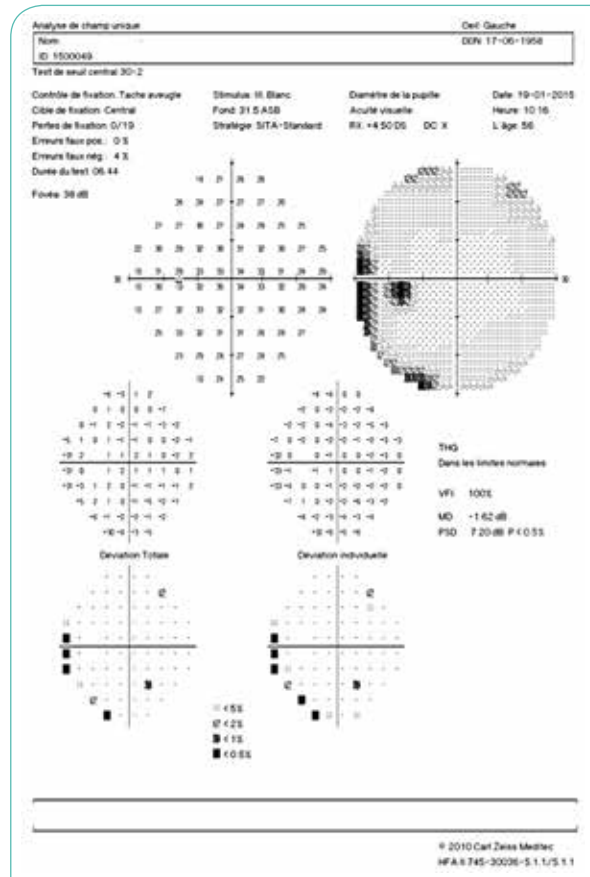


Figure 9: Left visual field.

As the first OCT RNFL presented artefacts on the right, further measurements need to be taken (Figure 10).

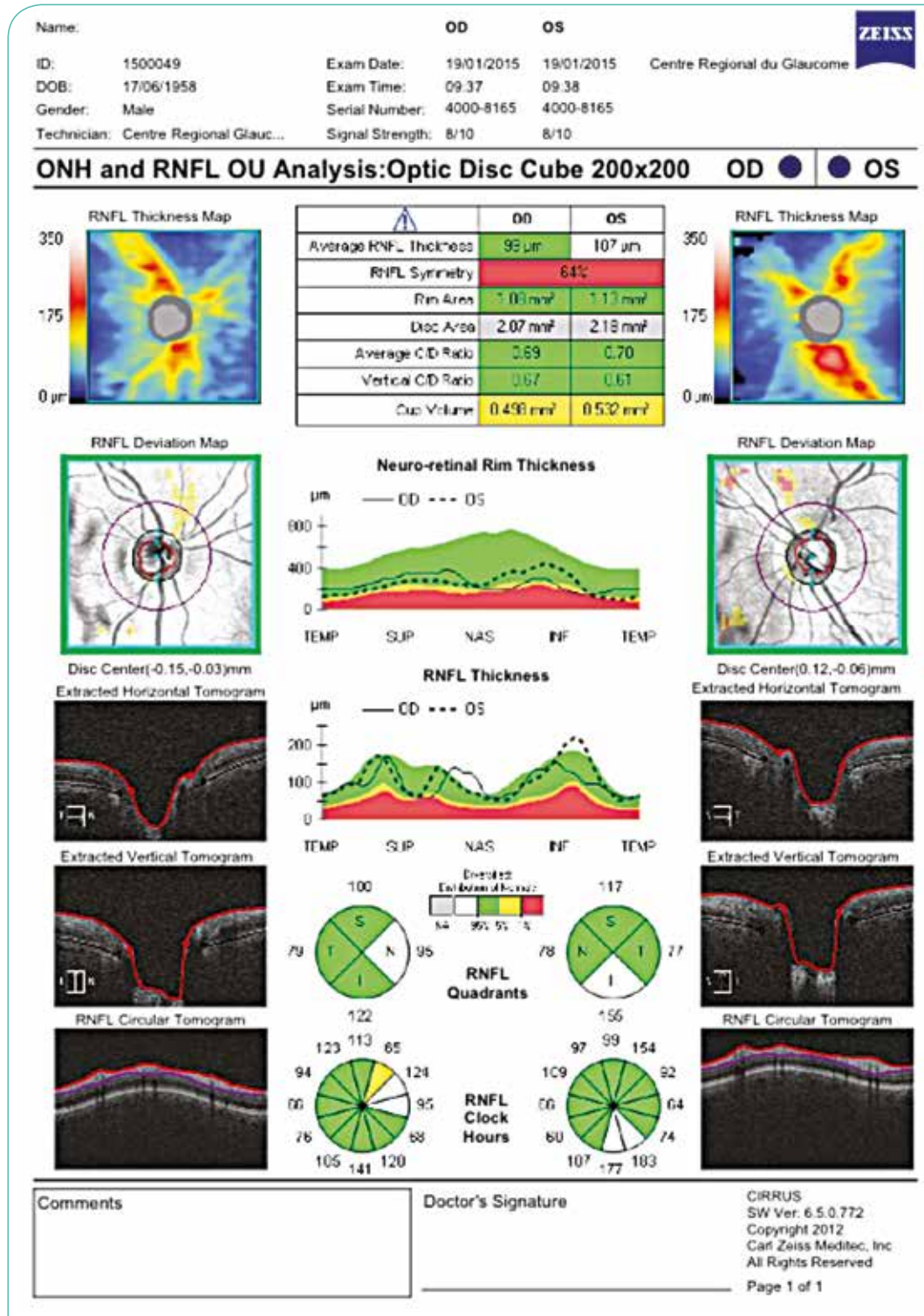


Figure 10: Cirrus OCT RNFL normal.

Multiple choice question

What do you suggest at this stage of the test? (three correct answers)

- A. The first visual fields do not present any characteristic defects of glaucoma.
- B. IOP is underestimated because of the thin corneal thickness.
- C. The optic discs are normal.
- D. OCT RNFL is normal.
- E. More data is needed before posing a diagnosis on this typical case of pseudo-capsular exfoliation.

Answer to the MCQ on page 39

To complete the examination, retinal photographs of the optic discs are re-assessed: right eye (Figures 11 and 12) and left eye (Figures 13 and 14).

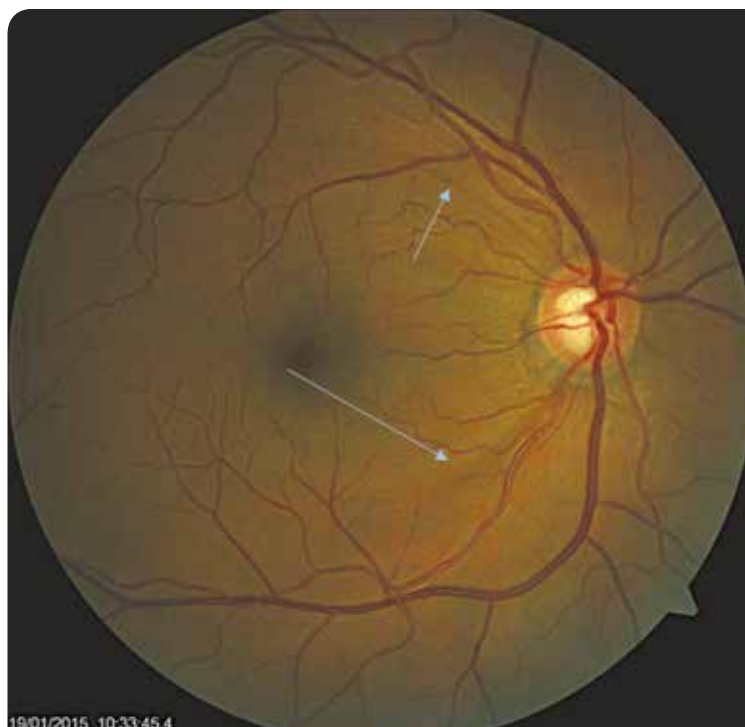

Figure 11: Axonal fibre defects below and above (arrows).

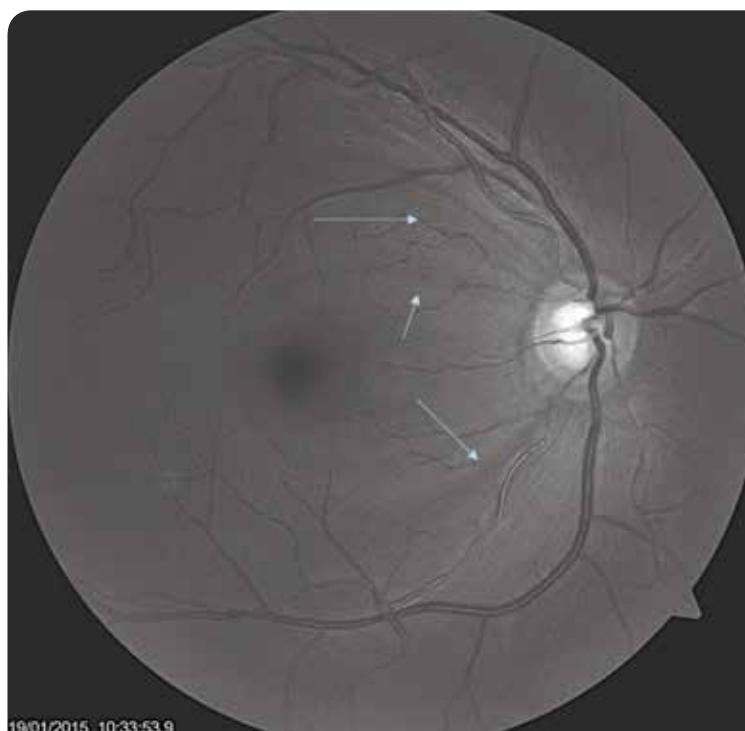

Figure 12: Picture with blue light: lower and upper axonal fibre defect (arrows).

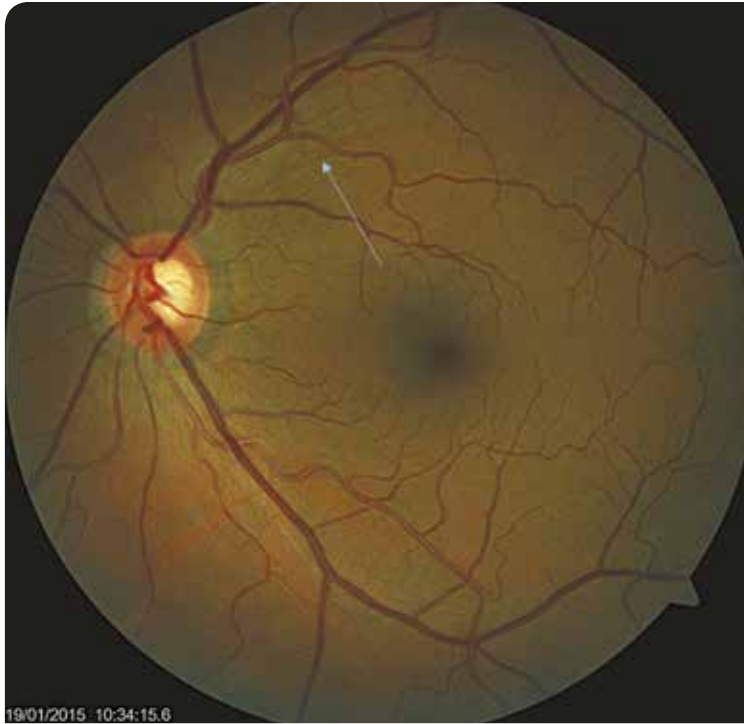

Figure 13: Small upper defect (arrow).

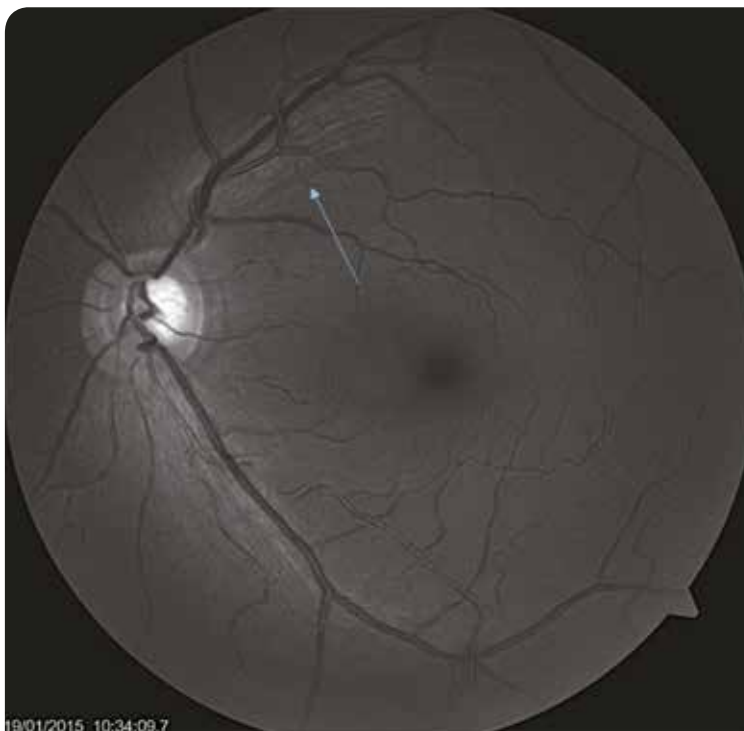

Figure 14: Picture with blue light: confirmation of upper fibre defect (arrow).

Finish with an exploration of the ganglion cell complex (Figure 15).

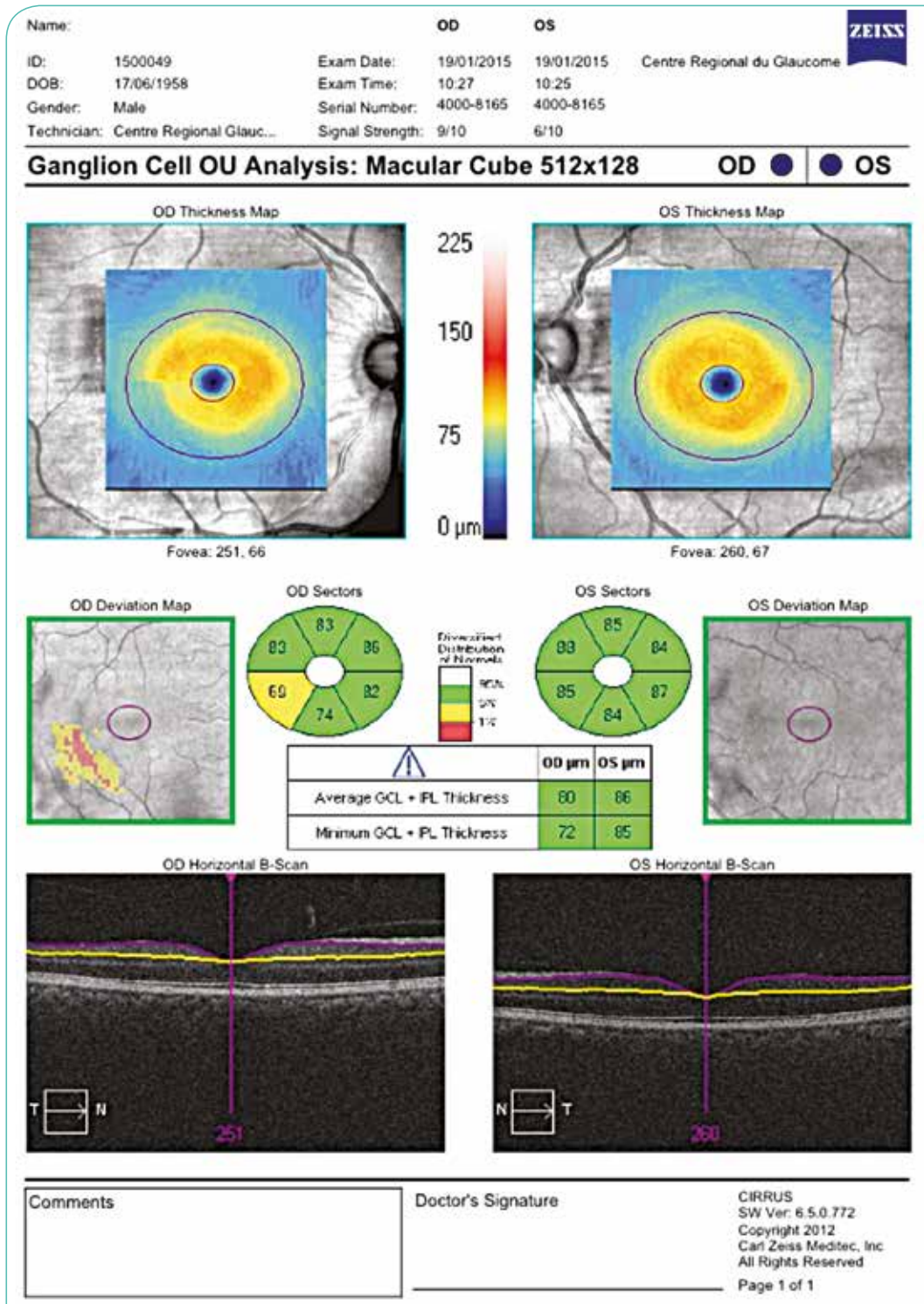


Figure 15: Notch in the macular vulnerability zone on the right, consistent with the lower axonal fibre defect seen in the retinal photographs.

In conclusion and at this stage, the diagnosis is a secondary pre-perimetric pseudoexfoliation capsular glaucoma.

Initiation of a treatment to reduce ocular hypertension with prostaglandin analogues is recommended.

After three year, the patient is stabilized by this monotherapy and the visual field has not worsened (Figures 16 and 17).

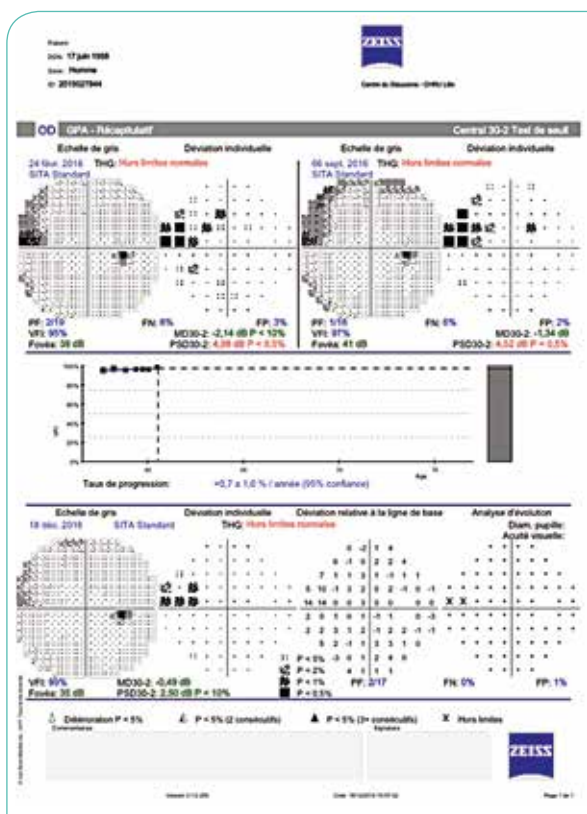


Figure 16: Analysis of the trend and events of the right eye stability.




Figure 17: Analysis of the trend and events of the left eye: normality.

On the other hand, OCT RNFL has changed and shows with a delay the axonal defect on the right but not yet on the left (Figure 18) the ganglion cell complex remains stable (Figure 19).

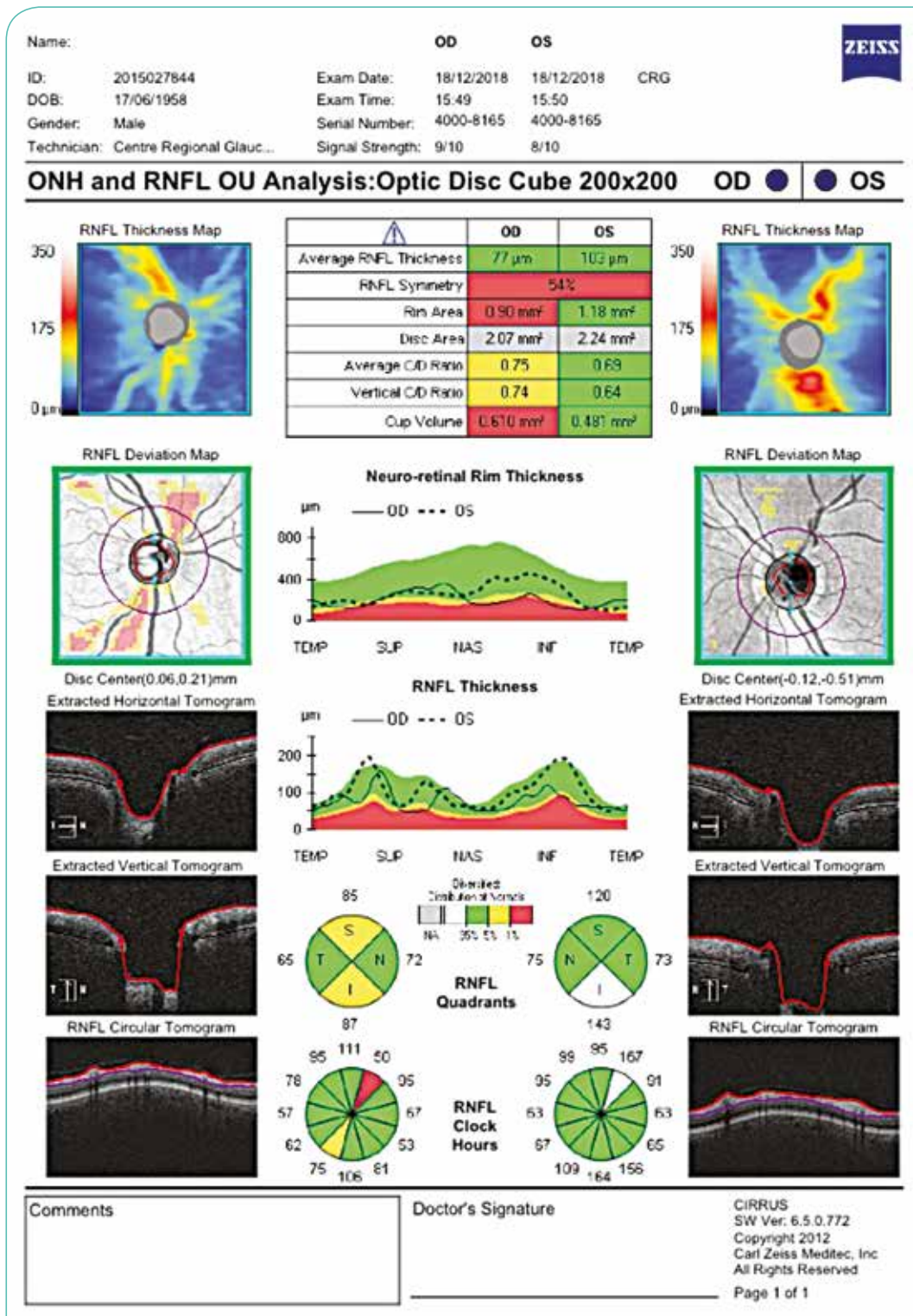


Figure 18: Damage lower right, normality on the left.

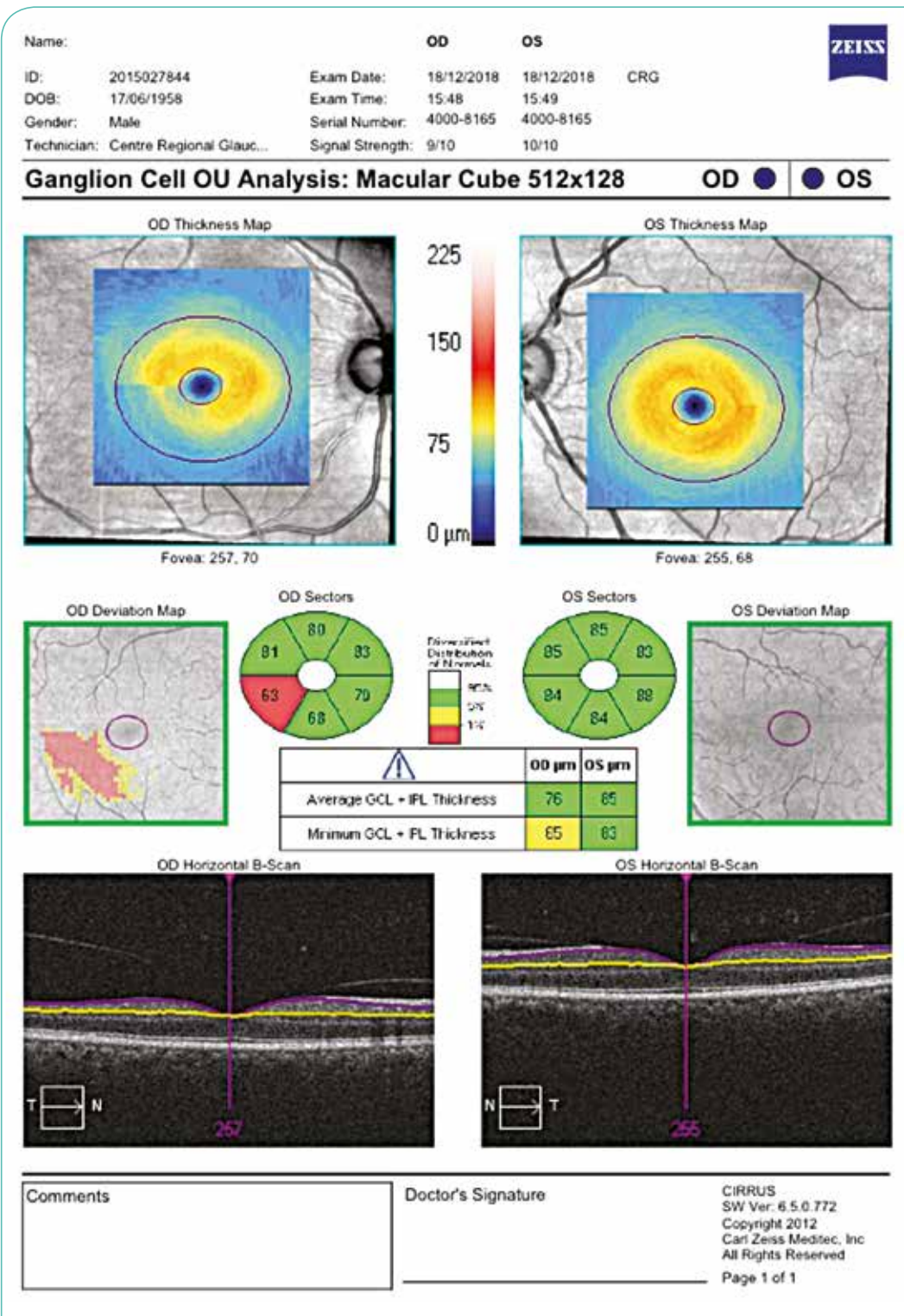


Figure 19: OCT, ganglion cell complex: stability.

Discussion

This clinical case highlights the importance, from the very first exam, of having an exhaustive assessment of the function through the visual field and the structure based on retinal photographs, OCT of axonal fibers (RNFL) and ganglion cell complex (GCC).

The OHTS⁽¹⁾ showed that in approximately 50% of cases the conversion of ocular hypertension into a PAOG occurred only by modification of the axonal fibers.

In 35% of cases the visual field alone was the determining factor that confirmed the conversion and two simultaneous involvements were only visible in about 10%.

Only two tests enabled confirmation of the diagnosis of pre-perimetric PAOG: retinal photographs and OCT by the study of the ganglion cell complex (GCC).

The RNFL analysis remained normal at first then defects appeared during the follow-up.

Literature does not favour either RNFL or GCC. A recent meta-analysis⁽²⁾ reports that RNFL is reached earlier but is less accurate for short-sighted patients or for those with anatomical abnormalities of the optic nerve head. Their association is therefore logical⁽³⁻⁴⁾.

References

1. Kass MA, Heuer DK, Higginbotham EJ, et al. The Ocular Hypertension Treatment Study : a randomized trial determines that topical ocular hypotensive medication delays or prevents the onset of primary open- angle glaucoma. *Arch Ophthalmol.* 2002; 120: 701-13.
2. Oddone F, Lucenteforte E, Michelessi M, et al. Macular versus retinal nerve fiber layer parameters for diagnosing manifest glaucoma: a systematic review of diagnostic accuracy studies. *Ophthalmology* 2016; 123: 939–49.
3. Kim KE, Park KH. Macular Imaging by Optical Coherence Tomography in the Diagnosis and Management of Glaucoma. *Br J Ophthalmol* 2018; 102: 718-724. doi:10.1136/bjophthalmol-2017-31086.
4. Renard JP, Magazzeni S, Fenolland R, Delbarre M : Tomographie par cohérence optique in Glaucome Primitif à Angle Ouvert Rapport SFO 2014 Elsevier ed Paris 162-187.

Answer to the MCQ on page 25: D

Answers to the MCQ on page 31: B, D and E



3

Young people under pressure

Case report

A 41-year-old patient is referred for management of narrow iridocorneal angle and ocular hypertension.

Upon examination visual acuity is 20/20 in both eyes with correction of a mild myopia (-1.5 diopters). Intraocular pressure is 25 mmHg in both eyes under prostaglandin analogues.

The anterior chambers are examined (Figure 1).

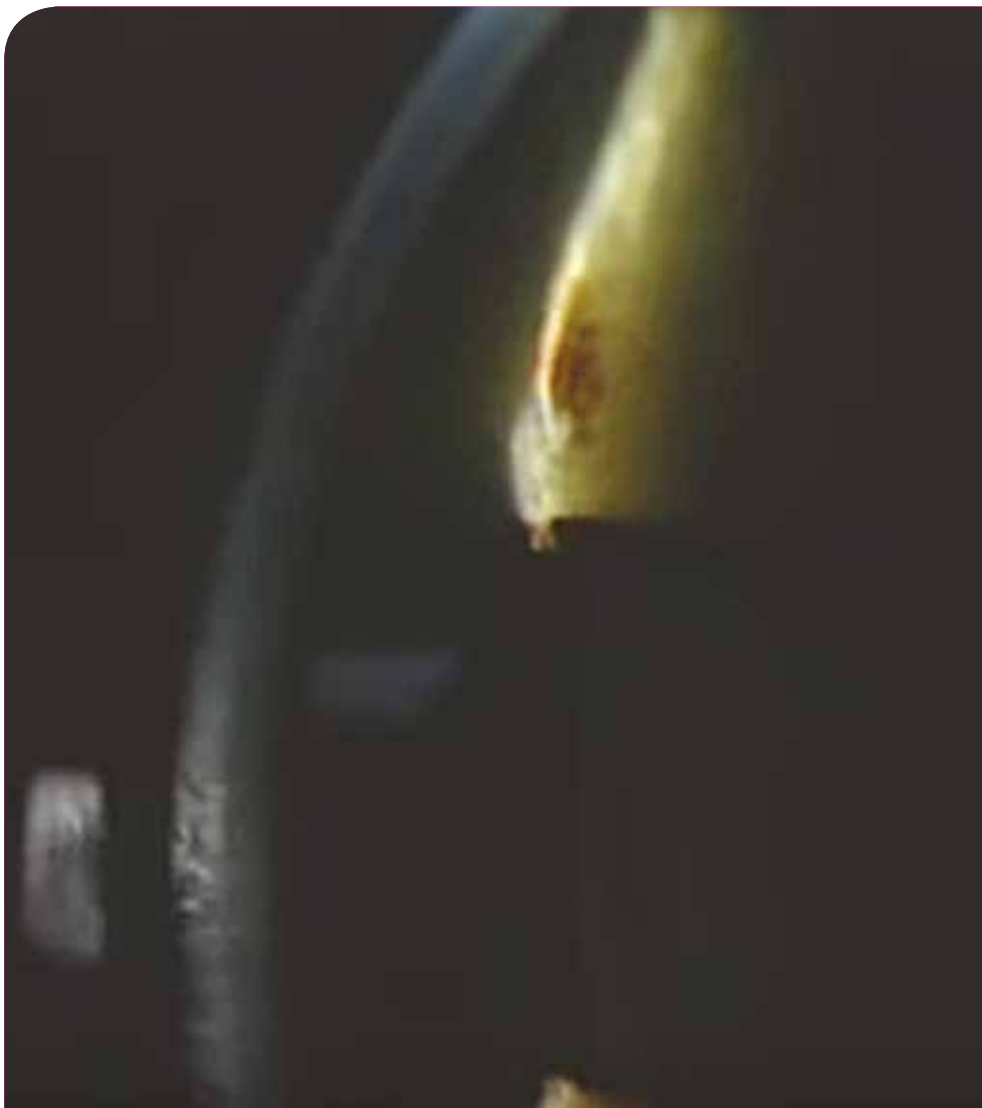

Figure 1: Anterior chamber.

In the periphery (Figure 2):

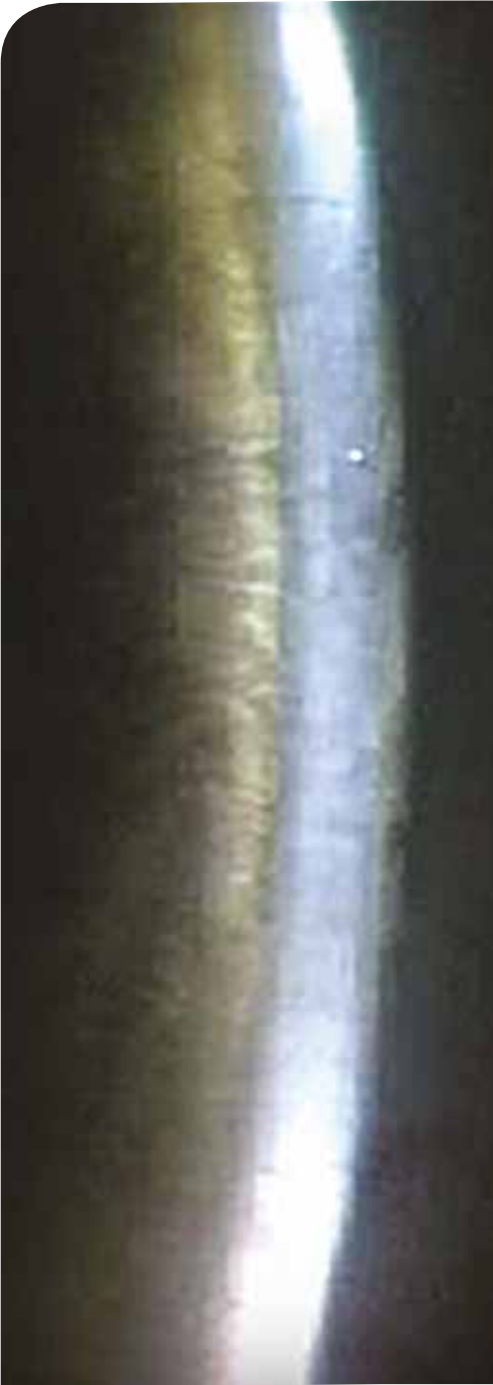

Figure 2: In the periphery.

Then gonioscopy is performed.

Figure 3: 3-mirror lens examination.

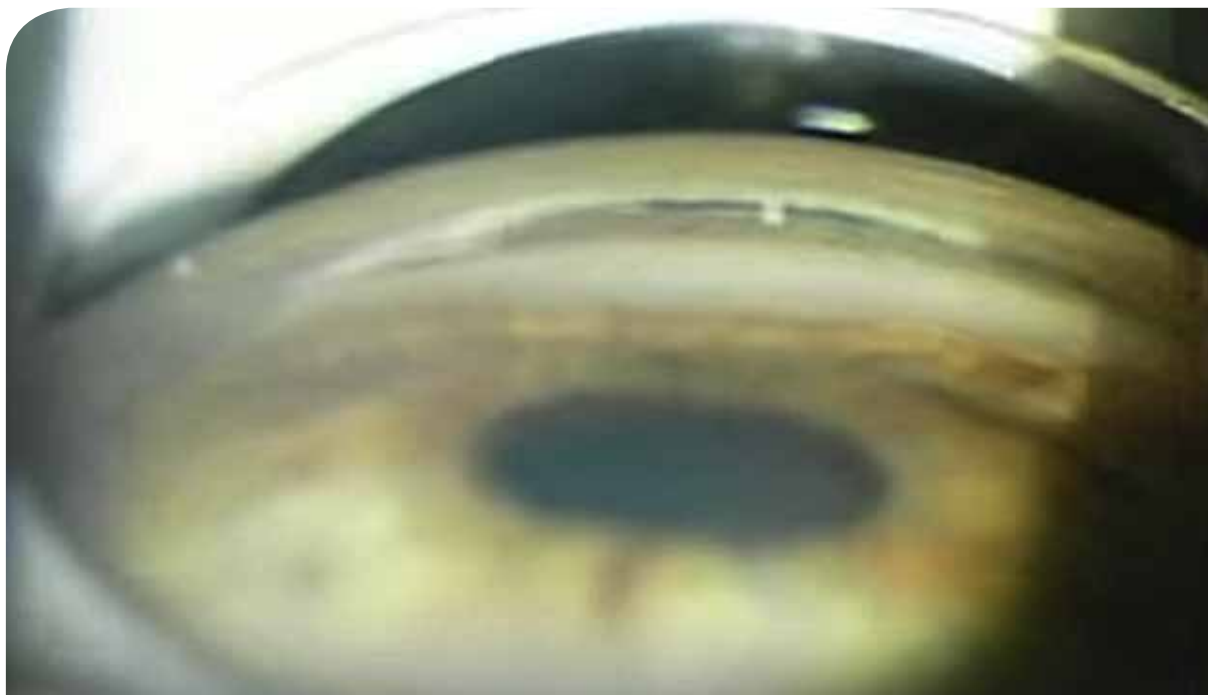


Figure 3: 3-mirror lens examination.

Posner lens examination (Figure 4):



Figure 4: Posner lens examination.

Multiple choice questions

1 Which condition can explain the gonioscopic appearance? (one correct answer)

- A. Primary angle-closure glaucoma
- B. Choroidal melanoma
- C. Neovascular glaucoma
- D. Iridocorneal endothelial syndrome
- E. Plateau iris syndrome

2. Regarding management, what are the good answers? (two correct answers)

- A. Medical treatment alone is sufficient.
- B. A selective trabeculoplasty can complete medical treatment.
- C. Laser iridotomy can be performed to remove a pupillary block component.
- D. Lens extraction must be performed.
- E. If the iridotomy has no effect, laser iridoplasty can be envisaged.

Answers to the MCQ on page 51

Complete case report and answer to the question

The slit lamp exam shows a deep anterior chamber in the center but narrow in the periphery.

The gonioscopic examination shows a flat iris with an anterior surface that runs straight outwards almost to the trabecular meshwork, then depicts a significant posterior convexity delineating a narrow angle recess strongly tilted in relation to the iris plane.

The passage of light to obscurity results in a complete apposition of the iris against the pigmented trabecular meshwork. Dynamic gonioscopy only allows a partial reopening of the iridocorneal angle.

During the indentation of the center of the cornea by the Posner lens, the persistence of a swelling iris prevents a large reopening of the angle (a double hump appearance).

The examination of the eye fundus shows no excavation of the optic disc. OCT of the peripapillary retinal nerve fiber layer and the 24-2 white-on-white visual field does not show any abnormalities.

A plateau iris syndrome is invoked and high-frequency ultrasound of the anterior segment (ultrasound biomicroscopy, Aviso 50 Mhz, Quantel, France) performed (Figure 5).

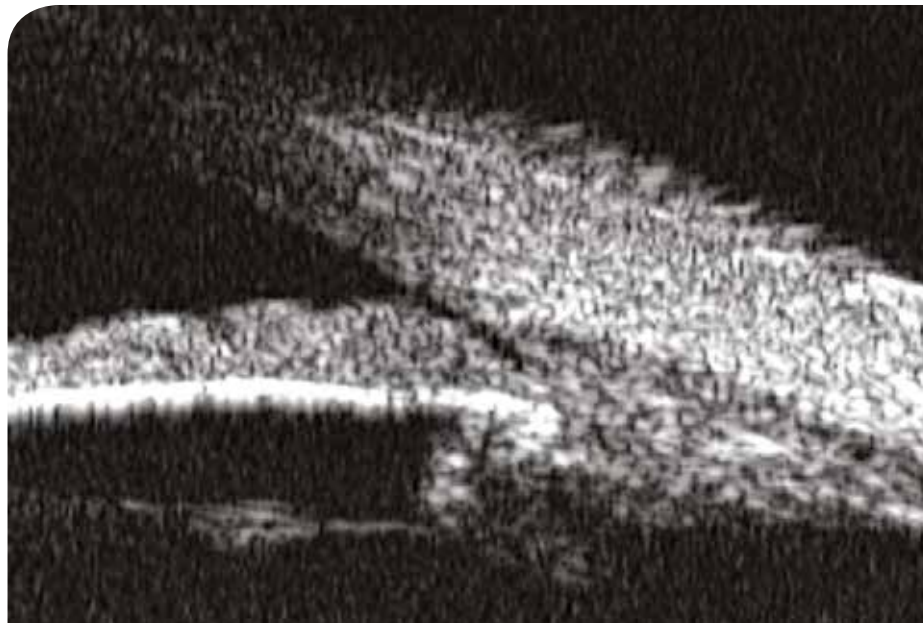


Figure 5

This confirms the existence of a plateau iris syndrome by showing a voluminous anteriorly positioned ciliary body pressing against the posterior surface of the iris and thus concealing the ciliary sulcus. The anterior surface of the iris is flat, then depicts a posterior and external course, delineating a narrow angle recess in the shape of “a flute mouthpiece”.

Laser iridotomy is performed without anatomical effect on the opening of the iridocorneal angle. Bilateral Argon laser iridoplasty is performed. By thinning the base of the iris, it enables a significant reopening of the iridocorneal angle.

Before iridoplasty (Visante OCT, Zeiss Meditec, USA)(Figure 6):

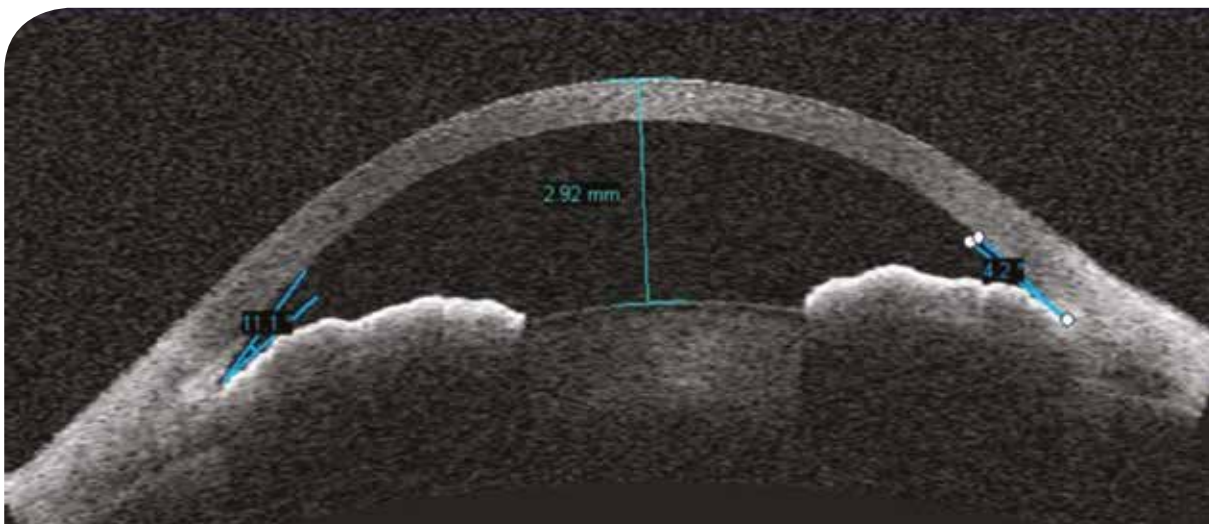


Figure 6

After iridoplasty (Figure 7):

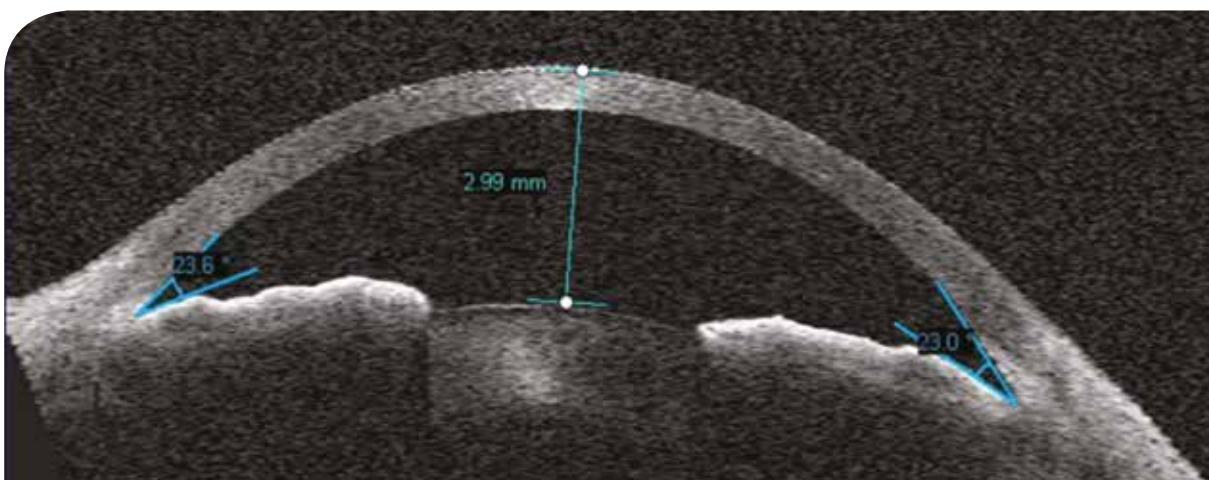


Figure 7

Intraocular pressure under prostaglandin analogues is maintained at about 20 mmHg. A simple bi-annual follow-up is performed.

Overview of the topic discussed in the case

Plateau iris syndrome is a relatively uncommon form of primary angle-closure glaucoma that can occur despite the presence of a patent iridotomy.

The term “plateau iris” indicates the presence of a flat iris in which the anterior surface runs in a straight line almost to the trabecular meshwork, then depicts a significant posterior convexity, delineating a narrow angle recess strongly tilted in relation to the iris plane.

In the case of plateau iris syndrome, pupil dilation can result in iridocorneal angle closure by a thickening of the iris root, even in presence of an iridotomy and therefore without pupillary block.

In the case of a plateau iris configuration, a relatively similar anatomical configuration of the iris combines with a pupillary block component that results in iridocorneal angle closure and thus iridotomy in this case is able to reopen the iridocorneal angle.

Plateau iris configuration and plateau iris syndrome are anatomico-clinical entities that have been described relatively recently.

The advent of ultrasound biomicroscopy has made it possible to have a much better understanding of their pathophysiological mechanisms.

Plateau iris syndrome

Plateau iris syndrome occurs more frequently in young, far-sighted female subjects. Although the overall incidence of plateau iris syndrome is low, it is the primary cause of angle closure in subjects under 50 year old⁽¹⁾.

Plateau iris syndrome is characterized by an acute or chronic iridocorneal closure secondary to abnormalities in the form and position of the ciliary body and iris root. An abnormally voluminous ciliary body anteriorly positioned will mechanically bring the peripheral iris in contact with the trabecular meshwork.

During pupillary dilation, or sometimes even spontaneously, the iris root will thicken and form the equivalent of a ridge that will bridge the angle recess and stick to the trabecular meshwork. In the case of a pure plateau iris syndrome, this mechanism alone will close the iridocorneal angle without the participation of a pupillary block mechanism.

Therefore, iridotomy or iridectomy will not change the position of the iris and will not enable the reopening of the iridocorneal angle. It should be noted that, in rare cases, multiple cysts of the ciliary body or pigmented epithelium can result in a comparable clinical picture. The ultrasound biomicroscopy test can eliminate these differential diagnoses and indicate a suitable treatment plan.

Plateau iris configuration

Plateau iris configuration combines, in variable parts, an anatomical aspect of plateau iris described above and a pupillary block mechanism.

It generally occurs in older subjects, as the increase in lens size increases the relative pupillary block. In this case, the abnormal form and position of the ciliary body and iris root do not enable it alone to achieve a complete closure of the iridocorneal angle.

The coexisting pupillary block mechanism will participate in the closure of the iridocorneal angle and this explains the efficacy of iridotomy or iridectomy.

The pupillary block is a result of the decrease of space between the anterior surface of the lens and the posterior surface of the iris, which leads to an increase of resistance to aqueous humor flow through the pupillary orifice and to an increase of the pressure gradient between the posterior chamber and the anterior chamber.

This difference in pressure on both sides of the iris will move the iris forward, especially the peripheral iris that is thinner and probably more mobile due to the anatomical situation of the dilator muscles and sphincter of the iris that are mainly responsible for the biomechanical properties of the iris.

Clinical diagnosis and ultrasound

Angle closure resulting in an increase in intraocular pressure can be sudden or gradual and secondary to pupillary dilation or spontaneous.

The biomicroscopic test of the anterior segment shows the presence of an anterior chamber of normal depth or slightly less and a flat or slightly convex anterior surface of the iris.

The gonioscopic examination reveals a very narrow or closed iridocorneal angle with a very pronounced and deep angle recess (a very pronounced and very peripheral posterior convexity).

The passage from light to obscurity results in a peripheral thickening of the iris and to bridging of the angle recess sometimes visible during the gonioscopic examination.

Dynamic gonioscopy enables only a partial reopening of the iridocorneal angle, often less evident than that observed in the case of angle closure following a pupillary block.

Pure plateau iris syndrome is quite rare and combination with a pupillary block component quite frequent.

Therefore, the diagnosis of plateau iris syndrome can only be made in the case of persistent angle closure despite the presence of an iridotomy or patent iridectomy.

As clinical signs of plateau iris are often quite subtle, it is often the absence of reopening of the angle after iridotomy that prompts the clinician to look for and detect plateau iris syndrome.

Ultrasound biomicroscopy is the preferred method to examine the ciliary body and describe plateau iris syndrome^(2,3). The main ultrasound characteristics of plateau iris syndrome are:

- A voluminous ciliary body (especially voluminous processes)
- Antero-positioning of the ciliary body
- Partial or complete obliteration of the ciliary sulcus
- Normal or slightly reduced depth of the anterior chamber
- A very reduced ciliary-trabecular meshwork distance

Iridotomy and iridoplasty

Pure plateau iris syndrome is quite rare and combination with a pupillary block component quite frequent.

Clinical exams as well as ultrasound can never eliminate an associated pupillary block mechanism with certainty.

Therefore, it is now universally recognised that laser iridotomy is the first stage of management and an indispensable pre-condition for the diagnosis of plateau iris syndrome.

The visualization of the clinical characteristics and ultrasound data described above and the absence of a reopening of the iridocorneal angle after a patent iridotomy will thus provide a basis for establishing the diagnosis of plateau iris syndrome.

An iridoplasty can also be proposed and sometimes, by retracting and thinning the base of the iris, can enlarge the angle recess and reopen the iridocorneal angle⁽⁴⁾.

The existence of peripheral anterior synechiae does not appear to contraindicate the performance of laser iridoplasty, when they do not reach the entire circumference of the iridocorneal angle, thus enabling at least a partial reopening of the angle.

Medical treatment with myotics can also thin the peripheral iris and reopen the angle.

Lastly, without a reopening of the angle associated with poor pressure control, a trabeculectomy and/or lens extraction can also be indicated. Due to the configuration of the iridocorneal angle, non-perforating filtration surgery or micro-invasive surgery are probably not suitable, even after performance of laser iridoplasty.

Ciliary body coagulation techniques (diode laser, ultrasound) could also reduce the volume of the ciliary body and open the iridocorneal angle⁽⁵⁾.

References

1. Ritch R, Chang BM, Liebmann JM. Angle closure in younger patients. *Ophthalmology*. 2003 Oct; 110(10): 1880-9.
2. Liebmann JM, Ritch R. Ultrasound biomicroscopy of the anterior segment. *J Am Optom Assoc*. 1996 Aug; 67(8): 469-79.
3. Pavlin CJ, Ritch R, Foster FS. Ultrasound biomicroscopy in plateau iris syndrome. *Am J Ophthalmol*. 1992 Apr 15; 113(4): 390-5.
4. Ritch R, Tham CC, Lam DS. Long-term success of argon laser peripheral iridoplasty in the management of plateau iris syndrome. *Ophthalmology*. 2004 Jan; 111(1): 104-8.
5. Francis BA, Pouw A, Jenkins D, Babic K, Vakili G, Tan J, Chopra V, Green RL. Endoscopic Cycloplasty (ECPL) and Lens Extraction in the Treatment of Severe Plateau Iris Syndrome. *J Glaucoma*. 2016 Mar; 25(3): e128-33.

Answers to the MCQ on page 45:

Question 1: E

Question 2: C and E



4

More than just glaucoma

Case report

Miss A, 16-year-old is referred to our department to assess an ocular hypertension, found incidentally during a renewal of her corrective lenses.

Intraocular pressure measured twice was 38 mmHg in both eyes.

A hypotonic treatment with a fixed prostaglandin analogue-beta blocker combination was started following the initial consultation.

The interview found no functional complaint. There is no particular personal or family eye history.

The ophthalmologic examination is as follows:

- AV Right: 20/20 (+1.50 (-0.5 175°))
- AV Left: 20/20 (+3.0 (-1.0 170°))

Corneal diameter is normal, without edema or corneal abnormality.

Intraocular pressure measured with the Goldmann tonometer is 15 mmHg in both eyes (pachymetry 495 μ m) under hypotonic treatment for 3 weeks.

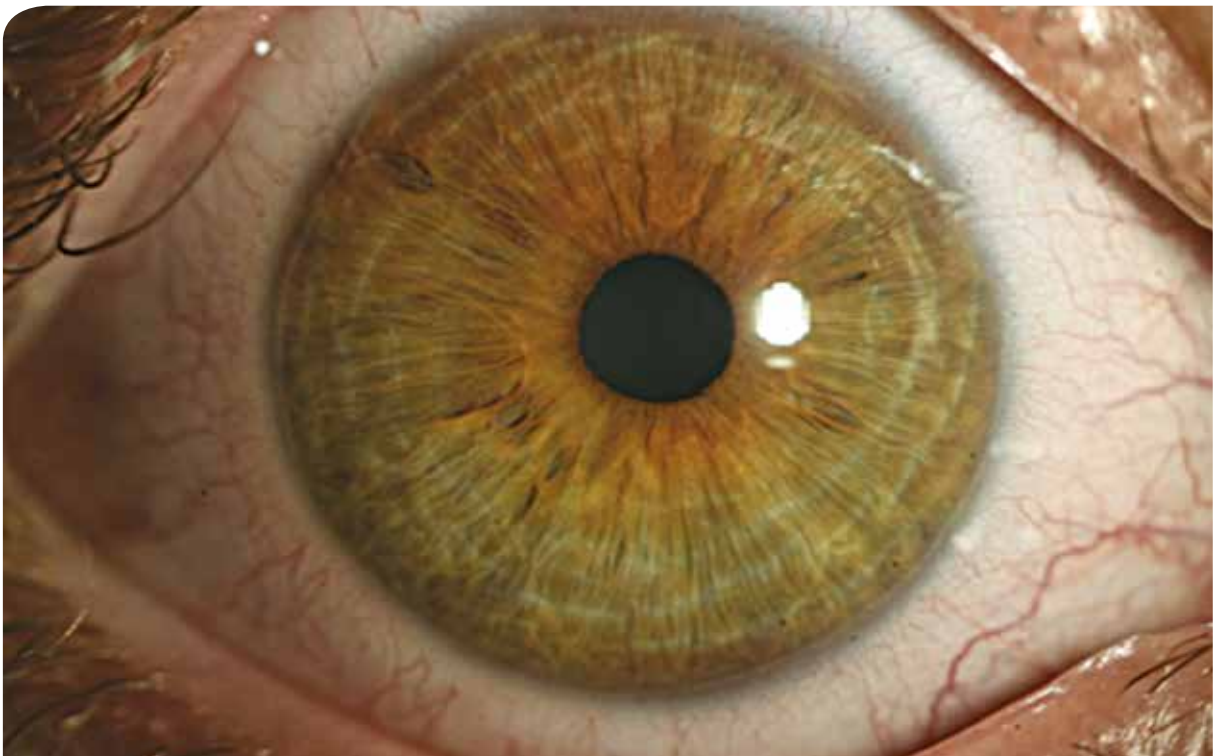


Figure 1: Posterior embryotoxon found in both eyes.

The biomicroscopic test found a bilateral posterior embryotoxon (Figures 1 and 2).

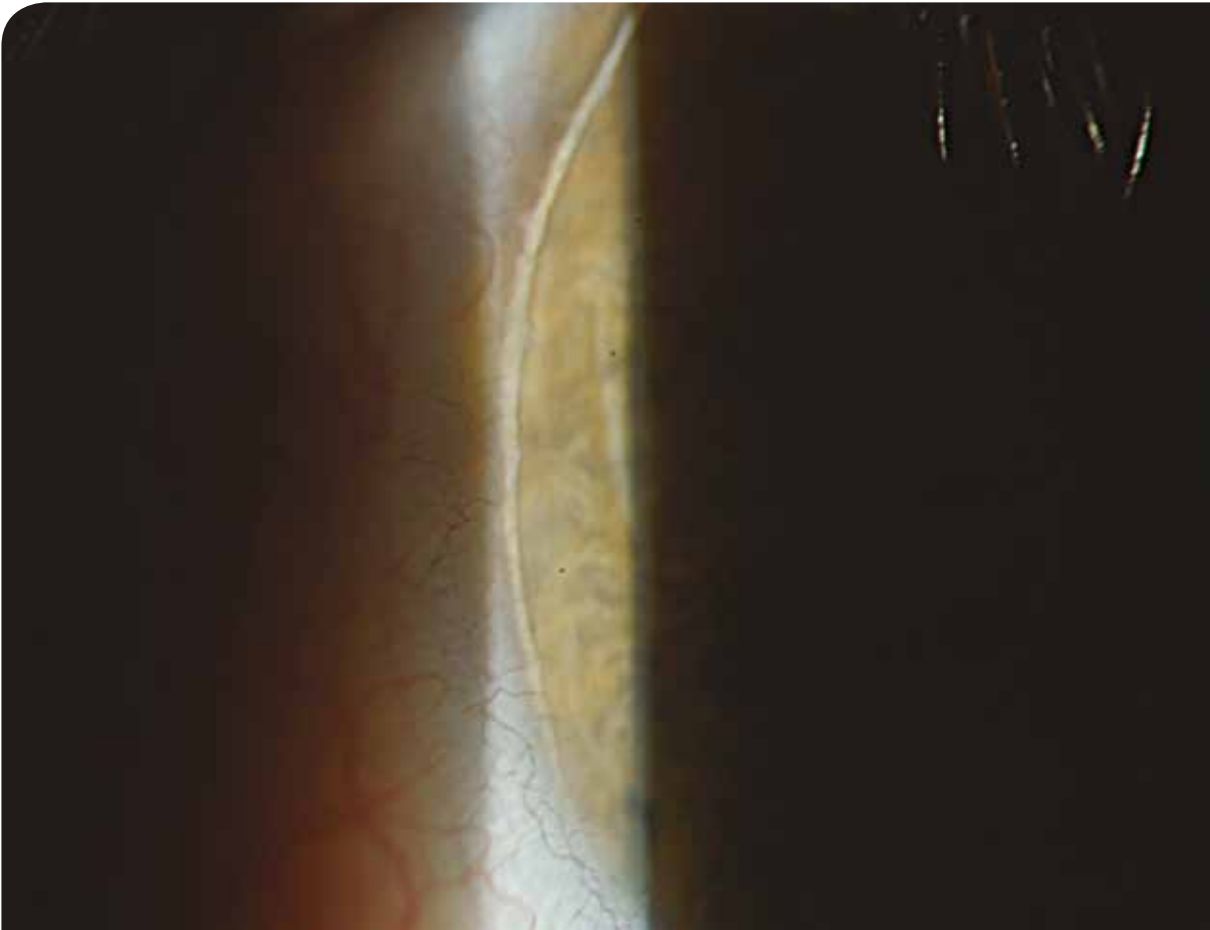

Figure 2: Posterior embryotoxon: enlargement in the temporal side of right eye.

The eye fundus examination notes damage to the right optic disc but the left optic nerve head appears clinically unaffected (Figures 3 and 4).

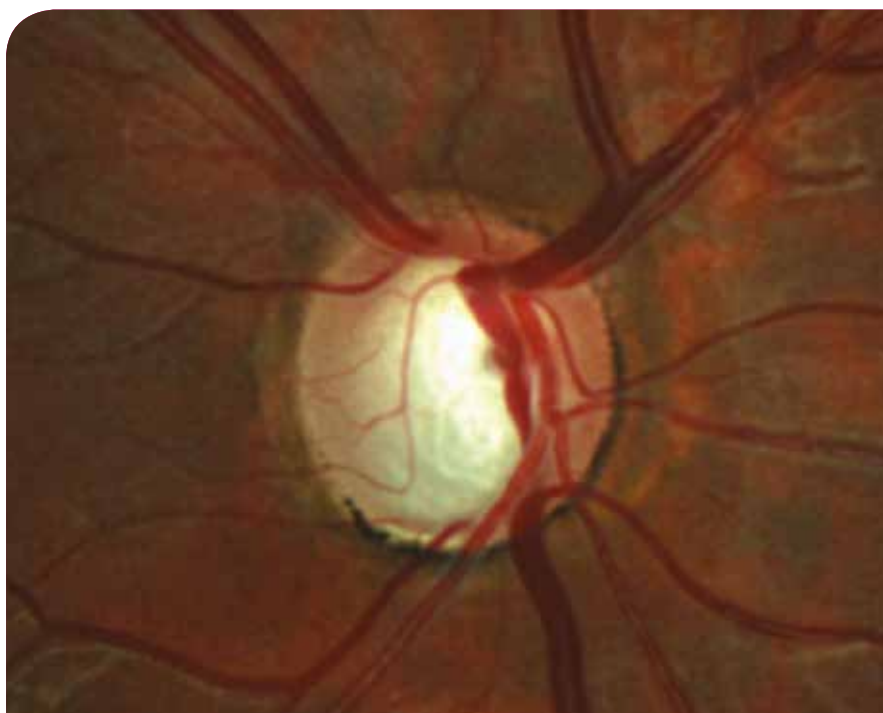


Figure 3: Right optic disc.

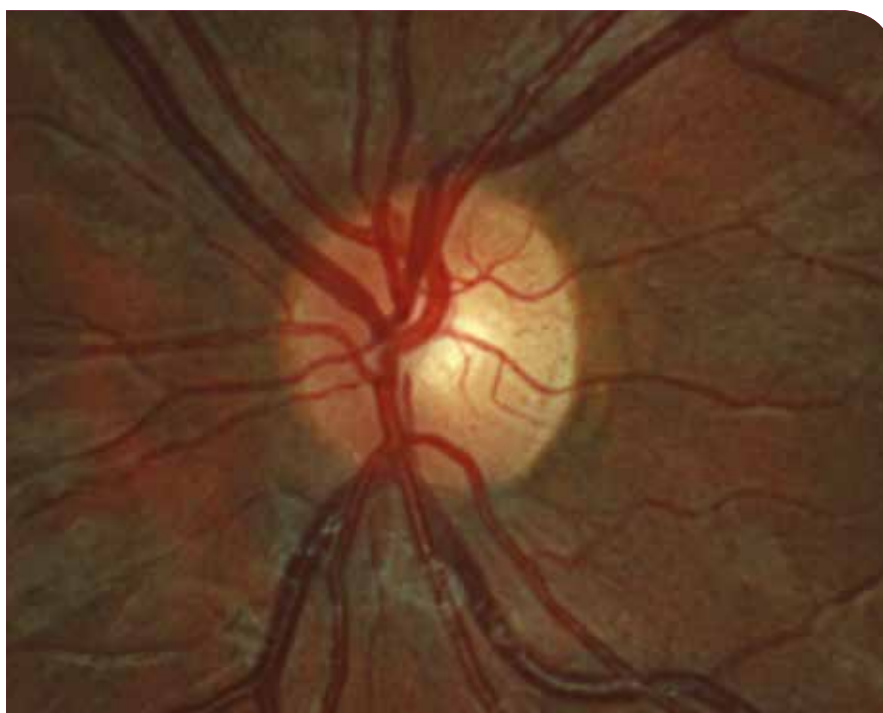

Figure 4: Left optic disc.

Multiple choice question

What diagnosis do you expect from this ophthalmologic exam?

- A. A congenital glaucoma
- B. Steroid-induced glaucoma
- C. Primary juvenile glaucoma
- D. Axenfeld-Rieger glaucoma
- E. A bilateral post-traumatic glaucoma

Answer to the MCQ on page 65

Complete biomicroscopic exam and bilateral gonioscopy. The angle is wide with hypertrophy of Schwalbe's line: posterior embryotoxon associated with numerous iris tissue bridges terminating on Schwalbe's line: goniodysgenesis over 360° of both eyes (Figures 5 and 7).



Figure 5: Goniodysgenesis between the iris and Schwalbe's line.

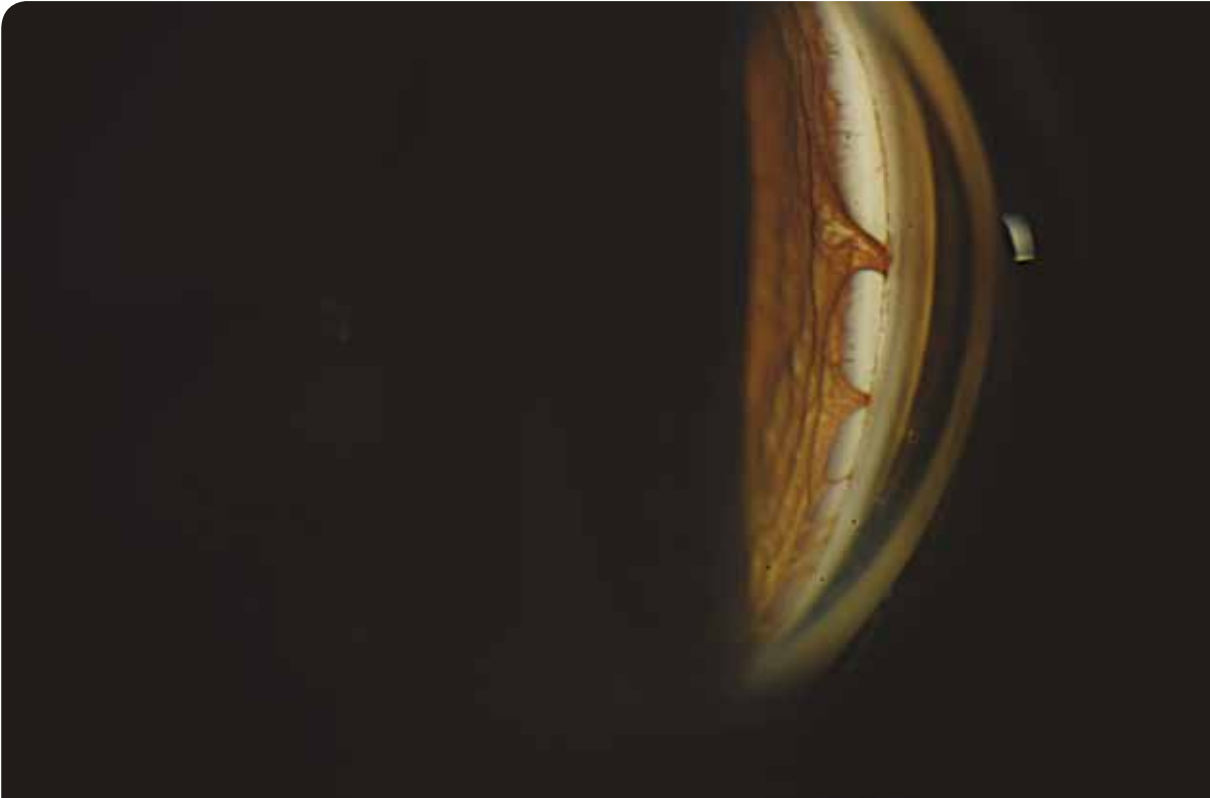


Figure 6: Extensive dysgenesis disorders.



Figure 7: Anomalies are found over 360° in both eyes.

The optical tomography examination of the angle shows a wide angle with a flat iris and dysgenesis seen in gonioscopy (Figures 8 and 9).

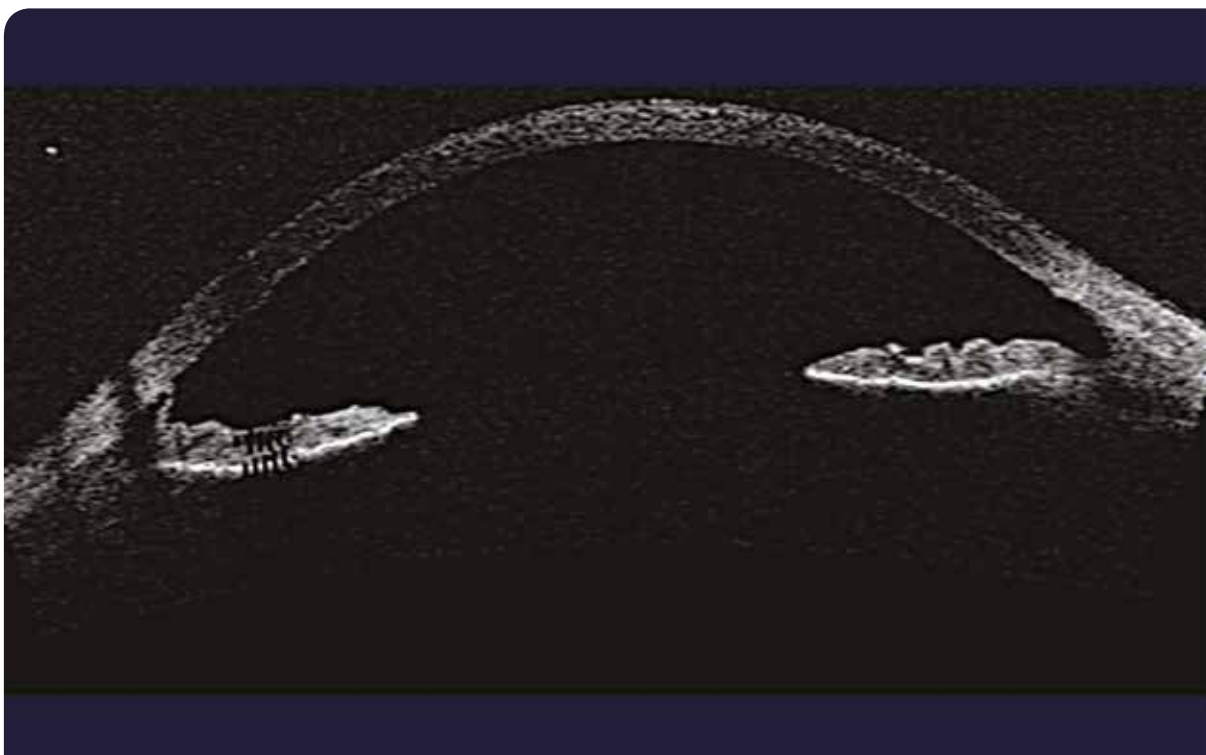


Figure 8: OCT of the angle with iridocorneal bridge.

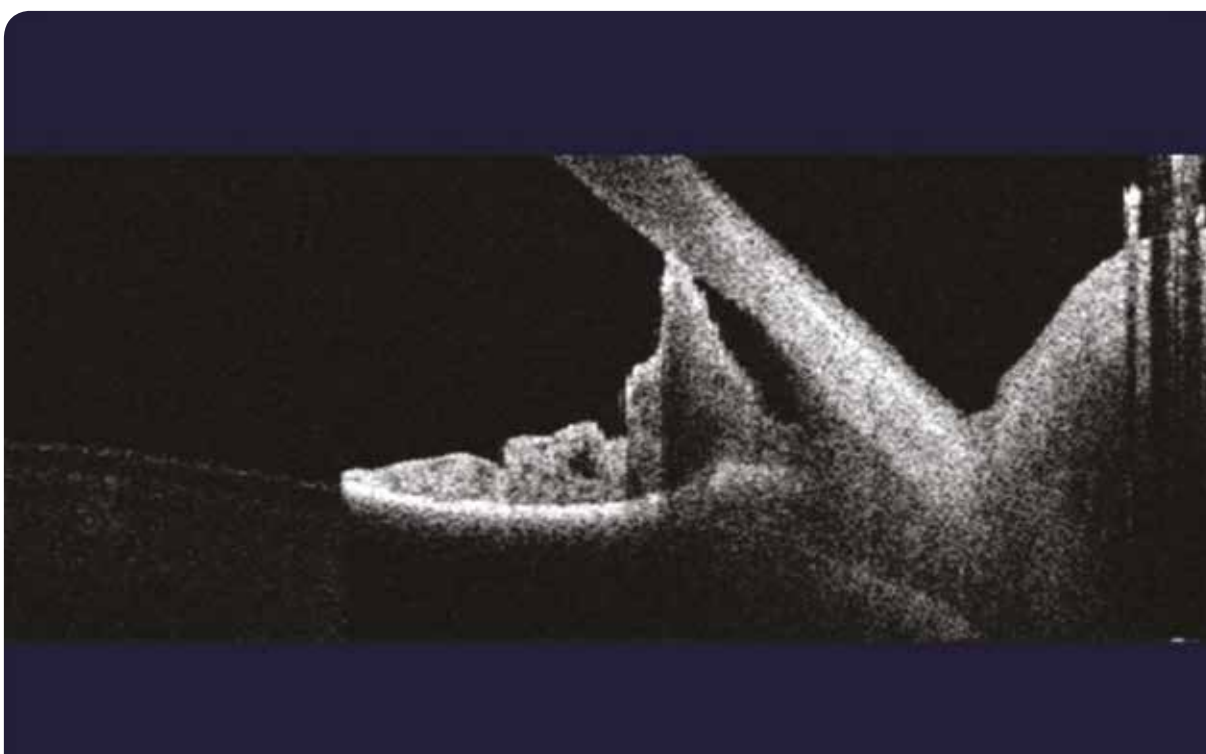


Figure 9: Detail of goniodysgenesis.

The diagnosis of Axenfeld-Rieger syndrome is suspected and is supported by the examination of dentition (Figure 10).

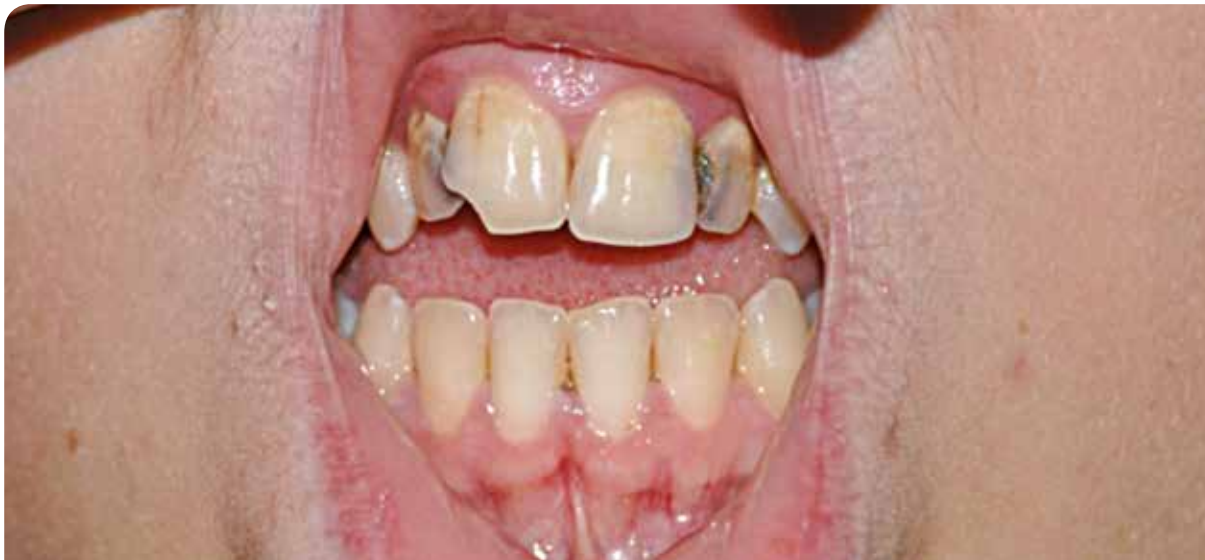

Figure 10: Microdontia.

Measurement of the visual field confirms right papillary damage with a superior scotoma (Figure 11) consistent with lack of defect in the left eye.

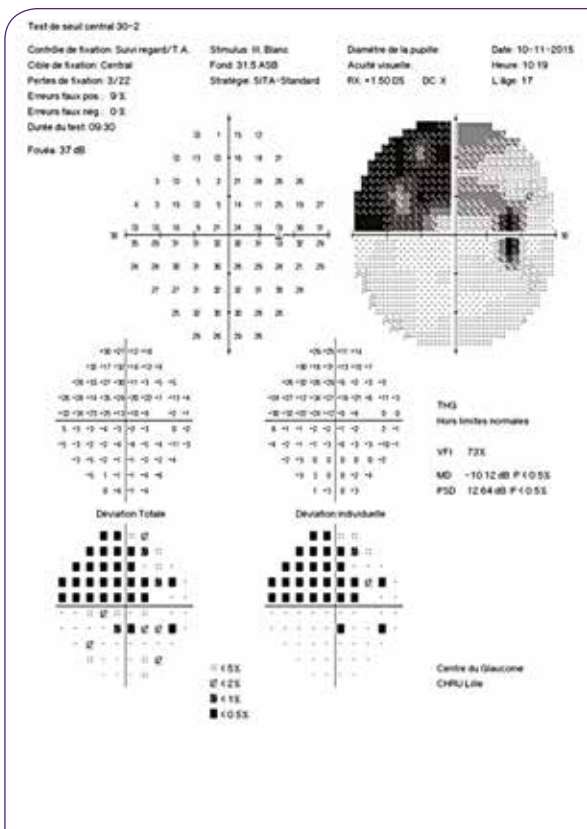


Figure 11: Abnormal standard right visual field.

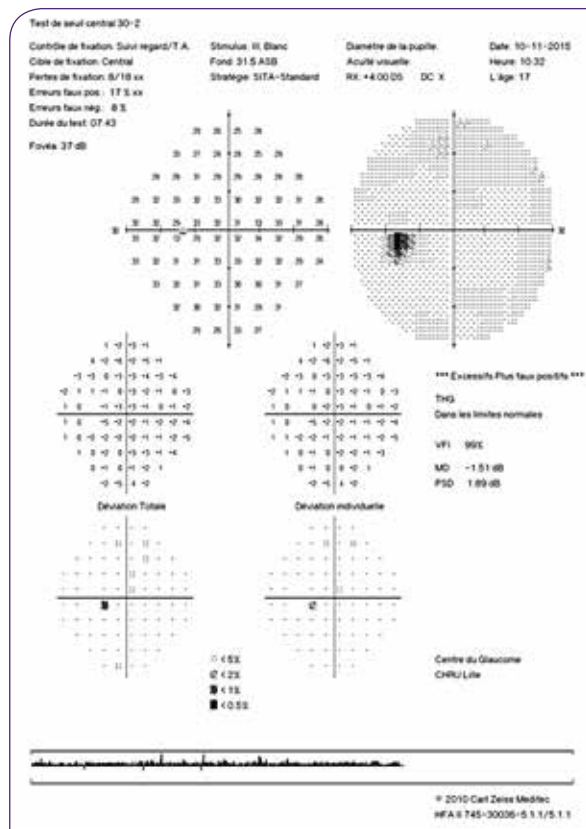


Figure 12: Normal standard left visual field.

The RNFL exam found a significant defect in the fibers on the right and within the normal range on the left (Figure 13).

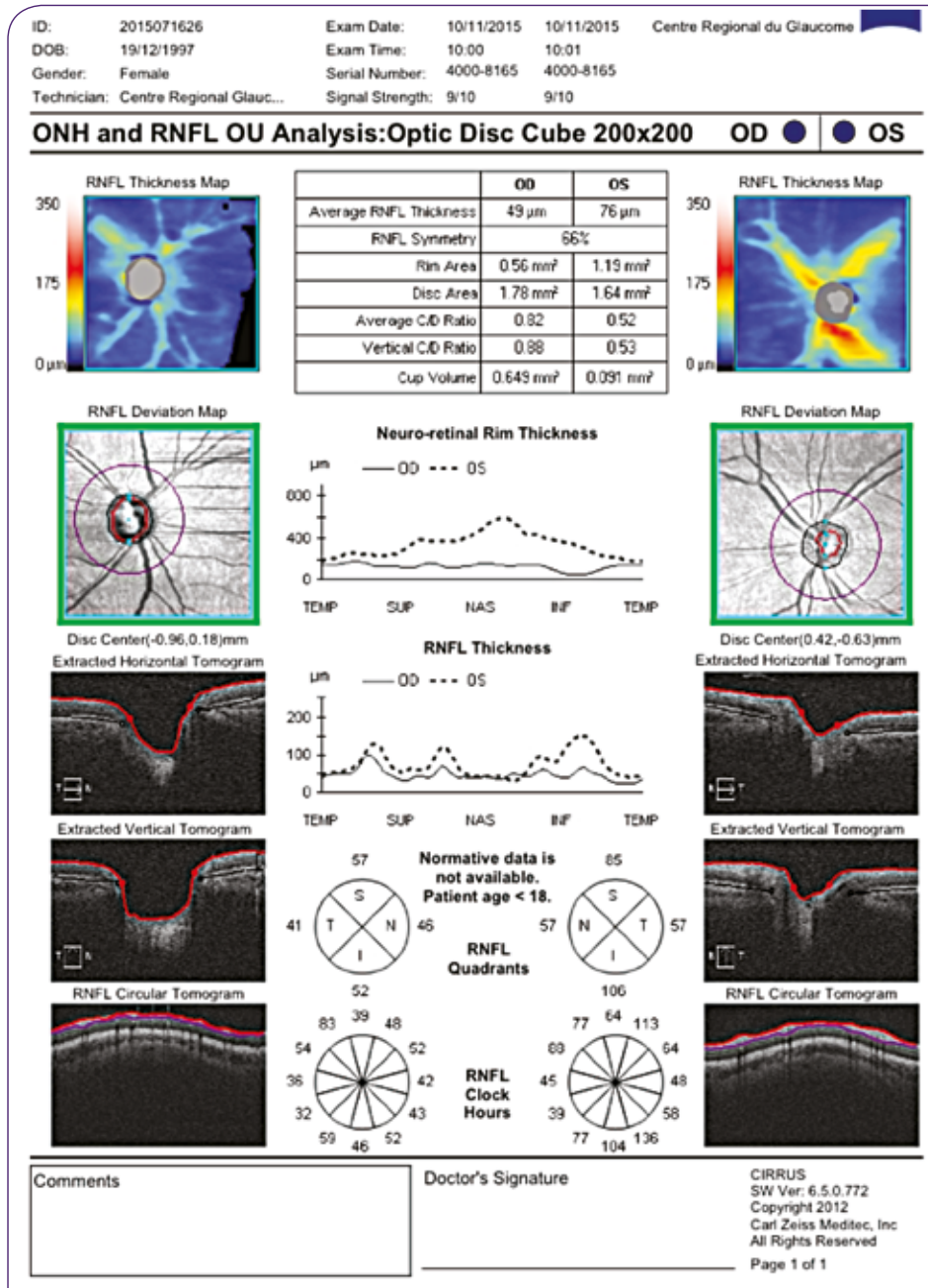


Figure 13: RNFL of both eyes: damage predominant on the right (no normative values for patients under 18 year).

The exploration of the ganglion cell complex (GCC) is also altered on the right (Figure 14).

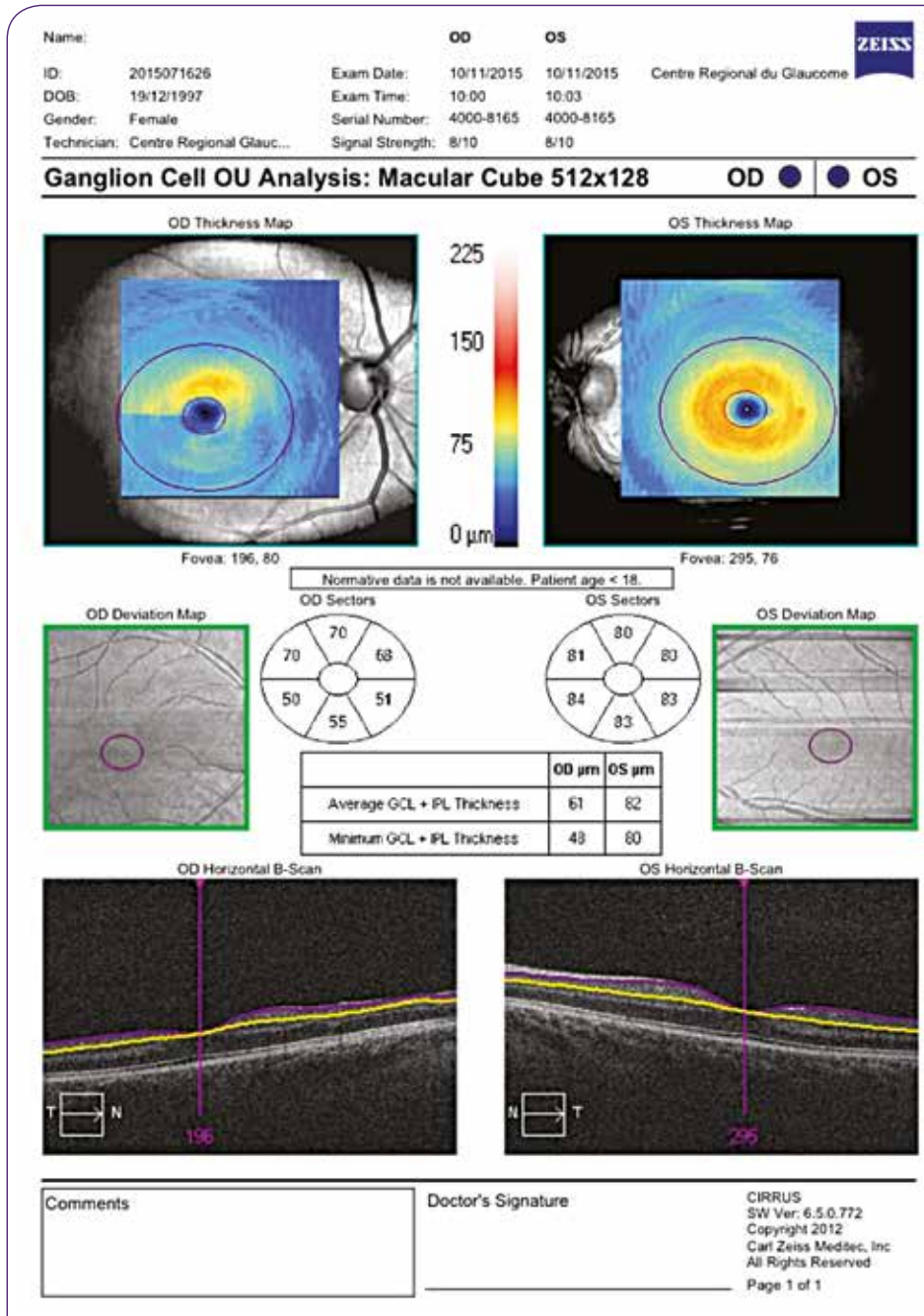


Figure 14: inferior right GCC damage.

The diagnosis of Axenfeld-Rieger syndrome with glaucoma more developed on the right is suggested. As this is an initial assessment and the start of local hypotonic treatment is very recent, we recommend the continuation of this initial local treatment with a follow-up in three months and new comparative exam.

Axenfeld-Rieger syndrome

Axenfeld-Rieger syndrome is a component of dysgnesis of the anterior segment.

This genetic disease attacks different organs other than the face and eye: heart, skeleton and skin.

Initially described by Axenfeld in 1920 given the association of a posterior embryotoxon and abnormalities of the iris, Rieger completed the clinical picture by adding goniodysgenesis and corectopia associated with the abnormalities described by Axenfeld.

Molecular genetics confirms that it is a common entity with various expressions of which 50% can result in glaucoma.

Ocular involvement

The age of diagnosis is very variable. Glaucoma can be present from birth, sometimes even with a clinical pattern of congenital glaucoma: buphthalmia, photophobia, corneal edema and ocular hypertension.

However, more often abnormalities of the iris (corectopia) prompt a consultation or in a family with Axenfeld-Rieger, a exam is requested leading to the discovery of posterior embryotoxon and goniodysgenesis.

The most frequent abnormality is posterior embryotoxon, which is a complete (360°) hypertrophied Schwalbe's ring.

Mandatory gonioscopy shows thin or thick bridges more or less numerous between the iris and Schwalbe's line, bridging in front of the trabecular meshwork.

The traction of this adherences can cause corectopia.

Glaucoma, present in 50% of cases, is the consequence of a perturbation of the development of the trabecular meshwork with a reduction of intertrabecular spaces or even associated with a rudimentary Schlemm's canal.

Defects in the iris can appear over time developing extensively or even cause a rupture of the iris sphincter.

General involvement

Facial dysmorphism is very frequent with a flattening of the base of the nose and hypertelorism, telecanthus, and mandibular ascending ramus hypoplasia can be found.

Microdontia is a dental abnormality that affects the upper incisors in particular or can even lead to missing teeth.

Deafness can be present.

Cardiac impairment especially of the valves must be systematically checked.

A common skin defect is the regression of peri-umbilical tissue that can be mistaken for an umbilical hernia.

The following general disorders are also reported, namely hypospadias and empty sella turcica syndrome.

Genetics

Autosomal dominant transmission. Two main genes have been identified: PITX2 and FOXC1.

Treatment of glaucoma

The management of glaucoma is identical to that of pediatric glaucoma. Initial treatment is most often medical with hypotonic eye drops.

Trabeculectomy surgery will be preferred to goniotomy.

In the event of failure, trabeculectomy or even a valve will be the preferred treatments⁽⁴⁾.

References

1. Axenfeld-Rieger syndrom : new perspectives Chang TC, Summers CG, Schimmenti LA, Grajew. Br J Ophthalmol 2012 ; 96: 318-322.
2. Opacités congénitales de cornée et dysgénésies du segment antérieur. Clinique, phénotypes et classification : Bui Quoc E, Beylerian M, Denis D. : in Rapport SFO 2017 Ophtalmologie Pédiatrique Elsevier ed Paris : p.276.
3. Axenfeld Rieger syndrome. Aref AA, Loch AR et al Eyewiki.org. oct 2019.
4. Early-onset glaucoma in Axenfeld-Rieger anomaly: long-term surgical results and visual outcome Mandal AK, Pehera N : Eye (2016) 30, 936-94.

Answer to the MCQ on page 57: D



5

Indented iris

Case report

A 52-year-old patient is referred to receive laser peripheral iridotomy for a narrow iridocorneal angle in both eyes.

Visual acuity is 20/20 in both eyes without correction.

Intraocular pressure is 17 mmHg in both eyes without treatment.

The examination of the anterior segment shows a deep chamber in the center and narrow in the periphery.

In gonioscopy the anterior surface of the iris appears slightly bosselated around the entire circumference. The iridocorneal angle is narrow without reopening in dynamic gonioscopy. Fundus uneventful.

Peripheral anterior chamber depth shallow and iris with bosselated appearance (Figure 1).

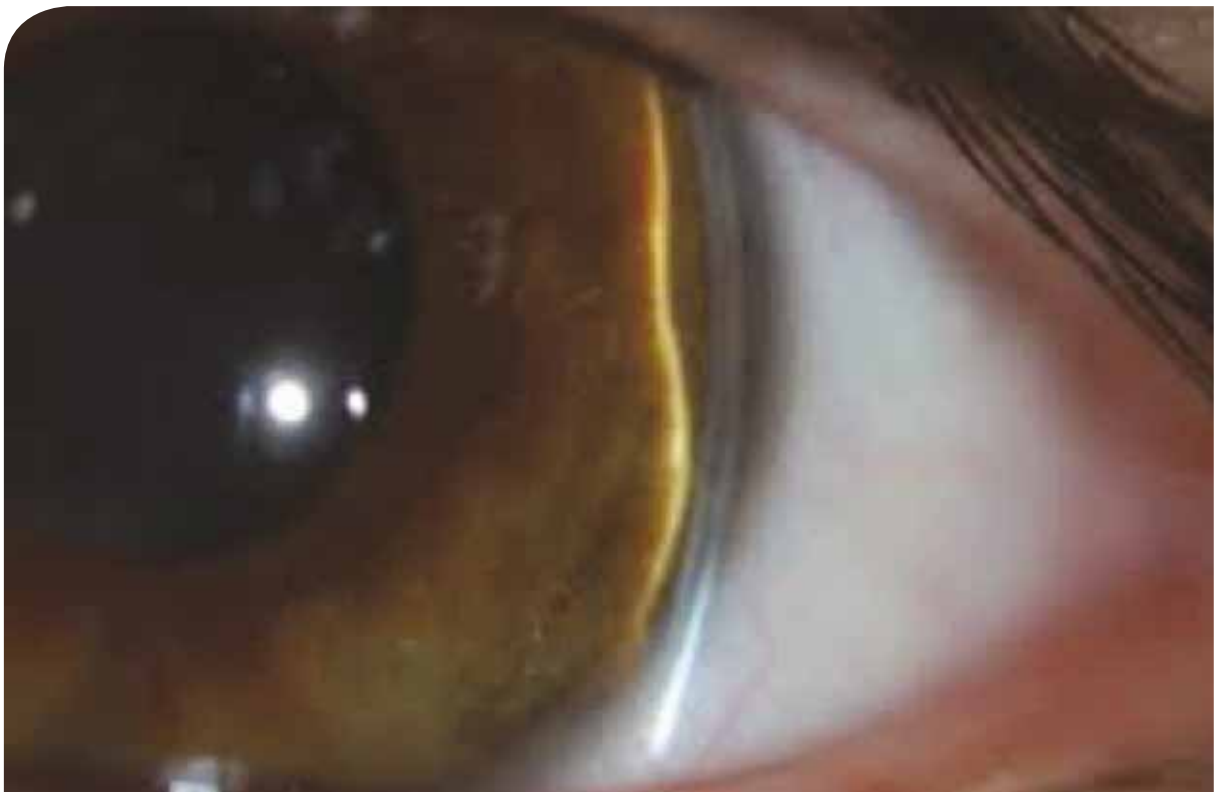

Figure 1: Examination of the anterior segment.

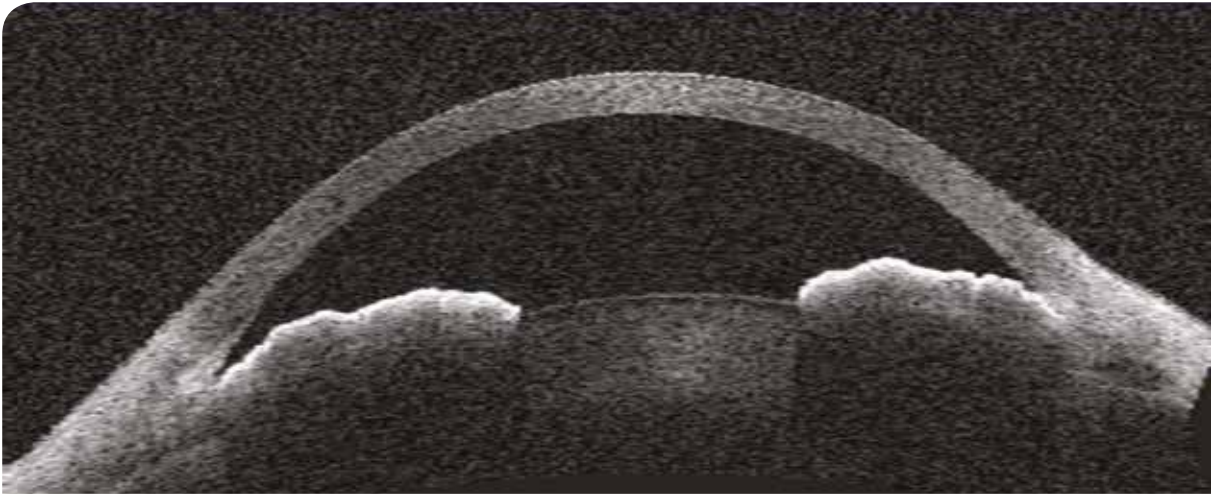


Figure 2: OCT of the anterior segment.

Multiple choice question

What complementary exam are you requesting? (one correct answer)

- A. B-mode ultrasound of the posterior segment
- B. Specular microscopy
- C. Ultrasound bio-microscopy (UBM) examination of the anterior segment
- D. Brain and orbit MRI
- E. Ocular biometry

Answer to the MCQ on page 73

A high frequency ultrasound of the anterior segment is performed (UBM):

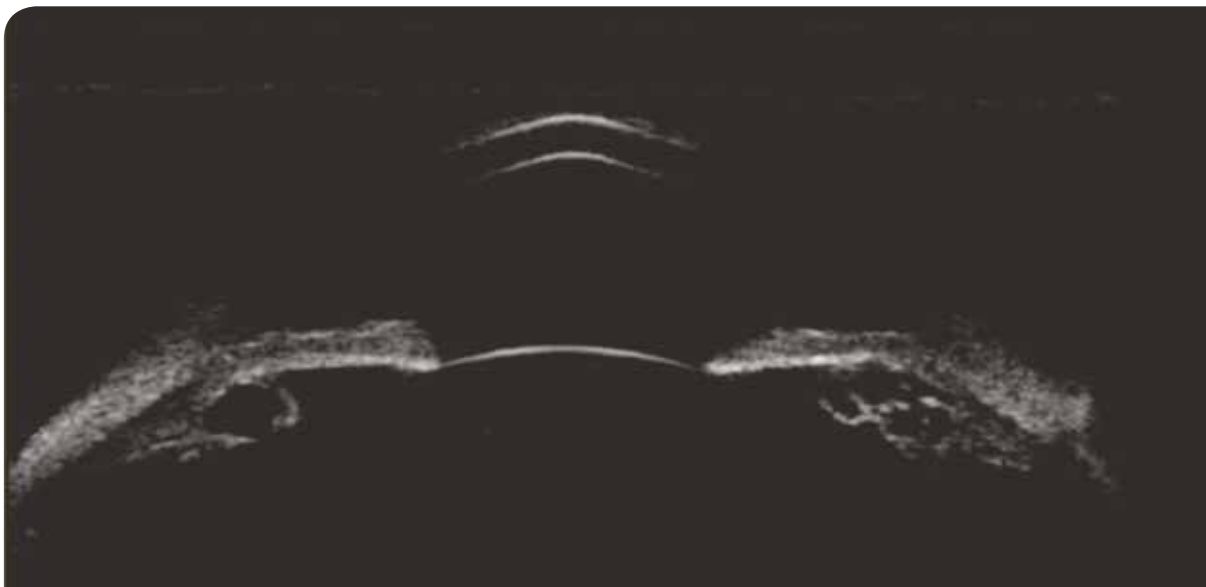


Figure 3: UBM of the anterior segment.

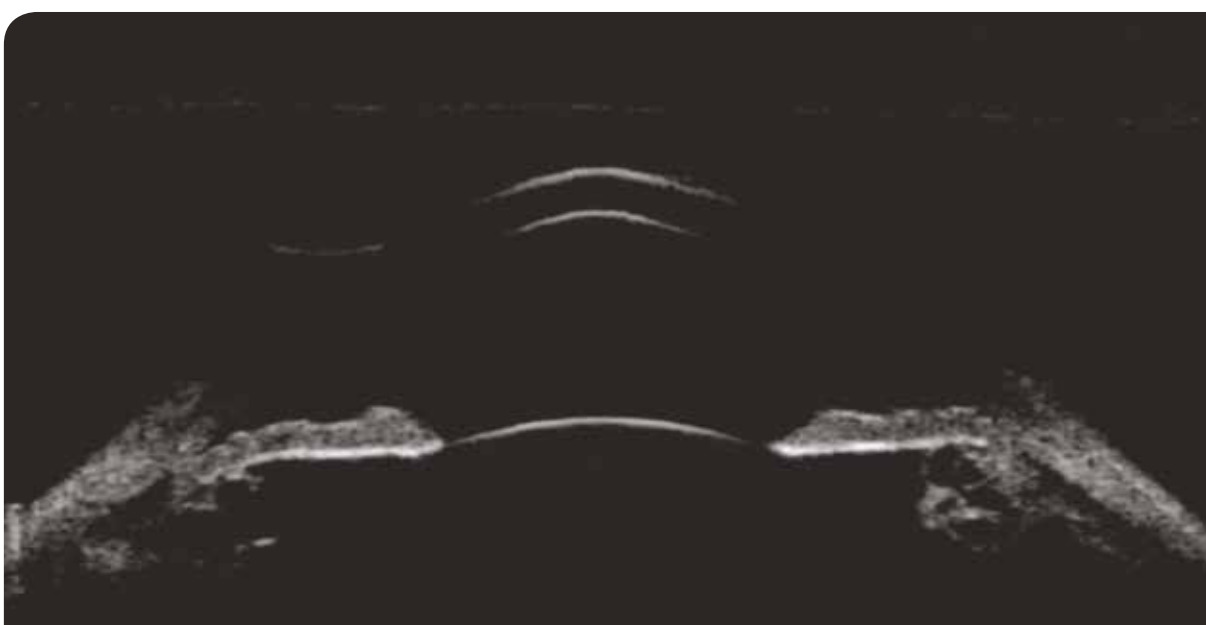


Figure 4: UBM of the anterior segment.

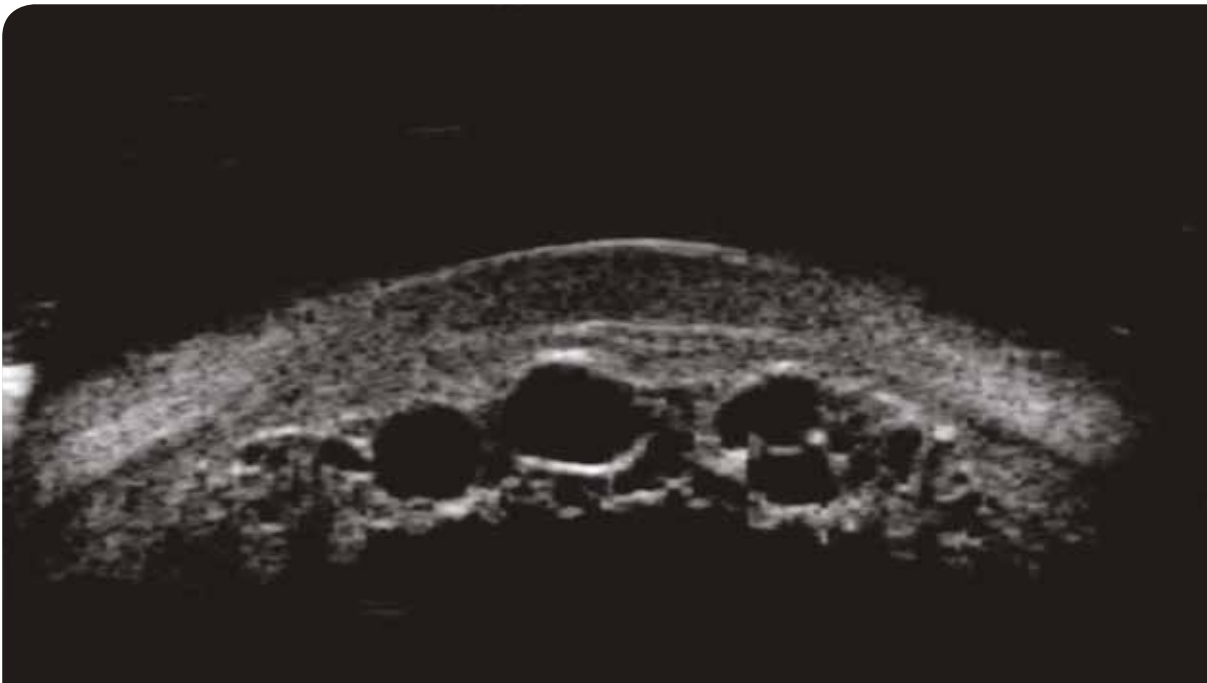


Figure 5: UBM of the anterior segment.

Multiple choice question

What is the cause of the iridocorneal angle closure? (One correct answer)

- A. Iris nevus
- B. Annular melanoma
- C. Malignant glaucoma
- D. Ciliary polycystosis
- E. Iridocorneal endothelial syndrome

Answer to the MCQ on page 73

Complete case report and answer to the question

The UBM shows a bilateral ciliary polycystosis reaching the entire circumference of the ciliary body (multiple, rounded lesions with clearly defined anechogenic area).

The cysts are developed at the expense of the pigmented epithelium of the ciliary body and sometimes of the iris and are benign.

The ciliary polycystosis is often primary, sometimes secondary to a traumatism or to repeated contacts with an implant placed in the ciliary sulcus. Involvement is most often bilateral.

As intraocular pressure is normal, regular follow-up appears acceptable. An iridotomy will probably be effective, because the cysts are numerous and developed at the expense of the entire circumference of the ciliary body⁽¹⁻⁴⁾.

An iridoplasty, by producing the retraction and a thinning of the base of the iris, can sometimes result in a limited reopening of the angle⁽⁵⁾.

In the case of glaucoma that is resistant to medical treatments, the use of transscleral or endoscopic cyclophotocoagulation has sometimes been described⁽⁶⁾.

References

1. Lois N, Shields CL, Shields JA, Mercado G. Primary cysts of the iris pigment epithelium. Clinical features and natural course in 234 patients. *Ophthalmology*. 1998; 105(10): 1879-85.
2. Shields JA, Kline MW, Augsburger JJ. Primary iris cysts: a review of the literature and report of 62 cases. *Br J Ophthalmol*. 1984; 68(3): 152-66.
3. Berkani Kitouni Z, Kitouni Y, Boukhecham D, Kherroubi R, Hartani D. [Plateau-like iris configuration secondary to multiple iridociliary cysts: case report of one family]. *J Fr Ophtalmol*. 2015; 38(3): e41-2. French.
4. Ang GS, Bochmann F, Azuara-Blanco A. Argon laser peripheral iridoplasty for plateau iris associated with iridociliary cysts: a case report. *Cases J*. 2008; 1(1): 368.
5. Crowston JG, Medeiros FA, Mosaed S, Weinreb RN. Argon laser iridoplasty in the treatment of plateau-like iris configuration as result of numerous ciliary body cysts. *Am J Ophthalmol*. 2005; 139(2): 381-3.
6. Schmalfluss TR, Picetti E, Pakter HM. Glaucoma due to ciliary body cysts and pseudoplateau iris: a systematic review of the literature. *Arq Bras Oftalmol*. 2018 Jun; 81(3): 254-261.

Answer to the MCQ on page 69: C

Answer to the MCQ on page 71: D



6

Details are in the angle

Case report

Miss A, 19-year-old, without known medical history, is referred by a colleague for an additional exam of an ocular hypertension found during a follow-up ophthalmologic examination for myopia.

Refraction is as follows:

- Right: 20/20 -3.00 (-0.25) 0° d
- Left: 20/20 -3.50 d

The pressure measured with the Noncontact tonometer was 22 mmHg in the right eye and 20 mmHg in the left.

Gonioscopy finds the same anomalies in both eyes (Figures 1 and 2).




Figure 1: Appearance of the right eye in gonioscopy at the 6 o'clock position.

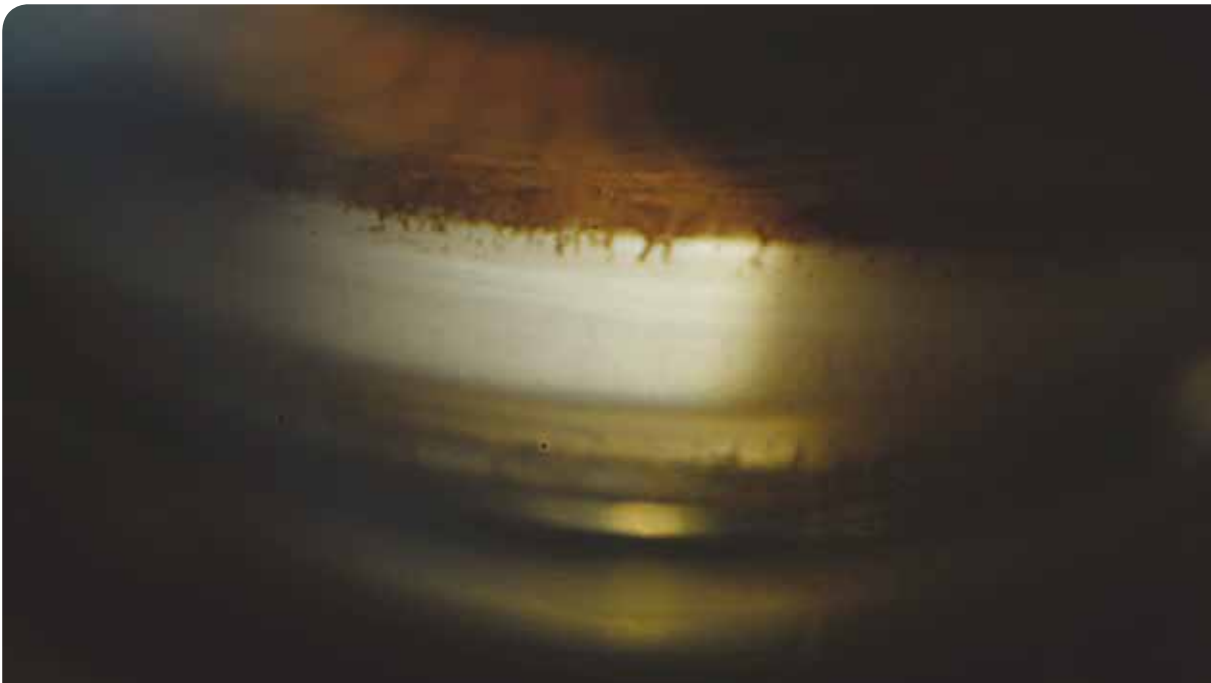

Figure 2: Appearance of the left eye in gonioscopy at the 12 o'clock position.

The examination of the eye fundus is as follows (Figures 3 and 4).

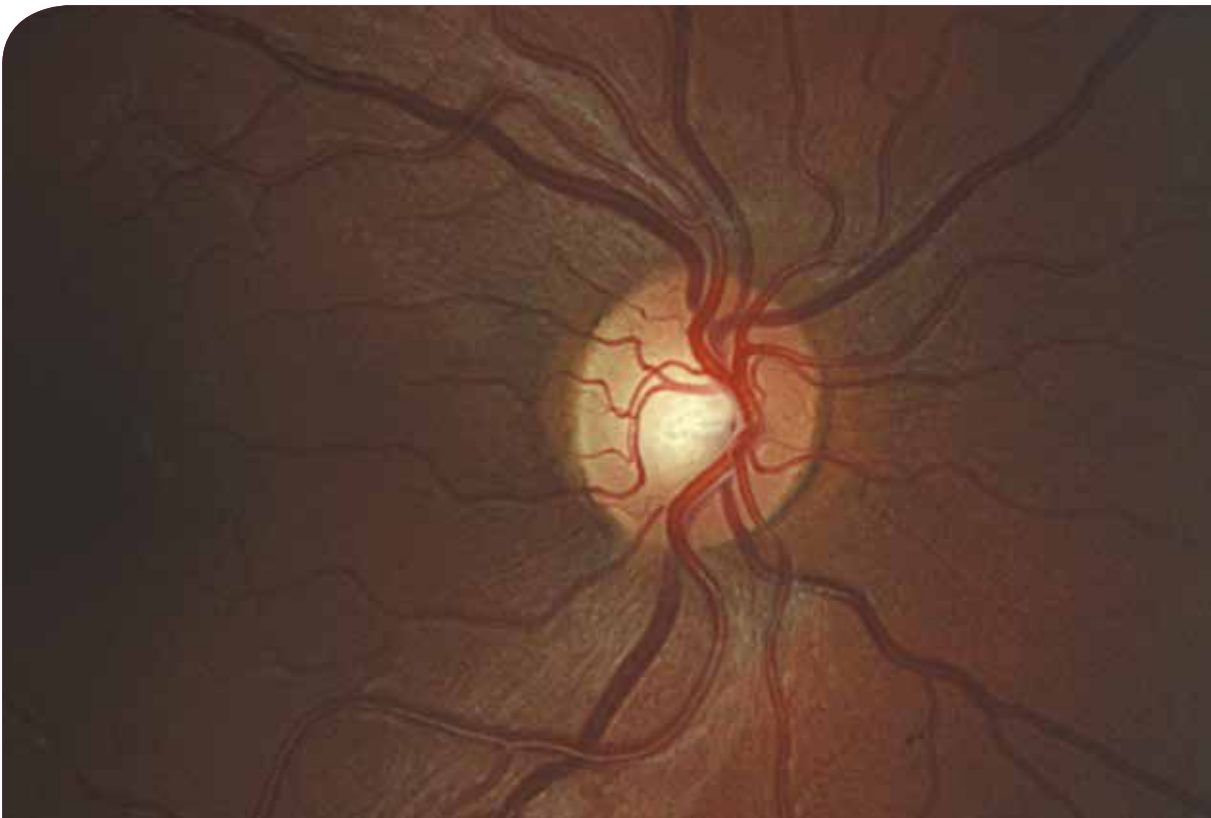


Figure 3: Right optic disc.

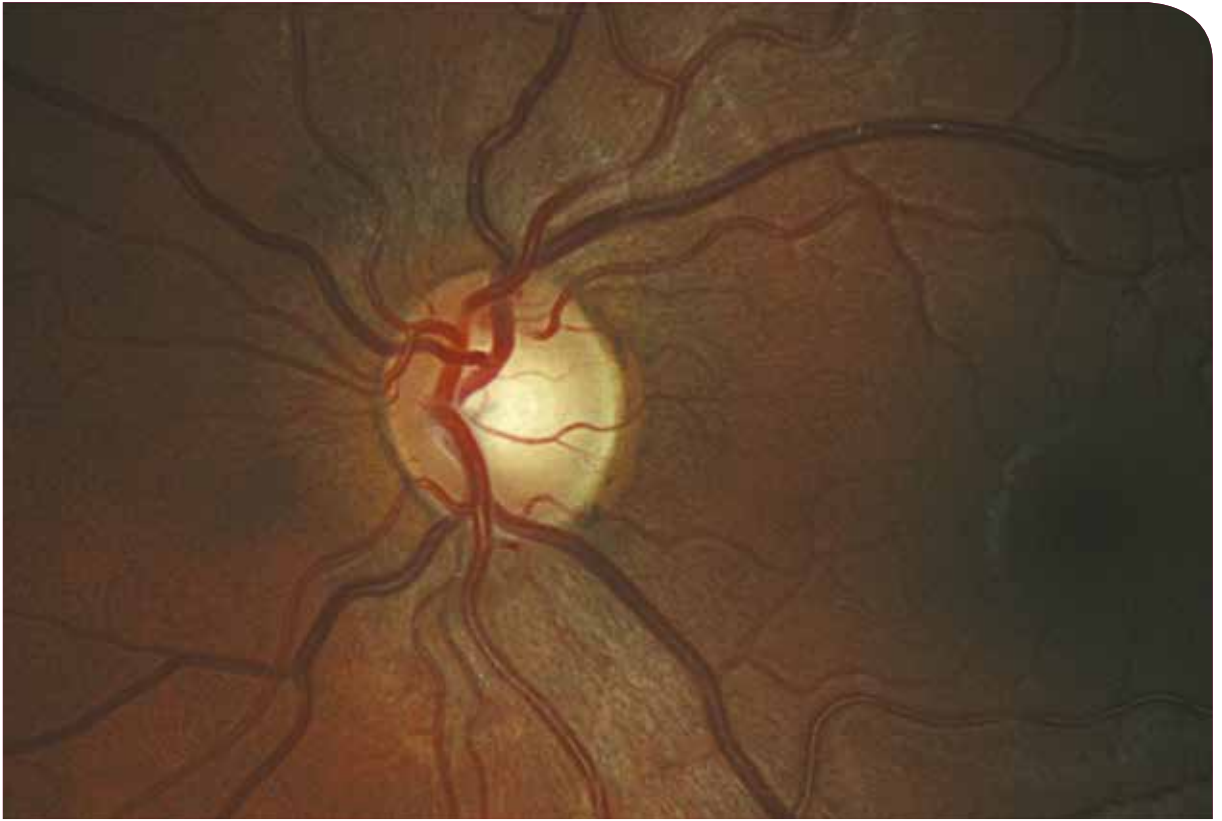

Figure 4: Right optic disc.

Multiple choice question

What is your approach to the ophthalmologic examination? (one correct answer)

- A. You look for an inflammatory episode to explain the synechiae.
- B. You suspect an Axenfeld-Rieger syndrome.
- C. They are iris processes unrelated to ocular hypertonia.
- D. These anomalies obstruct the iridocorneal angle and explain the ocular hypertension.
- E. It is a bilateral Iridocorneal endothelial syndrome (ICE syndrome).

Answer to the MCQ on page 85

The exam also includes a measurement of the pachymetry that is 620 μm on the right and 615 μm on the left.

The intraocular pressure measured again with the Goldmann tonometer is 19 mmHg in both eyes.

The retinal photographs with blue light do not reveal any loss of axonal fibers of the optic nerve (Figures 5 and 6).

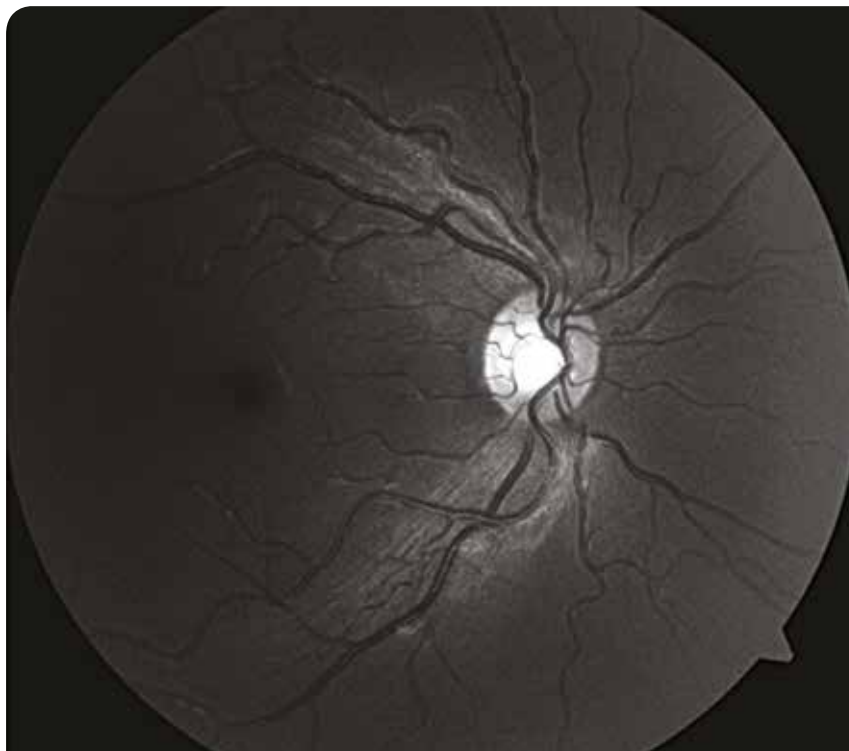

Figure 5: Image with blue light: no loss of visible fibres.

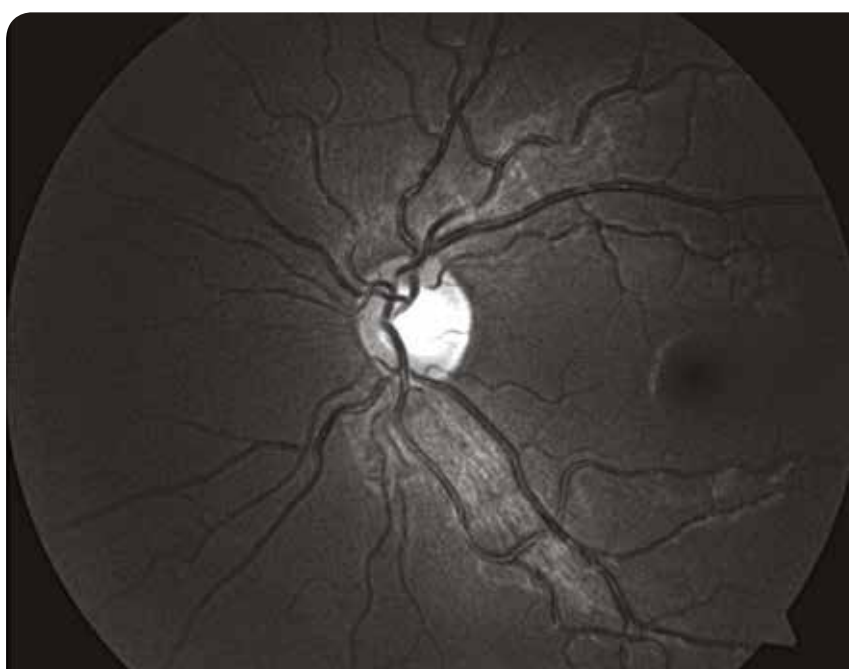


Figure 6: Image with blue light: no loss of visible fibres.

The visual fields analyzed for the first time are within normal ranges (Figures 7 ad 8) and the images of the optic nerve head and ganglion cell complex are strictly normal with large-size optic discs (Figures 9 and 10).

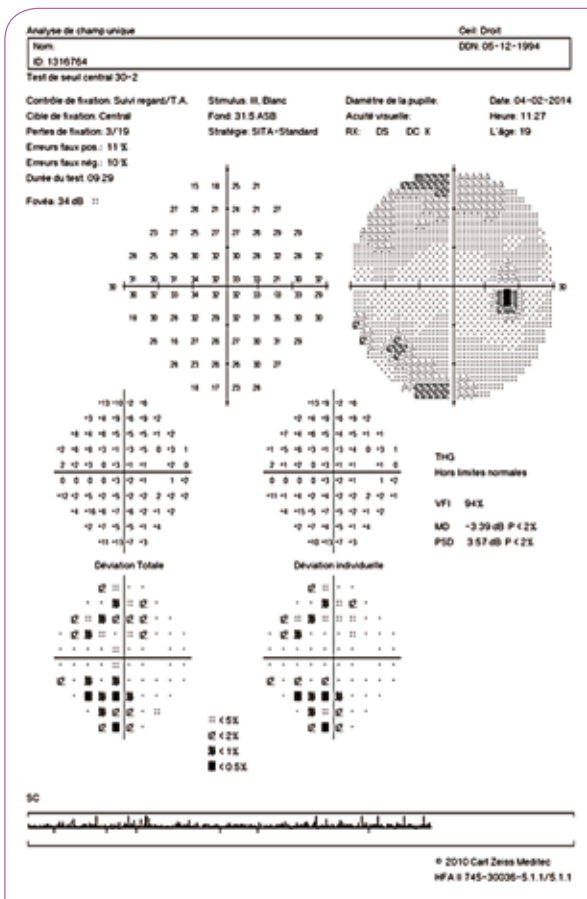


Figure 7: Normal right visual field.

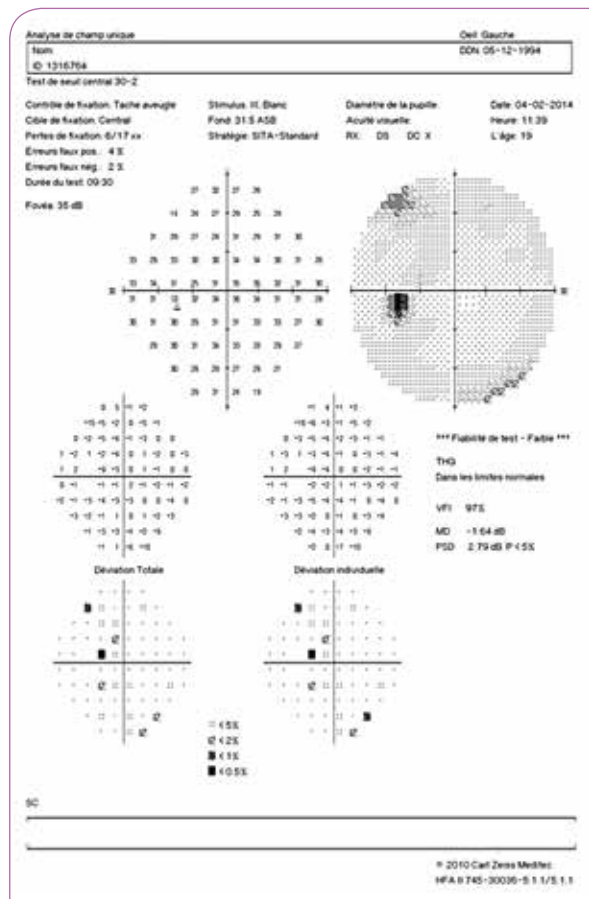


Figure 8: Normal left visual field.

Name: OD OS

ID: 1316764 Exam Date: 04/02/2014 04/02/2014 Centre Regional du Glaucome

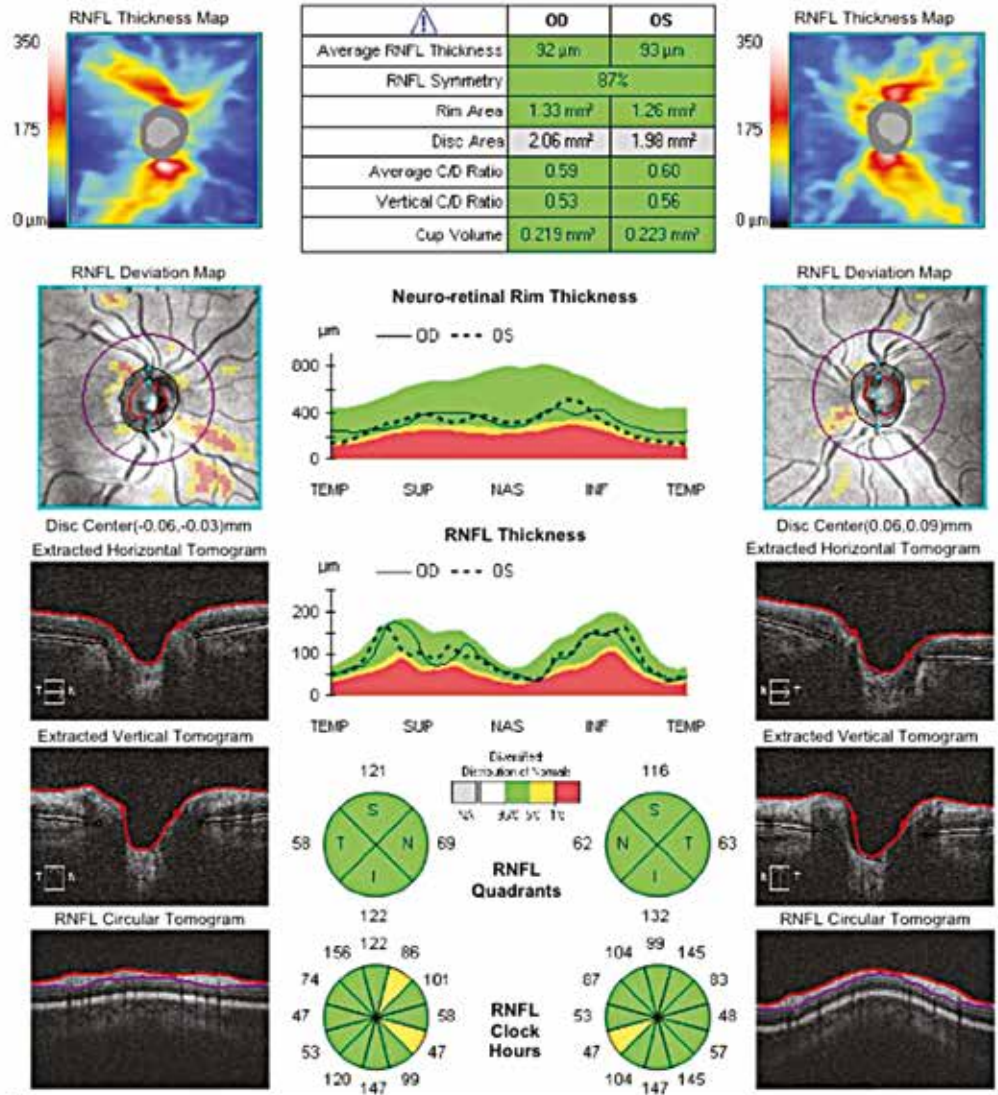
DOB: 05/12/1994 Exam Time: 13:00 13:02

Gender: Female Serial Number: 4000-8165 4000-8165

Technician: Centre Regional Glauc... Signal Strength: 8/10 8/10



ONH and RNFL OU Analysis: Optic Disc Cube 200x200 OD ● ● OS



Comments


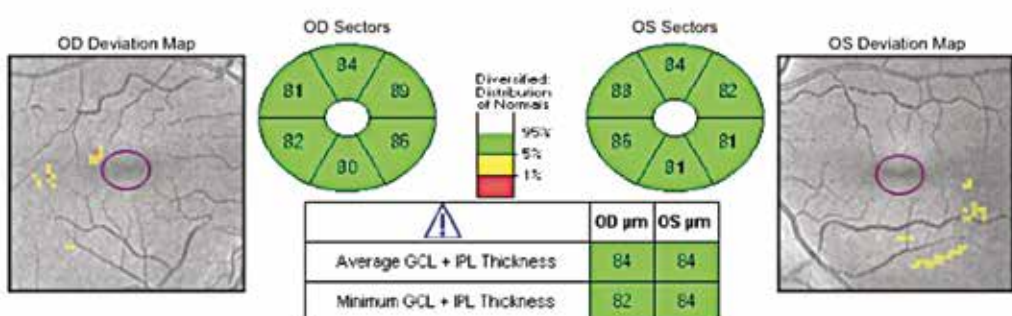
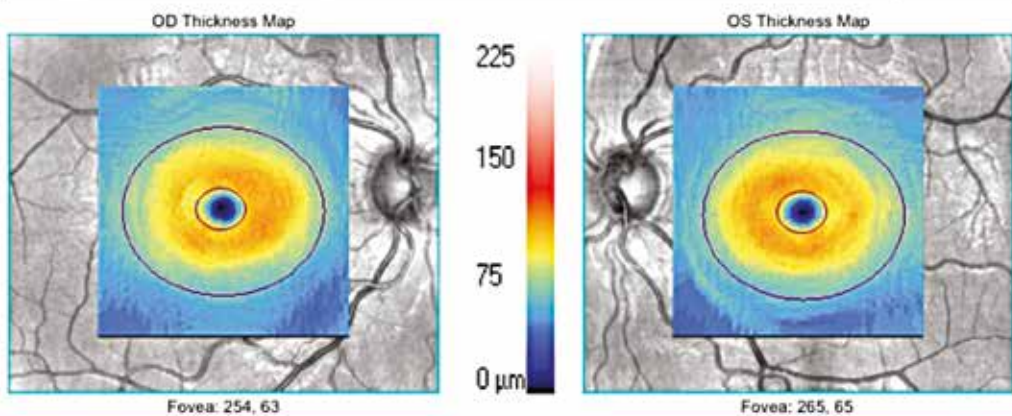
Doctor's Signature

CIRUS
SW Ver: 6.5.0.772
Copyright 2012
Carl Zeiss Medtec, Inc
All Rights Reserved
Page 1 of 1

Figure 9: OCT exam of the RNFL: within normal range.

Name: **OD OS**
 ID: 1316764 Exam Date: 04/02/2014 04/02/2014 Centre Regional du Glaucome **ZEISS**
 DOB: 05/12/1994 Exam Time: 13:00 13:02
 Gender: Female Serial Number: 4000-8165 4000-8165
 Technician: Centre Regional Glauc... Signal Strength: 8/10 9/10

Ganglion Cell OU Analysis: Macular Cube 512x128 **OD OS**



Comments _____ Doctor's Signature _____

CIRRUS
 SW Ver: 6.5.0.772
 Copyright 2012
 Carl Zeiss Meditec, Inc
 All Rights Reserved
 Page 1 of 1

Figure 10: Normal ganglion cell complex analysis.

This young patient presents an intraocular pressure modified by a high pachymetry reading.

The presence of bilateral iris trabeculae that are anomalies of angle development does not lead to ocular hypertension.

They must be recognized so as not to be led astray by other diagnoses or even start useless therapy.

The iris processes or iris trabeculae

Iris processes are very often found in normal iridocorneal angles. They are an expansion of iris tissue towards the trabecular meshwork. But they can also terminate on Schwalbe's line.

They are visible in two forms: either as thin lines of iris tissue or thicker surfaces that appear to adhere to the bottom of the angle. Their colors are often identical to the color of the iris.

They do not cause any limitation of the aqueous humor pathways.

The differential diagnosis is goniosynechia or peripheral anterior synechiae.

Dynamic gonioscopy can very often distinguish them.

References

Atlas of gonioscopy : l'angle normal : www.gonioscopy.org

Answer to the MCQ on page 79: C



7

A specific etiology

Case report

A 46-year-old male patient asks for a second opinion.

He is followed by his ophthalmologist for right unilateral ocular hypertension treated with sustained release beta blockers administered once a day.

Despite very good treatment compliance, intraocular pressure measured by his ophthalmologist is sometimes high (nearly 30 mmHg). There is no family history of glaucoma or ocular hypertension.

He recently read that ocular hypertension or glaucoma generally affect elderly patients and often both eyes and therefore wants to know the reasons for his ocular hypertension and if his treatment is adequate.

Examination shows acuity at 20/20 in both eyes with his correction. Intraocular pressure is 18 mmHg in the right and 13 mmHg in the left, under timolol 0.50% LP once daily in the morning in both eyes. A rapid exam of the anterior segment does not show any obvious anomalies.

Gonioscopic examination of the right eye is performed:

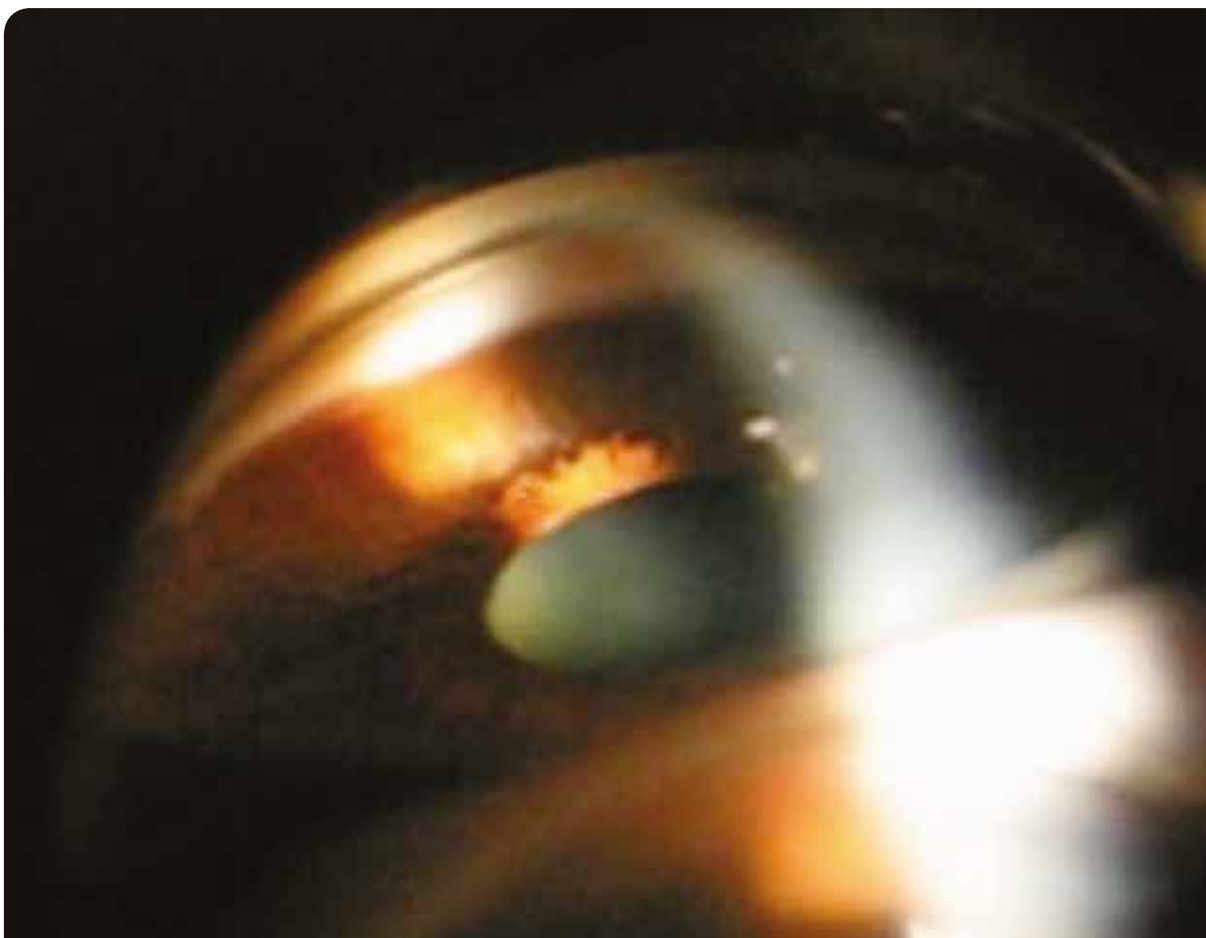


Figure 1

A high magnification of the inferior portion of the angle:



Figure 2

Multiple choice question

What situation explains his right ocular hypertension? (One correct answer)

- A. Angle recession
- B. Chronic anterior uveitis
- C. Pigmentary dispersion syndrome
- D. Iridocorneal endothelial syndrome
- E. Plateau iris syndrome

Answer to the MCQ on page 99

Complete case report and answer to the question

A closer examination of the anterior segment shows a circumferential *spoke-like iris transillumination* defects (Figure 3).

Likewise, an examination at high magnification of the corneal endothelium shows the presence of a vertical retrocorneal deposit of pigments (Krukenberg's spindle, Figure 4), confirming the diagnosis of bilateral pigment dispersion syndrome dominant in the right and complicated by ocular hypertension in the right eye.

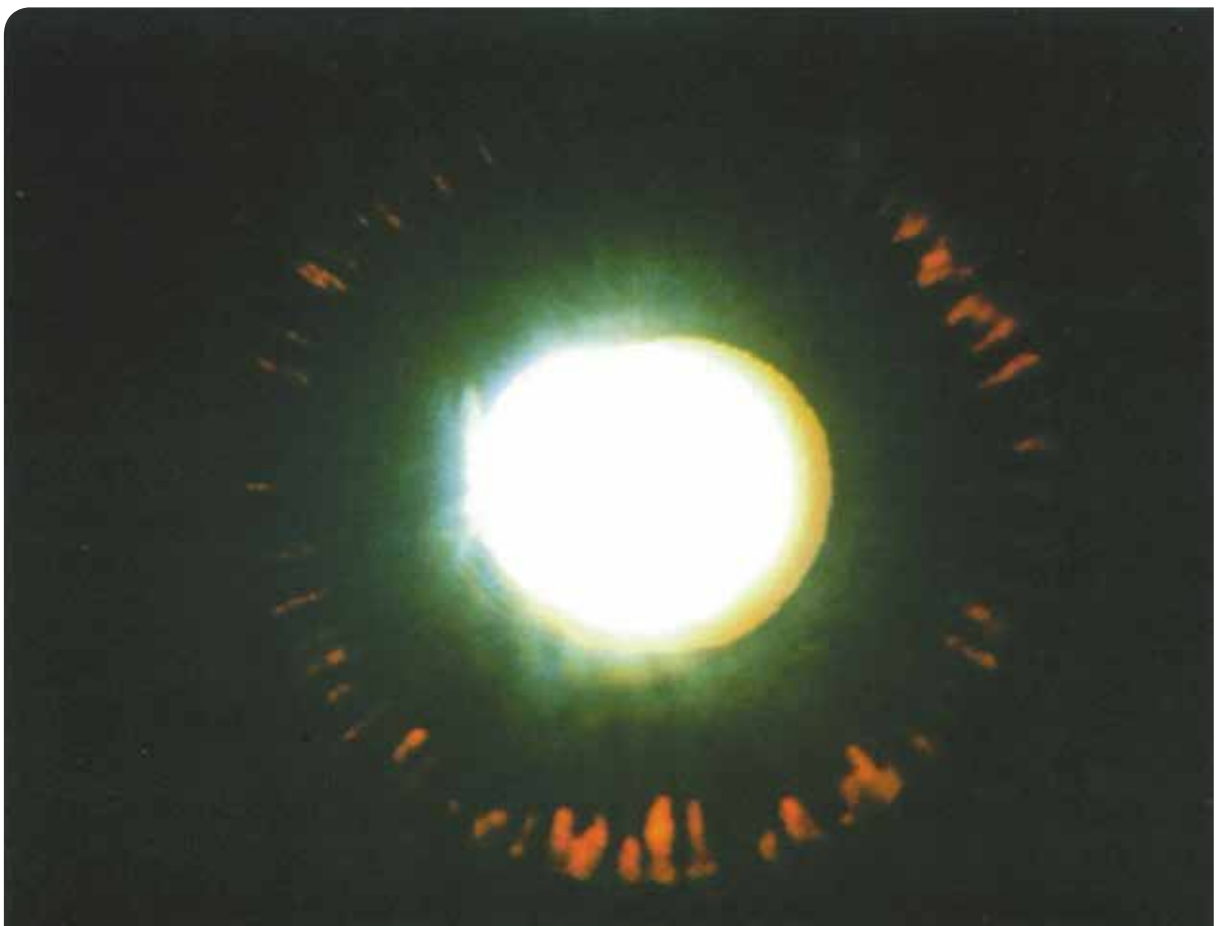


Figure 3: Transillumination of the right eye.

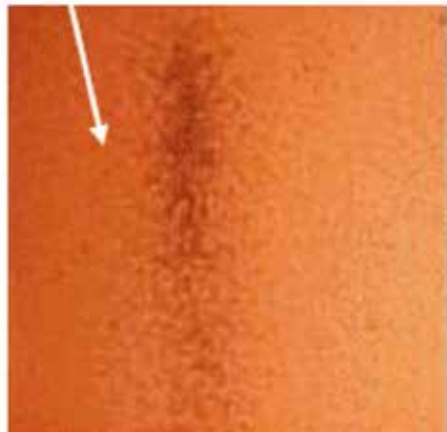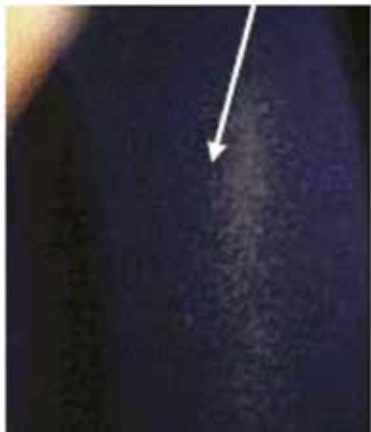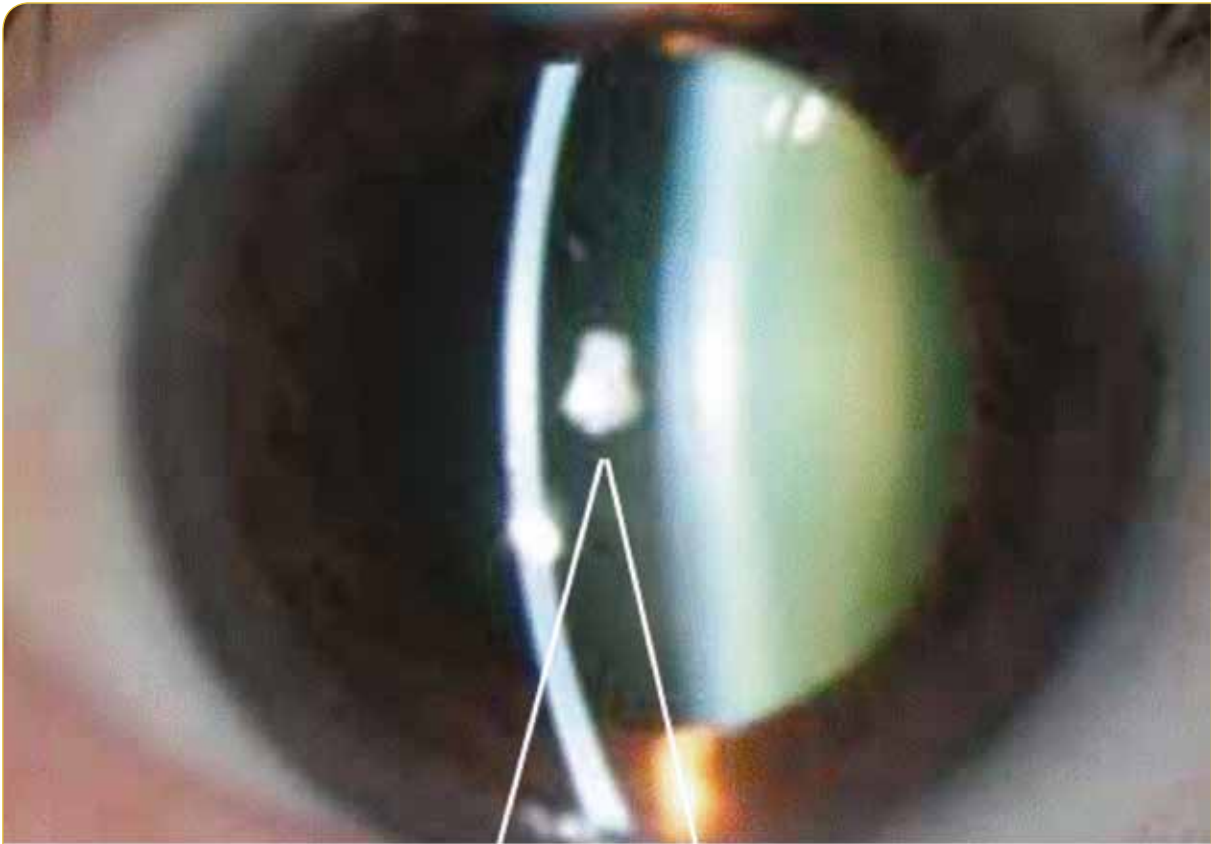


Figure 4: Krukenberg's spindle.

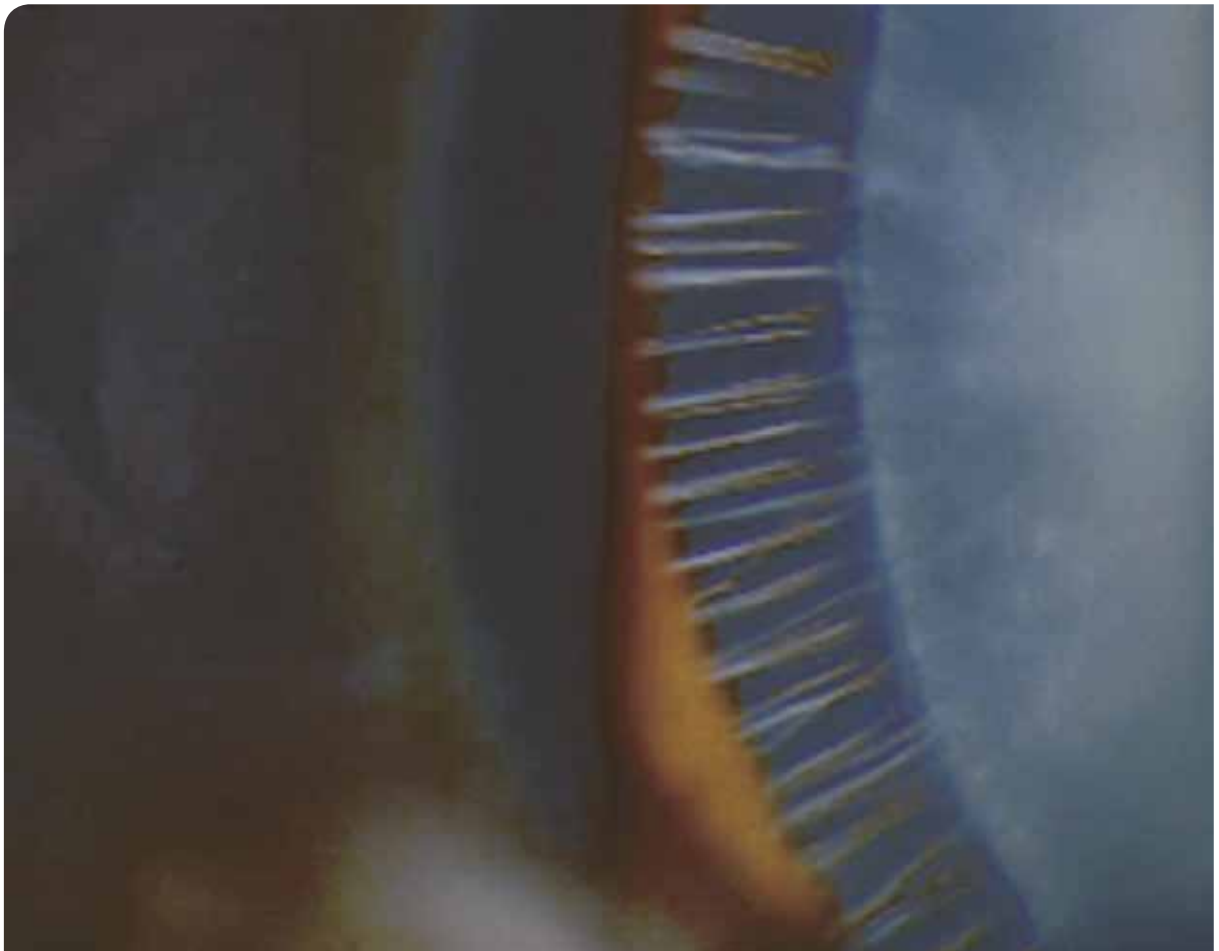

Figure 5: Pigment deposits on the zonules.

After discussing with the patient, he complains of episodes of pain and perception of colored halos when practicing endurance sports.

Measuring his intraocular pressure after a jogging session is therefore suggested. Results are 40 mmHg in the right and 20 mmHg in the left eye.



Figure 6: Pigmented Tyndall effect after sports activity.

Examination of the anterior segment shows a significant pigmented Tyndall effect on the right (Figure 6) and discreet on the left.

Images of the anterior segment show an reverse pupillary block with iris recurvatum (concave iris) resulting in apposition of the iris against the zonular fibers and very likely in an erosion of the pigmented epithelium during pupillary movements (Figures 7 and 8).

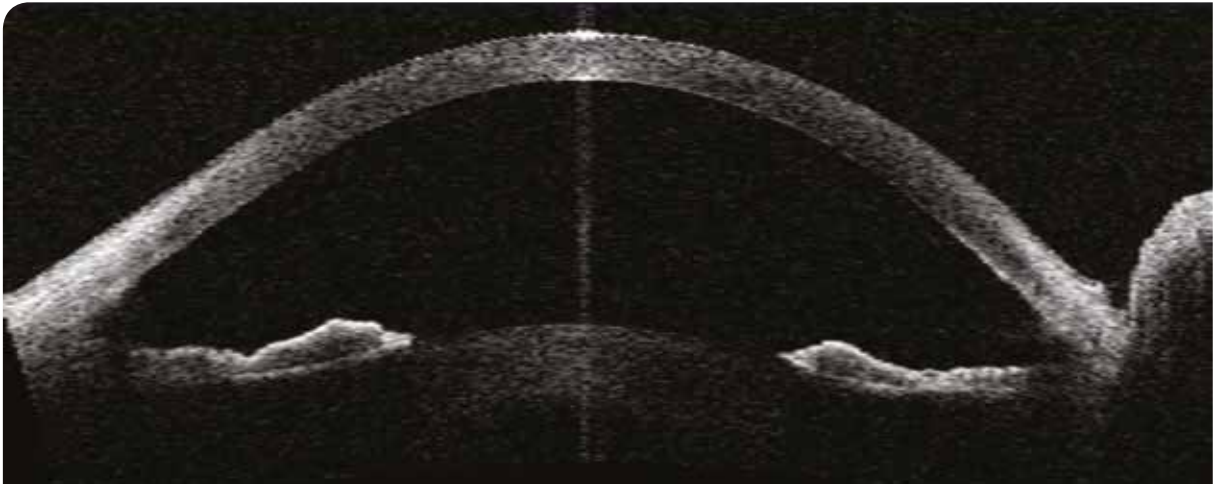


Figure 7: OCT before iridotomy.

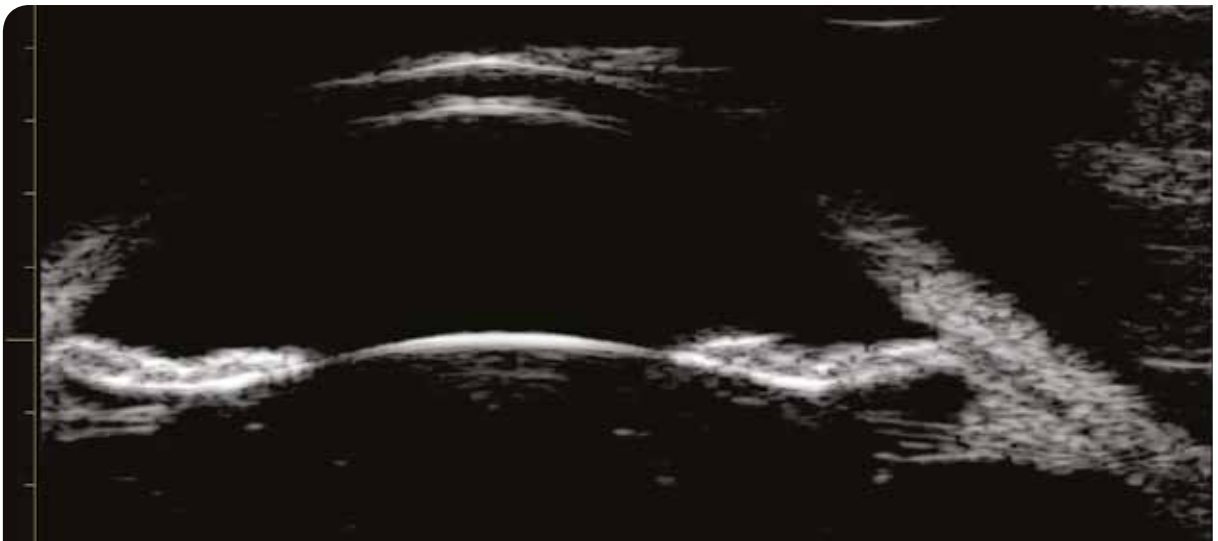


Figure 8: UBM before iridotomy.

Laser iridotomy is performed on the right pigment dispersion syndrome associated with ocular hypertension but without glaucomatous neuropathy.

This allows complete disappearance of the anatomical aspect (Figure 9). Intraocular pressure remains close to 20 mmHg on the right, but the patients no longer complains of symptoms during sports activity.

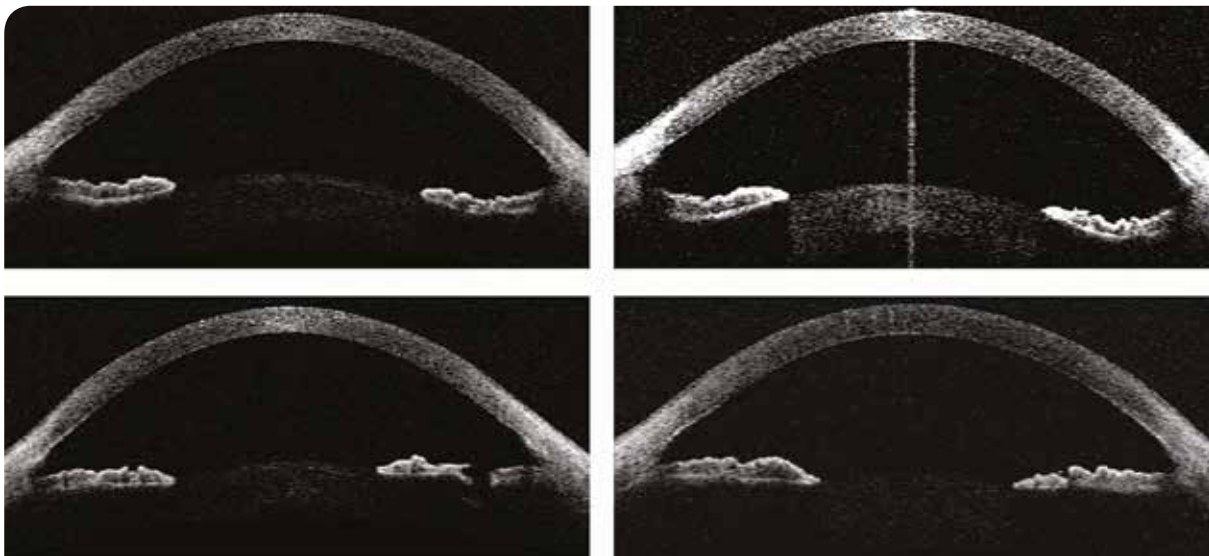


Figure 9: Effect of iridotomy on the configuration of the anterior segment (high before iridotomy, low after iridotomy).

Summary of the topic discussed in the case

Pigment dispersion syndrome is an anatomico-clinical entity characterized by a release of the components of the pigment epithelium of the iris that are then transported by aqueous humor and deposit on different anterior segment structures, especially in the trabecular meshwork ^(1,2).

The progressive accumulation of pigment granules can lead to an increase of intraocular pressure (IOP) then, in the event of subsequent glaucomatous optic neuropathy, a particular form of open-angle glaucoma called pigment glaucoma.

Pigment dispersion syndrome, complicated or not by glaucoma, mainly affects young male adults with myopia ⁽³⁾.

The release of pigment is linked to a particular anatomical configuration of the iris: a concavity of the iris leads to close contact between the posterior surface of the iris and the anterior surface of the lens and anterior zonular fibers.

During the variations in pupil size, especially in mydriasis, zonular fibers and the lens erode the pigment epithelium, resulting in the release of pigments. The accumulation of pigments in the trabecular meshwork probably reduces the drainage ability of aqueous humor and causes an increase in IOP.

Pigment dispersion is generally bilateral. It is often discovered accidentally when finding pigment deposits on the anterior segment structures (Figure 10) ⁽⁴⁾.

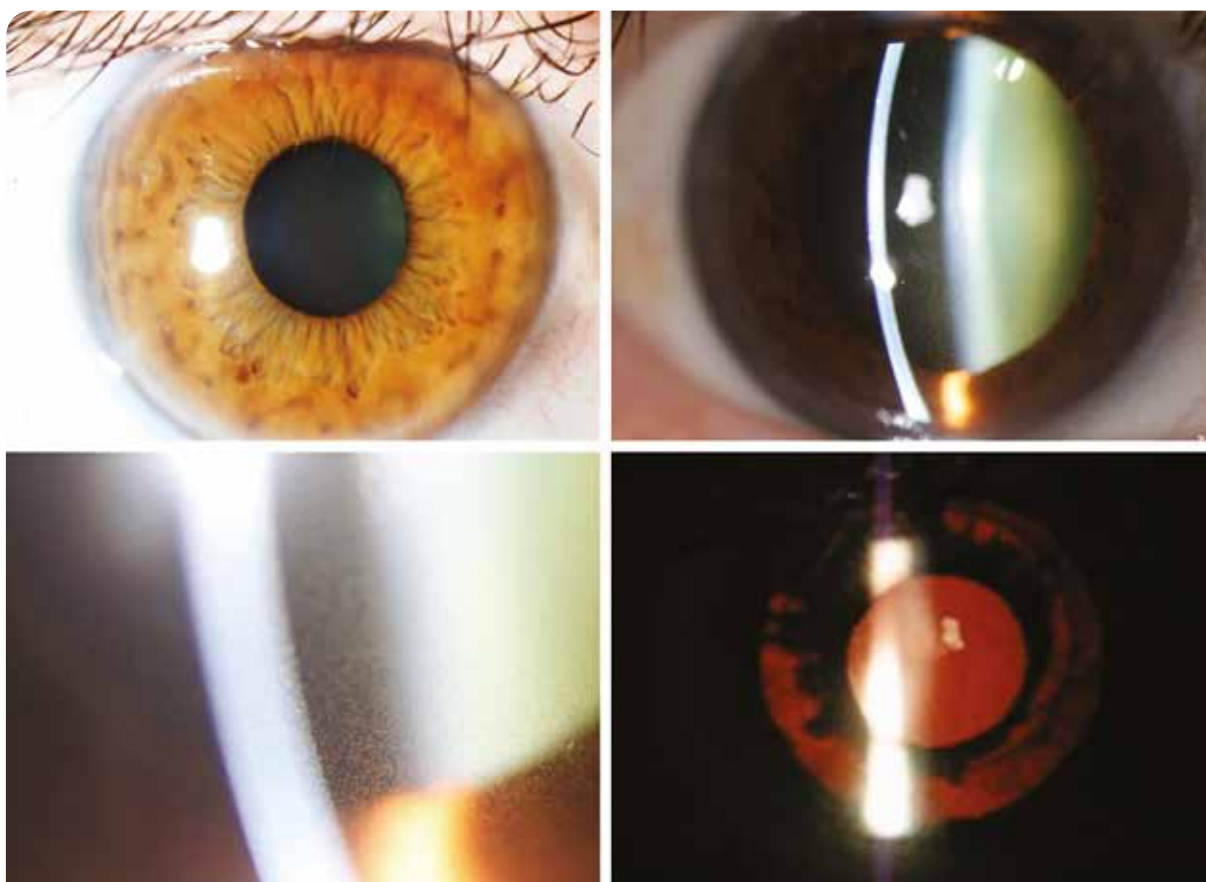


Figure 10: Figure 10: Alternance of pigmented areas and atrophic areas (upper left). Release of pigments after pupillary dilation (upper right). Pigmented Tyndall effect at high magnification (lower left). Transilluminable fields (lower right).

The vertical accumulation of pigments on the corneal epithelium constitutes the structures called Krukenberg's spindle.

Pigmented Tyndall can sometimes be observed, especially after pupillary dilation. Atrophy of the pigment epithelium results in the formation of transilluminable defects of the iris that often take the form called circumferential *spoke-like iris transillumination* defects. The gonioscopic examination enables the visualization of a concave peripheral iris associated with a wide-open iridocorneal angle (Figure 11).

A densely pigmented band, anterior to the scleral spur capable of extending to Schwalbe's ring is very characteristic of pigment dispersion syndrome.

An accumulation of pigments called Scheie's line can also be observed in the anterior crystalloid and zonular fibers.

In some patients, pigment dispersion can be discovered during very high symptomatic increases of IOP.




Figure 11: Iris concavity (top). Pigmented band in gonioscopy (bottom left). Pigments on the zonular fibers and the anterior hyaloid membrane (bottom right).

Optical or ultrasound imaging of the anterior segment can clearly visualize iris concavity and its apposition on the anterior surface of the lens and zonules (Figures 12 and 13) ^(5,6).

This anatomical configuration could according to certain authors be linked to an inversion of the pressure gradient between the posterior and anterior chambers and thus create a pupillary block situation.

Intermittent passage of aqueous humor between the lens and an abnormally mobile iris that would play the role of a valve could explain this possibility of temporary inversion of the natural pressure gradient between the posterior and anterior chambers.

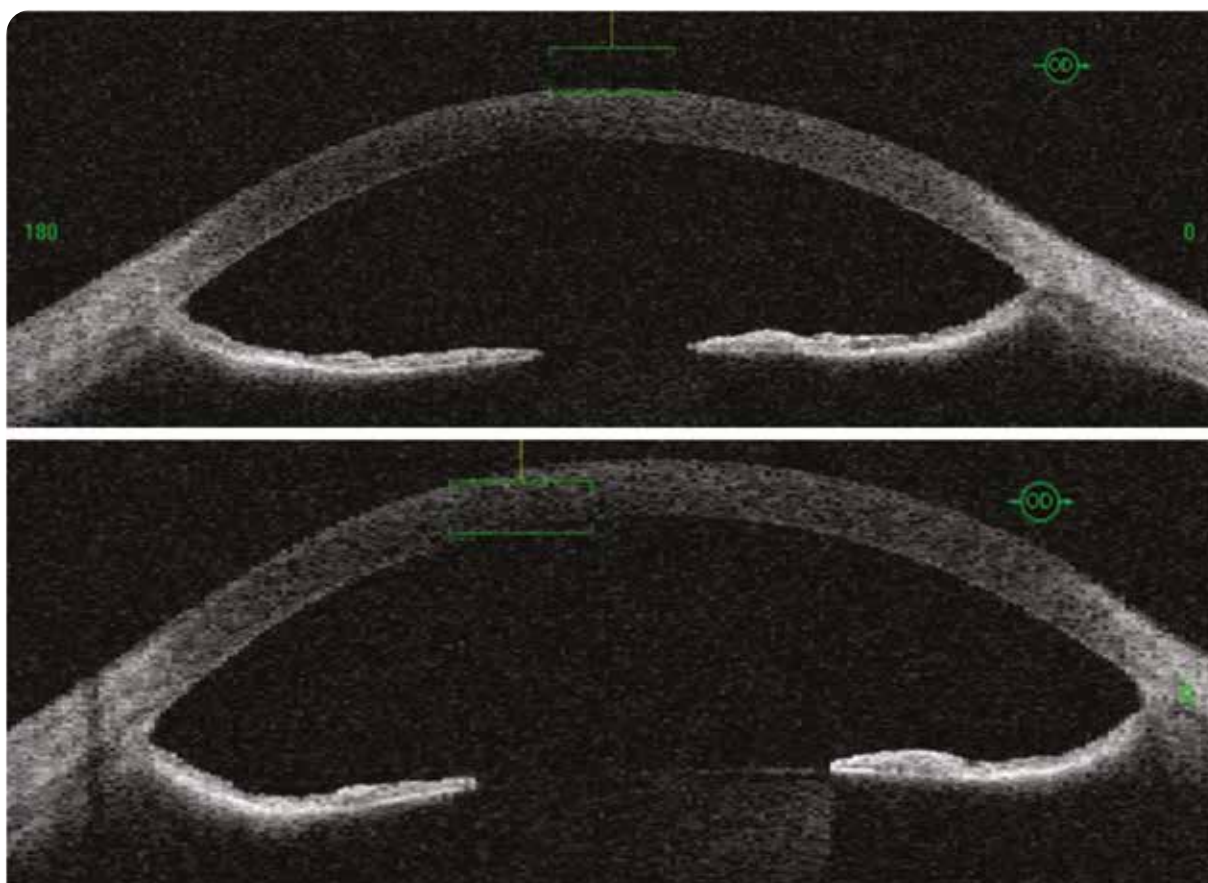


Figure 12: Cross-sections of the anterior segment in optical coherence tomography (OCT): apposition of the iris on the anterior surface of the lens before (top) and after (bottom) pupillary dilation.

Without an increase of IOP, normal follow-up can be performed⁽²⁾.

In the case of pigment dispersion complicated by ocular hypertension, performance of peripheral iridotomy can often reduce iris concavity, probably through equalization of pressure between the posterior and anterior chambers ^(7,8).

Standard antiglaucomatous eye drops can be used to reduce IOP. Pilocarpine has the benefit of reducing iris movements and induce a relative pupillary block distancing the iris from the zonules, but is generally poorly tolerated due to induced miosis and myopia.

In the case of inefficacy or associated glaucoma, laser trabeculoplasty or filtration surgery can be considered.

It should be noted that laser trabeculoplasty, selective or not, is generally effective in patients with *Pigmentary* glaucoma but can be followed by significant pressure peaks difficult to normalize.

Therefore, adaptation of the level of energy and number of impacts must be done.

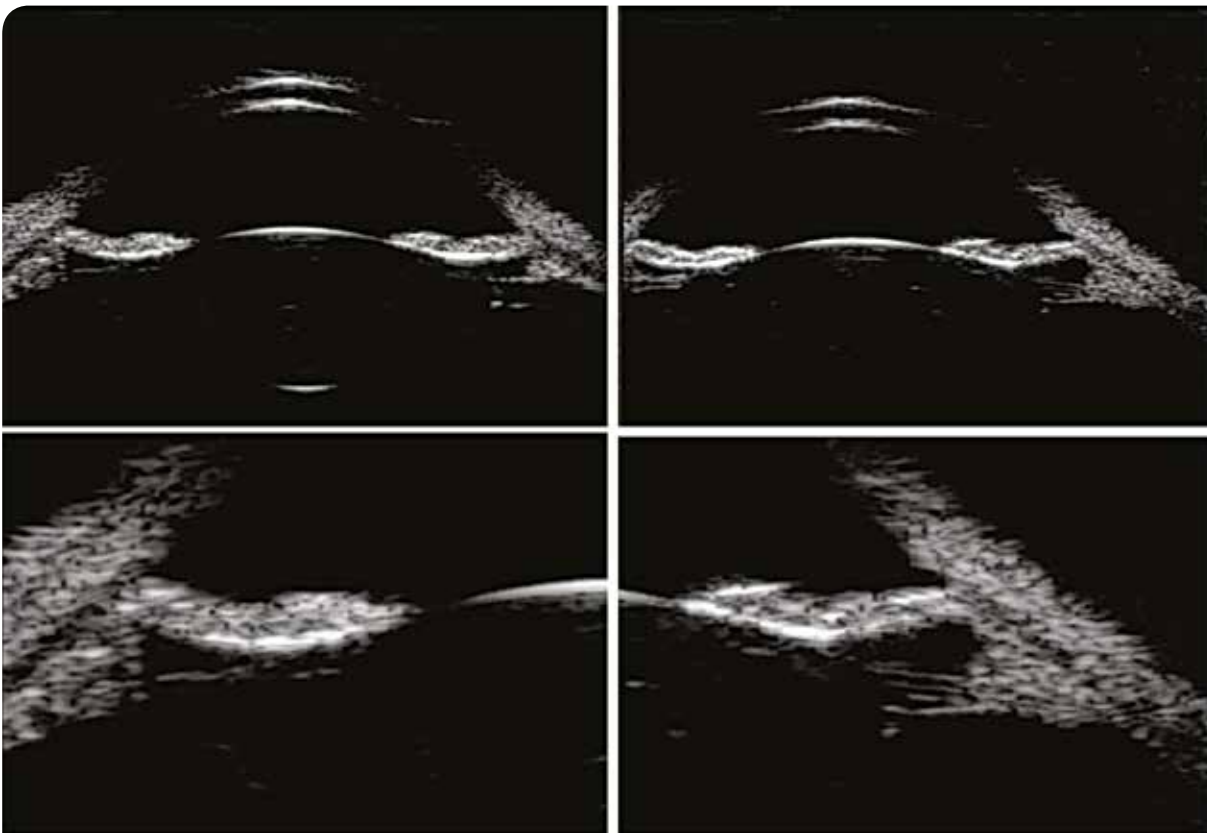


Figure 13: Cross-sections of the anterior segment with ultrasound biomicroscopy (UBM Aviso 25 MHz): apposition of the iris and anterior surface of the lens (top) and pigment deposits on zonular fibres (bottom).

References

1. Aptel F, Beccat S, Fortoul V, Denis P. Biometric analysis of pigment dispersion syndrome using anterior segment optical coherence tomography. *Ophthalmology*. 2011 Aug; 118(8): 1563-70.
2. Niyadurupola N, Broadway DC. Pigment dispersion syndrome and pigmentary glaucoma--a major review. *Clin Experiment Ophthalmol*. 2008 Dec; 36(9): 868-82.
3. Lehto I, Vesti E. Diagnosis and management of pigmentary glaucoma. *Curr Opin Ophthalmol*. 1998 Apr; 9(2): 61-4.
4. Ritch R. Pigment dispersion syndrome. *Am J Ophthalmol*. 1998 Sep; 126(3): 442-5.
5. Mora P, Sangermani C, Ghiradini S, Carta A, Ungaro N, Gandolfi SA. Ultrasound Biomicroscopy and Iris Pigment Dispersion: a Case-Control Study. *Br J Ophthalmol*. 2009 Oct 12.
6. Laemmer R, Mardin CY, Juenemann AG. Visualization of changes of the iris configuration after peripheral laser iridotomy in primary melanin dispersion syndrome using optical coherence tomography. *J Glaucoma*. 2008 Oct-Nov; 17(7): 569-70.
7. Kuchle M, Nguyen NX, Mardin CY, Naumann GO. Effect of neodymium:YAG laser iridotomy on number of aqueous melanin granules in primary pigment dispersion syndrome. *Graefes Arch Clin Exp Ophthalmol*. 2001 Jul; 239(6): 411-5.
8. Gandolfi SA, Vecchi M. Effect of a YAG laser iridotomy on intraocular pressure in pigment dispersion syndrome. *Ophthalmology*. 1996 Oct; 103(10): 1693-5

Answer to the MCQ on page 89: C



8

Not a good mix

Case report

A 58-year-old male is referred for management of acute hypertension that occurred the day after an intravitreal injection of triamcinolone acetonide.

He has a past history of high myopia (approximately -12 diopters in both eyes) corrected during a cataract operation two year before. Three months before that, he developed a central retinal vein occlusion in the right eye complicated by a macular edema.

His visual acuity was 20/50 Pa4 in the right eye and 20/25 Pa2 in the left eye with correction in both eyes and an intraocular pressure of 18 mmHg in both eyes before he had the injection.

The day after the injection, right eye pressure is 50 mmHg, visual acuity 20/60 Pa4 and the patient complains of mild pain in the right eye.

The patient is examined with a slit lamp:

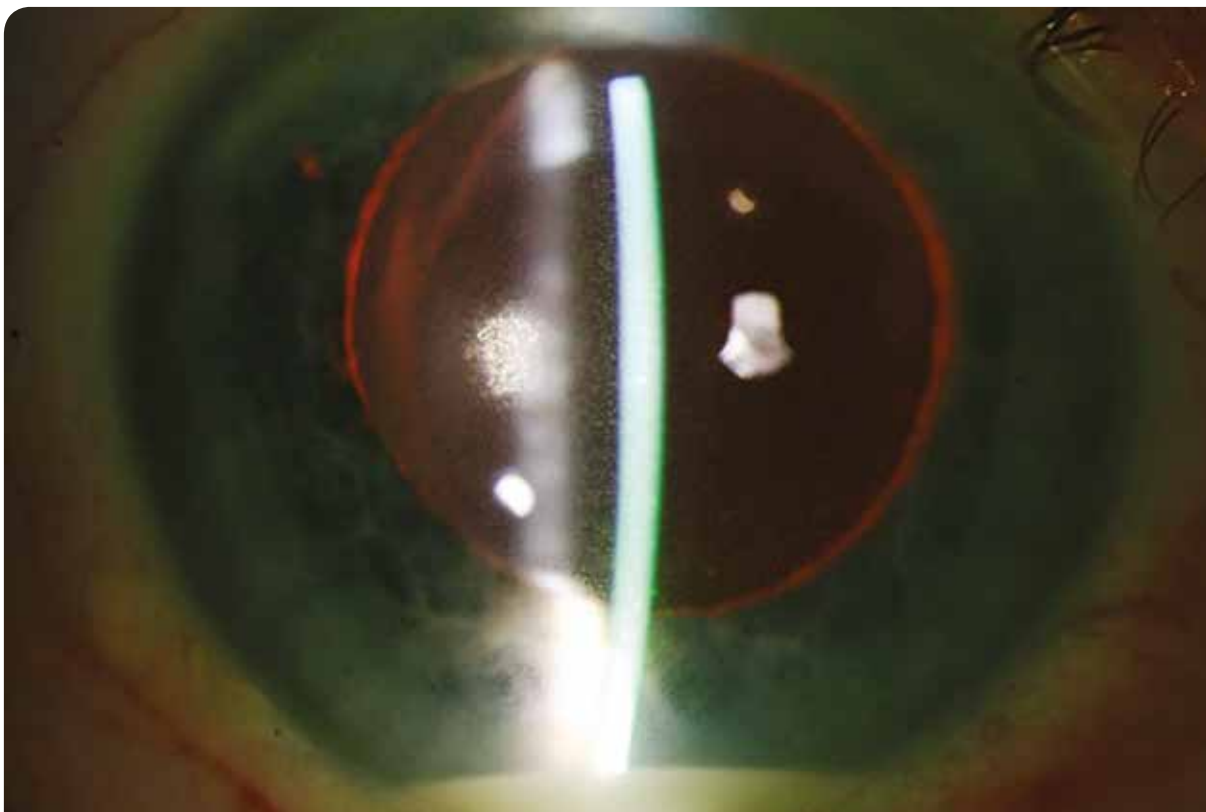


Figure 1: Slit lamp test of the anterior chamber.

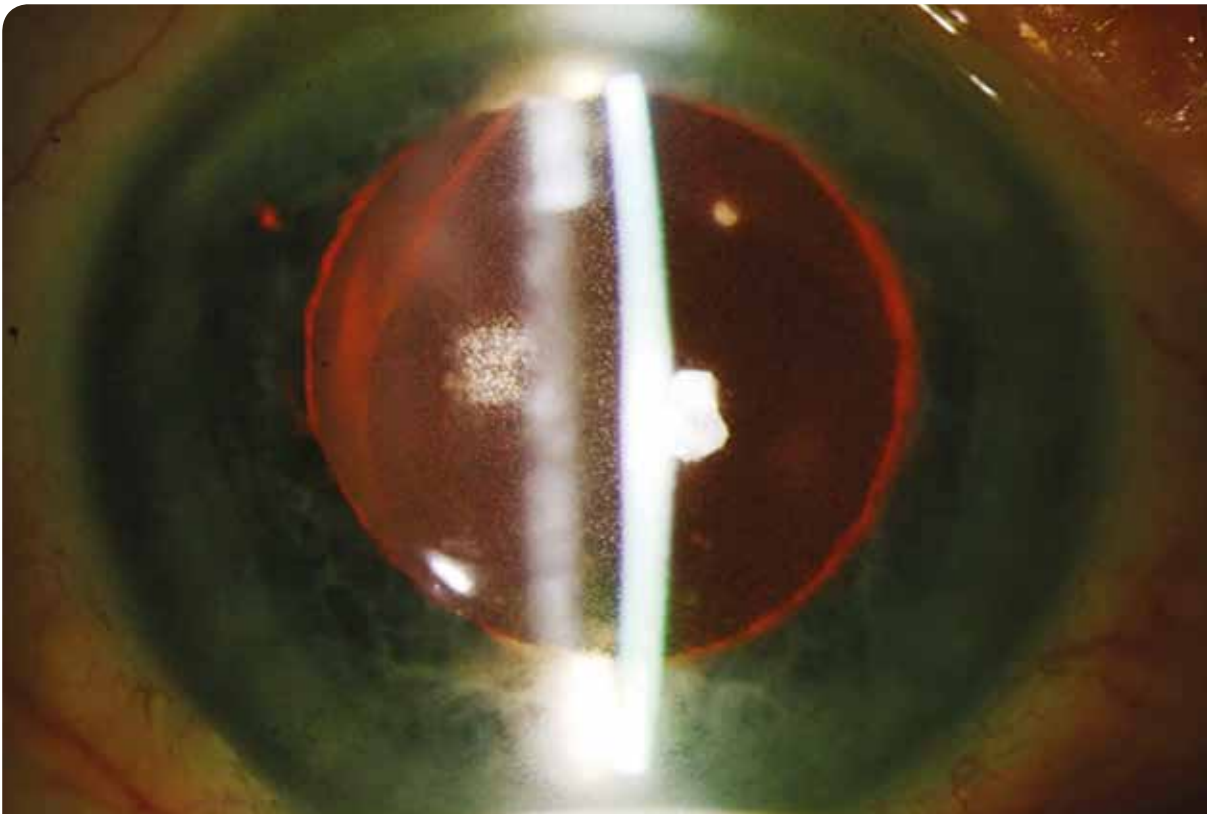


Figure 2: Pupillary reflex.

Multiple choice question

What is the most likely cause of acute hypertension? (one correct answer)

- A. Acute endophthalmitis secondary to the intravitreal injection
- B. Undetected glaucoma in a highly myopic patient
- C. Trabecular obstruction by triamcinolone acetonide crystals
- D. 90-day neovascular glaucoma
- E. Acute anterior uveitis

Answer to the MCQ on page 109

Complete case report and answer to the question

The examination of the anterior segment shows a Tyndall effect probably due to triamcinolone acetonide crystal suspensions, as well as a sedimentation of these crystals in the inferior section of the anterior chamber.

The eye is not red and the cornea is transparent. There is no cyclitic membrane and the intraocular implant is free of deposits. The pupillary reflex is preserved.

Examination of fundus after dilation finds triamcinolone acetonide crystal suspensions in the vitreous.

Nevertheless, the retina is easily visible without anomalies other than areas of myopic chorioretinal atrophy.

There are therefore no signs suggestive of acute endophthalmitis after IVT and conclusion is a ocular hypertension related to the flow of steroid crystals in the anterior chamber causing the obstruction of the trabecular meshwork.

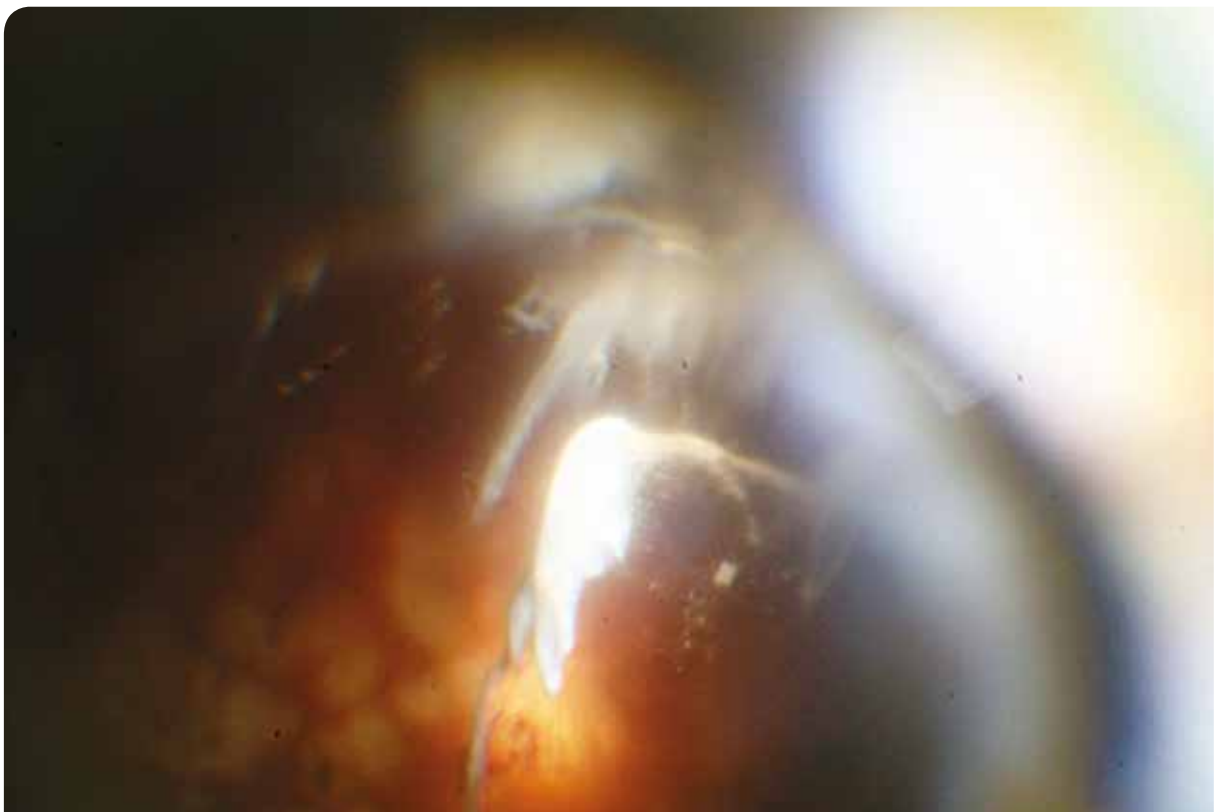

Figure 3: Crystal suspension in the vitreous.

The administration of three IOP lowering eye drops (beta-blockers, alpha-agonists and carbonic anhydrase inhibitors) combined with oral acetazolamide normalizes the IOP.

The treatment is progressively reduced and 10 days later the IOP is 16 mmHg with topical beta-blockers alone.

The patient is referred back to you two months later for the progressive reappearance of hypertension in the right eye. During the consultation, the IOP is 30 mmHg in the right eye under a fixed-combination of prostaglandins and beta-blockers, and 15 in the left without treatment.

The anterior segment is quiet.

The iridocorneal angle is open without visible neovessels.

Examination of the fundus does not show macular edema.

A selective trabeculoplasty is scheduled and subsequent injections of corticosteroids contraindicated.




Figure 4: Open iridocorneal angle.

Summary of the topic discussed in the case

1. Mechanism of steroid-induced hypertension

Different mechanisms can be involved in the onset of hypertension after intraocular or periocular administration of corticosteroids. The kinetics of the increase of IOP can identify the mechanism involved.

Hypertension immediately after an intravitreal injection: injection of given liquid or solid volume into a closed organ and bounded by poorly expandable walls causes an immediate, significant and transitory increase of IOP.

This pressure increase is independent of the product injected and dependent on^(1,2):

- the volume injected (less when the volume is 50 μ L rather than 100 μ L),
- the volume of the eyeball (more for small eyes and vice-versa),
- the biomechanical properties of the eye walls (more in the case of high scleral rigidity, elderly subjects),
- a reflux (less in the case of a reflux),
- the size of the needle used (more with a small needle),
- the pressure before injection (the higher the IOP before injection, the greater the increase),
- on the status of the eye (according to some studies the risk is higher in the case of a pre-existing glaucoma, regardless of the pressure level before injection).

Finally, the obstruction of the trabecular meshwork by triamcinolone crystals under certain conditions can cause a delayed and often significant increase of IOP (in the following hours or days after the injection).

The intravitreal administration does not prevent this hypertension due to the frequent diffusion of crystals in the anterior chamber. A whitish deposit is visible in the iridocorneal angle.

Retarded ocular hypertension: Corticosteroids, especially dexamethasone, cause an increase of the volume of the extracellular matrix in the trabecular meshwork and a decrease in the size of the areas allowing the drainage of aqueous humor. The mechanisms leading to an increase of the volume of the extracellular matrix are numerous and complex and involve a hyperhydration of the glycosaminoglycans of the extracellular matrix of the trabecular meshwork and an inhibition of the metalloproteinases degrading certain molecules of the extracellular matrix.

2. Frequency and risk factors of steroid-induced hypertension

Frequency:

Pressure increase immediately after an intravitreal injection in the absence of a significant reflux of the product, is quasi-continuous.

Studies report an increase of IOP at values over 30 or 35 mmHg in approximately 80% of cases after the injection of a volume of 50 μL ^(1,3). The maximum IOP is obtained just after injection of the product, with a peak of IOP often exceeding 40 mmHg, which then decreases rapidly with a return to the value measured before the injection in approximately 15 to 20 minutes.

After an injection of triamcinolone, a delayed increased of IOP occurs in 20 to 50% of cases. Hypertension starts typically after 2 to 3 weeks, but the pressure spike is observed later, typically around Day 100. Although the half-life of triamcinolone does not exceed 18 days, hypertension persists beyond this period when the quantity of the product in the vitreous chamber is high, usually for 8 to 12 months after injection of the product.

After injection of a dexamethasone implant, a significant increase of IOP occurs less frequently in 1 to 20% of cases in literature, with comparable kinetic increase then decrease. Thus, in one of the pilot studies an IOP increase of over 10 mmHg was observed in 16% of cases 2 months after injection and in 1% of cases 6 months after injection, and IOP over 35 mmHg was reported in 3% of cases 2 months after injection and in 0.2% of cases 6 months after injection⁽⁴⁾.

Risk factors:

A high initial IOP, pre-existing glaucoma, molecule used (higher risk with triamcinolone), high dose, repeated injections, high myopia, patient age, diabetes and certain conditions (higher risk in the case of vein occlusion than in the case of diabetic macular edema or complicating an uveitis). The method of administration is also a risk factor, with in decreasing order, intraocular, periocular (sub-tenonian, sub-conjunctival), topical and systemic use.

3. Management

A complete examination including measurement of IOP, a meticulous examination of the optic disc and layer of peripapillary optical fibres eventually completed with an examination of the visual field is recommended before any intraocular injection of corticosteroids to look for a pre-existing glaucoma. The patient should be asked to confirm the absence of any past history of steroid-induced hypertension.

It has so far not been formally demonstrated that immediate and rapidly reversible IOP peaks caused by IVT, even repeated, could facilitate the development of a glaucomatous optic neuropathy in a non-glaucoma or hypertensive patient. In patients with a pre-existing glaucoma, pharmacological prevention of IOP peaks is possible (topical alpha-agonists and/or oral acetazolamide), and an IOP check just after the injection is advisable.

When the increases of IOP is delayed, a medical treatment is often sufficient. All therapeutic classes can be used, avoiding nevertheless prostaglandin analogues in the case of aphakia or posterior capsular rupture.

In the Geneva study that assessed the use of a dexamethasone implant in subjects presenting with a macular oedema after retinal vein occlusion, approximately 4% of patients presented with ocular hypertension at follow-up, with a peak 60 days after injection and a return to normal 180 days later. The percentage of patients treated with IOP lowering drugs increased from 6% before injection to 24% 6 months later⁽⁵⁾.

A laser or surgical procedure was necessary in approximately 1% of patients. After injection of an intravitreal implant of fluocinolone, IOP increase is very frequent. A phase 3 pilot study showed that over one third of patients injected required anti-glaucoma eye drops to control IOP 12 and 36 months after the injection^(6,7).

The percentage of patients who have benefited from filtration surgery was 4.8% in the group treated with a low dose, 8.1% in the group treated with a high dose (0.5% in the sham group). Therefore, the use of this implant is contraindicated in cases of pre-existing glaucoma.

Selective trabeculoplasty often has a temporary effect that can be adapted to steroid-induced hypertension.

In conclusion, perforating or non-perforating filtration surgery is necessary in some cases.

Deep sclerectomy or placement of a "micro-drain" can be envisaged in the case of steroid-induced hypertension.

An alternative can be a vitrectomy with removal of a steroid crystal implant.

References

1. Aptel F, Denis P. Retina and glaucoma: therapeutic considerations. *J Fr Ophtalmol*. 2008 Jul; 31(6 Pt 2): 2S61-4.
2. Kotliar K, Maier M, Bauer S, Feucht N, Lohmann C, Lanzl I. Effect of intravitreal injections and volume changes on intraocular pressure: clinical results and biomechanical model. *Acta Ophthalmol Scand*. 2007 Nov; 85(7): 777-81.
3. D'Amico DJ, Masonson HN, Patel M, et al; VEGF Inhibition Study in Ocular Neovascularization (V.I.S.I.O.N.) Clinical Trial Group. Pegaptanib sodium for neovascular age-related macular degeneration: two-year safety results of the two prospective, multicenter, controlled clinical trials. *Ophthalmology*. 2006; 113(6): 992-1001.
4. Haller JA, Bandello F, Belfort R Jr, Blumenkranz MS, Gillies M, Heier J, Loewenstein A, Yoon YH, Jacques ML, Jiao J, Li XY, Whitcup SM; OZURDEX GENEVA Study Group. Randomized, sham-controlled trial of dexamethasone intravitreal implant in patients with macular edema due to retinal vein occlusion. *Ophthalmology*. 2010 Jun; 117(6): 1134-1146.
5. Haller JA, Bandello F, Belfort R Jr, Blumenkranz MS, Gillies M, Heier J, Loewenstein A, Yoon YH, Jacques ML, Jiao J, Li XY, Whitcup SM; OZURDEX GENEVA Study Group. Randomized, sham-controlled trial of dexamethasone intravitreal implant in patients with macular edema due to retinal vein occlusion. *Ophthalmology*. 2010 Jun; 117(6): 1134-1146.
6. Campochiaro P.A., Brown D.M., Pearson A., Chen S., Boyer D., Ruiz-Moreno J., and al. Sustained delivery fluocinolone acetonide vitreous implants provide benefit for at least 3 year in patients with diabetic macular edema *Ophthalmology* 2012; 119: 2125-2132.
7. Brown D.M., Nguyen Q.D., Marcus D.M., Boyer D.S., Patel S., Feiner L., and al. Long-term outcomes of ranibizumab therapy for diabetic macular edema: the 36-month results from two phase III trials: RISE and RIDE *Ophthalmology* 2013; 120: 2013-2022.

Answer to the MCQ on page 103: C



9

Head upside down

Case report

Mrs. P, 53-year-old, is referred by a colleague for an additional exam for a primary open-angle glaucoma during an ophthalmologic follow-up examination for myopia. Refraction is as follows:

- Right: 20/20 with -5.50 (-1.0) 65°
- Left: 20/20 with -5.25 (-1.25) 125°

The pressure measured with the Noncontact tonometer was 17 mmHg in the right eye (pachymetry 495 μm) and 18 mmHg in the left (pachymetry 500 μm)

Angle is open with 4 elements, flat iris and pigmentation at 2.

Eye fundus is as follows (Figures 1 and 2).

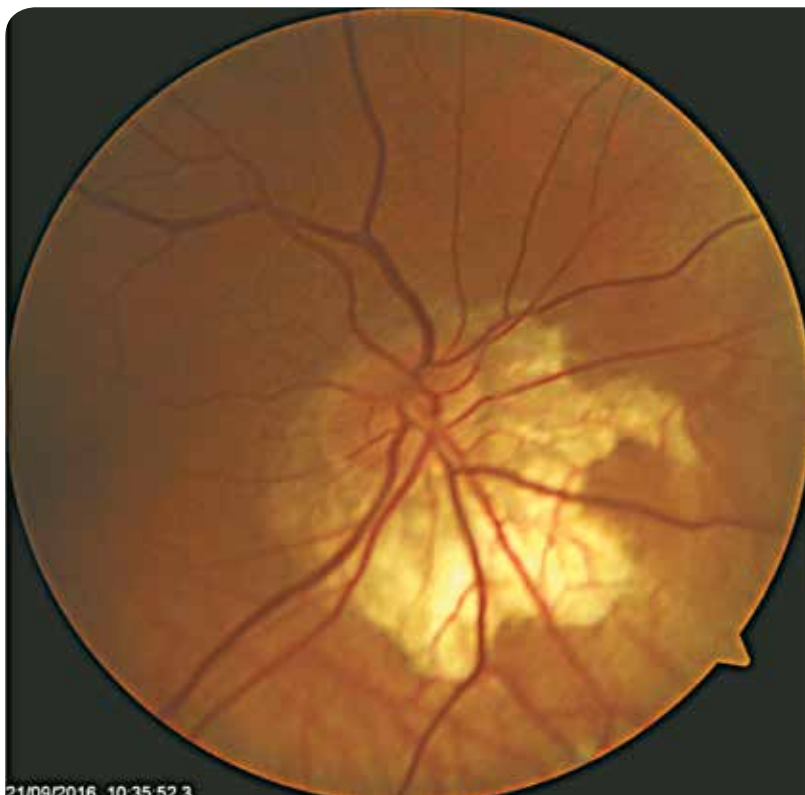

Figure 1: Retinal photograph of the right optic disc.

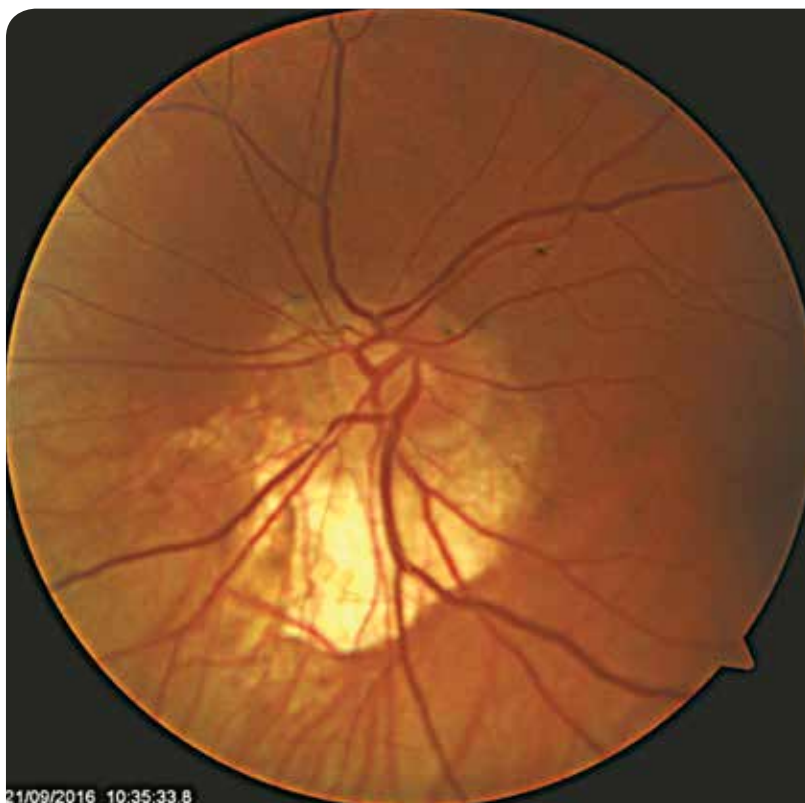

Figure 2: Retinal photograph of the left optic disc.

Standard visual field measurements are taken given this ocular hypertension (Figures 3 and 4).

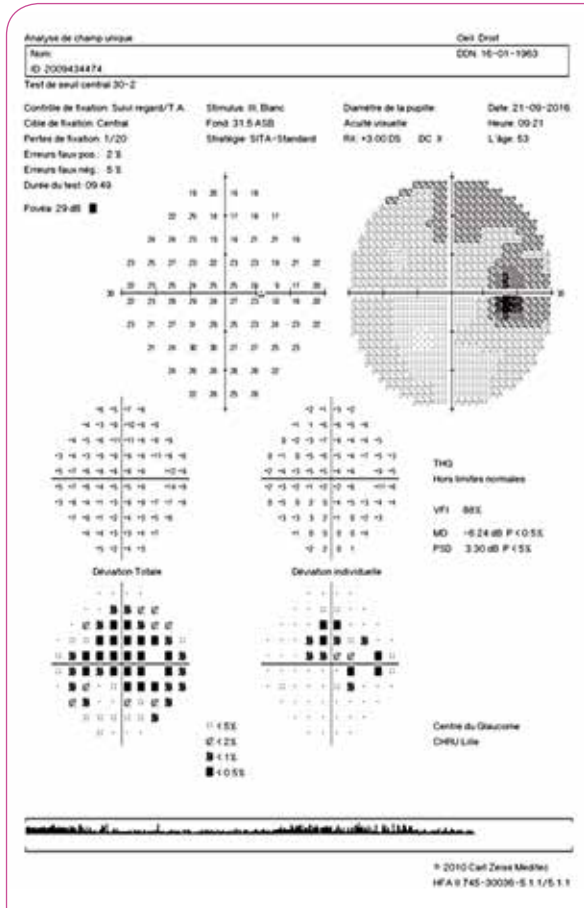


Figure 3: Right eye visual field examination.




Figure 4: Left eye visual field examination.

Multiple choice question

In this case of probable ocular hypertension, what will your approach be? (two correct answers)

- A. It is a primary open-angle glaucoma with two risk factors: myopia and ocular hypertension.
- B. It is a dysversion of the optic disc that can cause anomalies in the visual field.
- C. Treatment must be started immediately given the damage to the visual field.
- D. Given this hypertension, I recommend normal follow-up.
- E. Imaging of the optic nerve head and ganglion cell complex is a determining factor in this case.

Answer to the MCQ on page 121

You complete the exam with an optic disc imaging and a study of the ganglion cell complex (Figures 5 and 6).

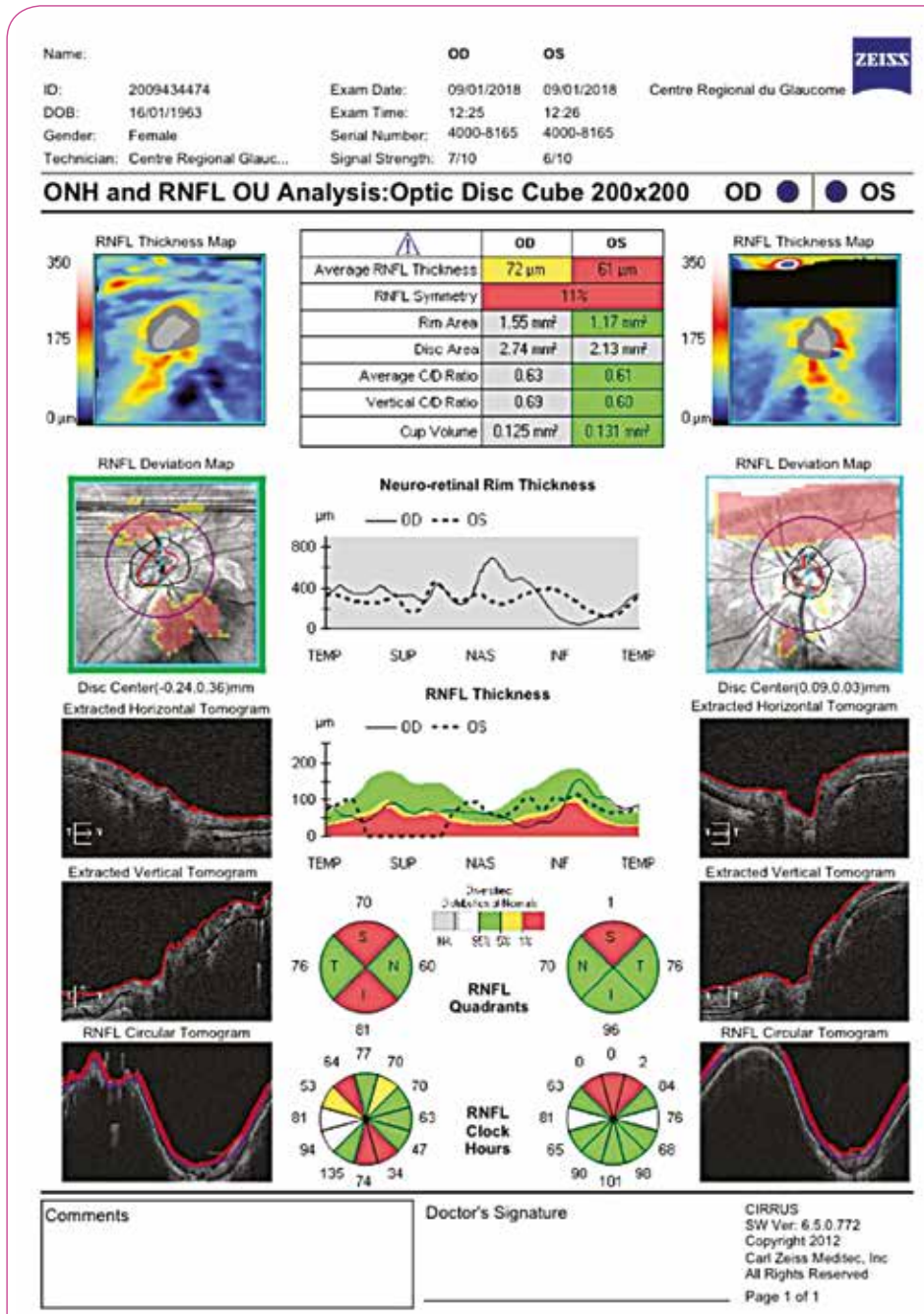
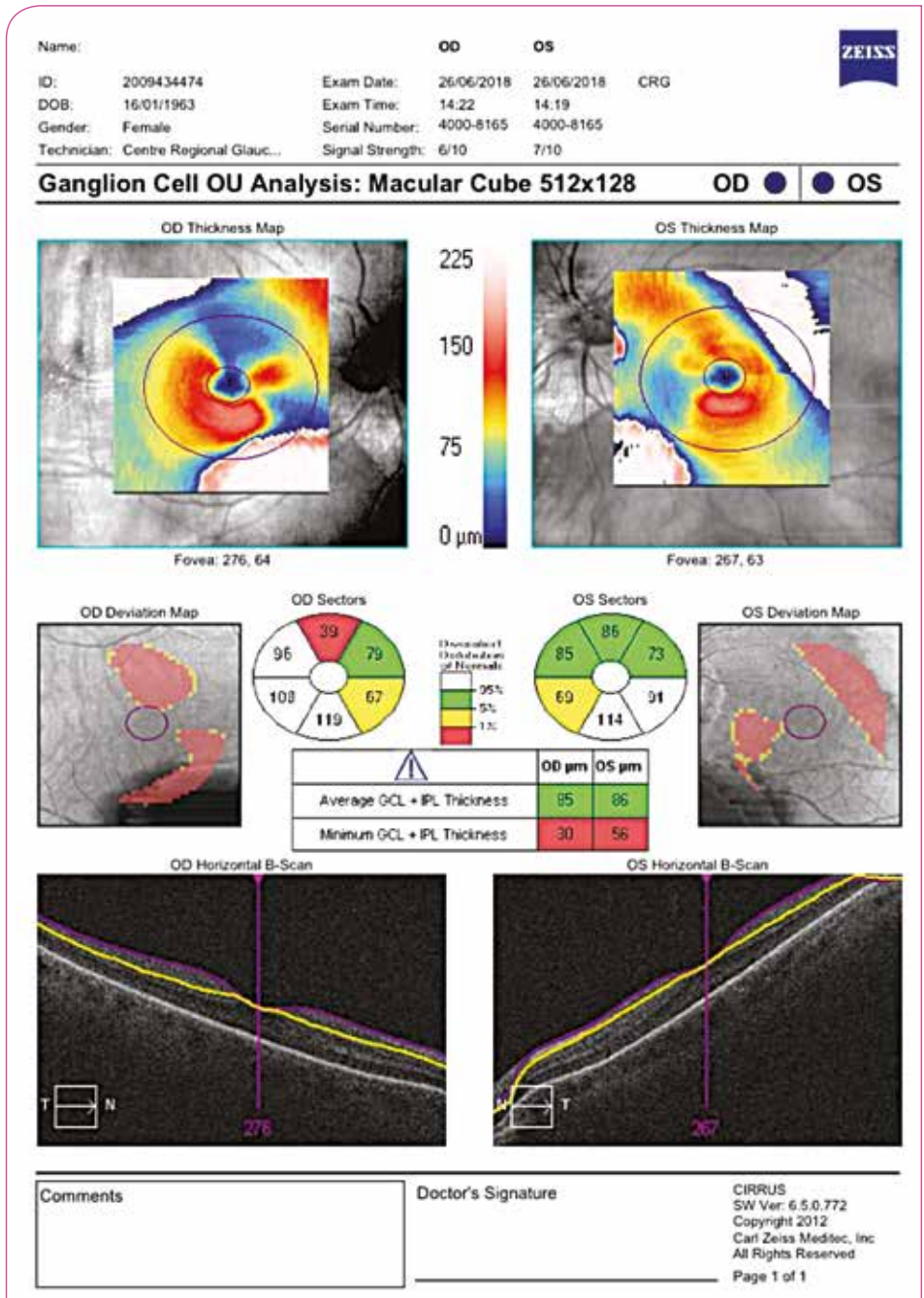


Figure 5: OCT exam of the RNFL: numerous artefacts despite several measurements.



Figures 6: OCT exam of the ganglion cell complex provides little information in this myopic patient.

The assessment is discussed with the patient and follow-up without treatment for the time being is recommended .

Dysversion of the optic disc with lower nasal vergence in both eyes but the neuroretinal border appears preserved.

Visual field defects are compatible with peripapillary atrophy. Follow-up is begun every six months with the patient's consent.

After 3 year of follow-up the visual field test shows no progression (Figures 7 and 8).




Figure 7: GPA in the right eye.

Papillary dysversion^(1,2)

Papillary dysversion is a congenital malformation of the optic disc found in 1 to 2% of the population.

Damage is more often bilateral and can be associated with a myopia above 5 diopters (20% of cases). In cases of high myopia dysversion develops concomitantly with ocular elongation.

Visual field anomalies can be associated with it: upper bitemporal damage corresponding to peripapillary atrophy. At this level there is a thinning of the retina and choroid or even of the sclera with a sparsely pigmented area.

Upper or lower nasal vergence will depend on the orientation of the central vessels of the retina.

Differential diagnoses are: papillary hypoplasia, papillary staphyloma, optic disc pit or chiasmal lesions.

The association of papillary dysversion and ocular hypertension raises the difficult problem of glaucoma diagnosis given the papillary and visual field anomalies. In the case of papillary dysversion (excluding high myopia) if deficits are noted they are stable over time.

Imaging of the optic nerve head or ganglion cell complex often provides little information due to anatomical changes^(3,4).

References

1. Apple DJ, et al. Congenital anomalies of the optic disc. *Surv Ophthalmol* 27: 3-41.
2. Welch RJ, Havens S, Hosain K Tilted Disc Syndrome: eyewiki.org/Tilted_Disc_Syndrome. 1982.
3. Sellem E. Imagerie de la papille et des cellules ganglionnaires : Photographies de la papille et des fibres nerveuses rétiniennes. in *Glaucome Primitif à Angle Ouvert Rapport SFO 2014 Elsevier Masson* 151-56.
4. Lemij H. ; Renard JP. ; Sellem E : Imagerie de la papille et des cellules ganglionnaires : Imagerie automatisée in *Glaucome Primitif à Angle Ouvert Rapport SFO 2014 Elsevier Masson* 156-158.

Answer to the MCQ on page 115: B and D



10

Myopia or glaucoma

Case report

A 52-year-old male with high myopia (-12 and -14 diopters right eye and left eye) is referred for suspected pathological excavation of the optic disc.

His intraocular pressure is 18 mmHg in both eyes without treatment.

Corneal thickness is 500 μm and visual acuity is 8/10 Pa2 with correction in both eyes.

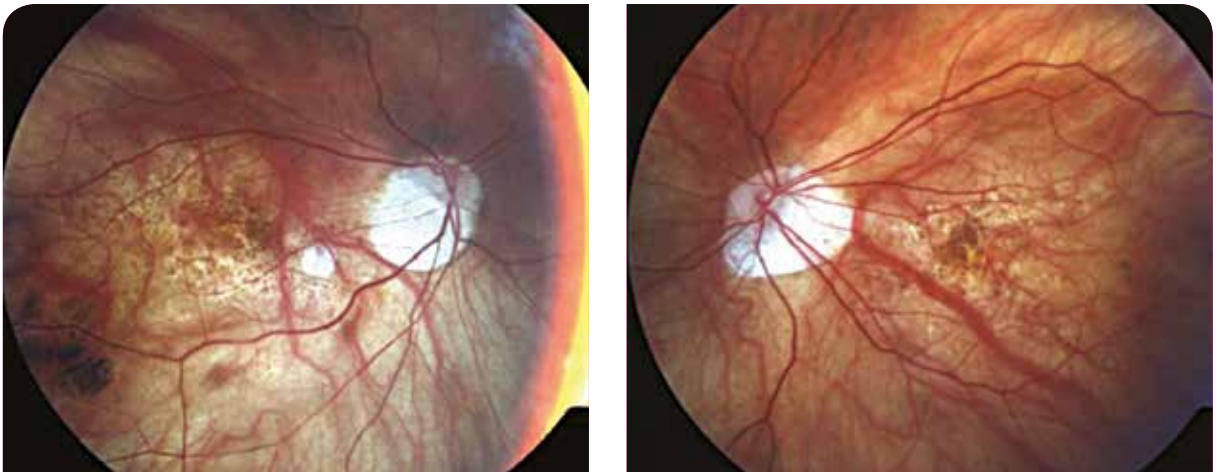


Figure 1: Retinal photographs.

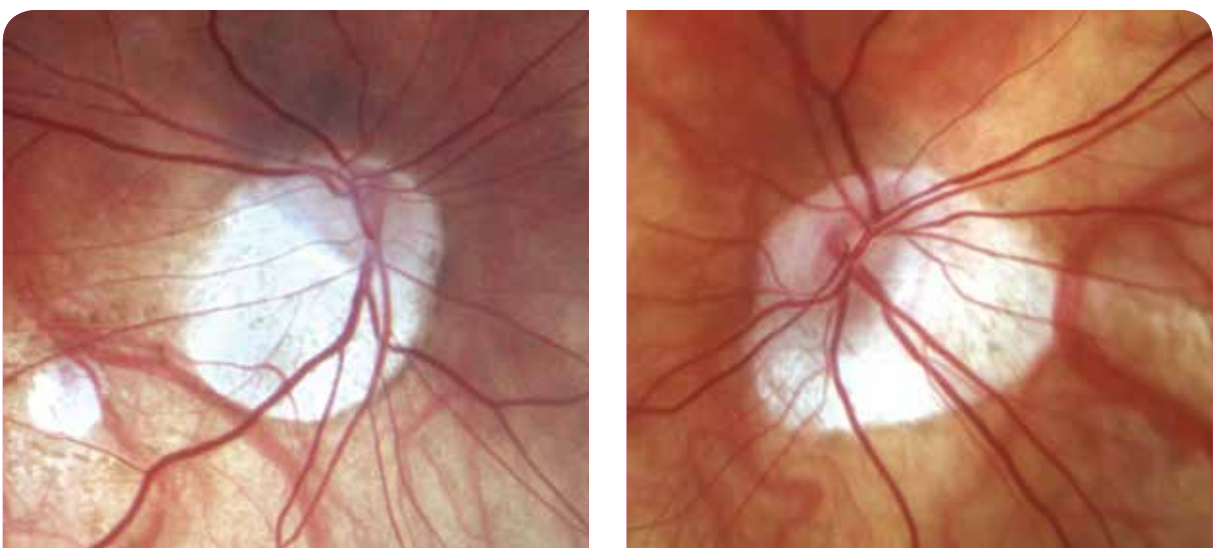


Figure 2: Detail of the optic discs.

Multiple choice question

Concerning his discs, what is your suggestion?

- A. Papillary dysversion.
- B. Presence of beta type peripapillary atrophy noted.
- C. Excavation of the optic disc is major, with a significant retraction of the perforated layer of sclera.
- D. Probable myopic conus.
- E. OCT analysis of the layer of optical fibers is not affected by the peripapillary atrophy.

Answer to the MCQ on page 131

Optical coherence tomography of the papillary region provides little information due to poor segmentation of the interfaces and a peripapillary circular scan radius crossing the area of chorioretinal atrophy.

Macular OCT is affected by the presence of a pronounced bilateral myopic conus and by diffuse chorioretinal atrophy of the back of the eye.

A visual field examination is requested.




Figure 3: 30-2 SITA standard Humphrey visual field white-on-white.

Multiple choice question

What do you suggest considering the visual field report?

- A. High myopia can cause a decrease of retinal sensitivity.
- B. On the right, the superior arciform scotoma confirms the presence of a glaucoma.
- C. On the right, the superior arciform scotoma can be due to the area of inferior retinal atrophy of the posterior pole.
- D. Determination of a temporal evolution of the deficits would favor a glaucoma.
- E. Retinal lesions of the myopia do not cause visual field anomalies.

Answer to the MCQ on page 131

Complete case report and answer to the question

The presence of arciform defects of the visual field does in fact suggest a bilateral glaucomatous neuropathy, but may correspond to the areas of chorioretinal atrophy of essentially inferior topographies.

The examination of the anterior segment is uneventful and media are transparent. The iridocorneal angle is wide open and sparsely pigmented.

A daytime intraocular pressure curve is made with values varying from 18 to 24 mmHg in the right eye and from 18 to 26 mmHg in the left eye. An eye-pressure reducing treatment with prostaglandin analogues is instituted with a six-month follow-up examination (eye fundus, OCT, visual field) to look for the progression of defects over time. In this case medical treatment would be optimized.




Figure 4: Wide open, sparsely pigmented iridocorneal angle.

Summary of the topic discussed in the case

1. Epidemiology of glaucoma in subjects with myopia

The relation between myopia and the risk of intraocular hypertension is not formally demonstrated as studies provide contradictory results.

Some studies show a relation between spherical equivalent, IOP level and/or prevalence of ocular hypertension⁽¹⁻³⁾. On the contrary, myopia was not a risk factor for conversion of ocular hypertension to glaucoma in the Ocular Hypertension Study⁽⁴⁾.

An association between myopia and the prevalence of PAOG has been demonstrated in numerous studies.

In the Blue Mountain Eye Study, subjects with myopia had a 2 to 3 times greater risk of developing a PAOG than non-myopic subjects (2). This risk was 1.6 in the Beaver Dam Eye Study⁽⁵⁾ and 1.5 in the Barbados Eye Study⁽⁶⁾.

Furthermore, in the Los Angeles Latino Eye Study, Jiang showed that the increase of the axial length was significantly associated with the incidence of PAOG (OR per mmHg = 1.48, IC 95%, 1.22-1.80, $p < 0.001$)⁽⁷⁾. A recent meta-analysis compiling 11 population studies concluded that the risk was 2.46 for myopia higher than - 3 diopters and 1.65 for myopia < 3 diopters⁽⁸⁾.

The relation between myopia and risk of progression or rate of progression of a PAOG are more controversial. To date, it has not been formally demonstrated that, other things being equal, myopic subjects have a higher risk of rapid progression of glaucoma.

2. Diagnosis and follow-up of glaucoma in myopic subjects

Clinical forms

Myopic subjects present an increased risk of PAOG or normal-tension glaucoma. Angle-closure glaucoma is very rare in high-myopic subjects, but not impossible. Moderate myopia increases the risk of pigmentary glaucoma. There is no relation between myopia and the risk of exfoliative glaucoma.

Clinical analysis of the optic disc

Many anatomical changes related to myopia often modify the appearance of the optic disc and make its analysis difficult. Optic discs of high-myopic subjects often have an abnormal bowl shape, modified orientation (tilted or dysversion, i.e. located on the border of a myopic conus), pale and somewhat excavated even in case of glaucoma (no retraction of the perforated layer of sclera). Peripapillary hemorrhages are possible even without glaucoma.

OCT analysis of the structure

Likewise, a cautious approach must be adopted to interpretation, as many papillary and retinal changes related to myopia can lead to the presence of numerous artefacts in OCT. Anomalies in shape and orientation of the optic disc as well as the presence of peripapillary chorioretinal atrophy often falsify the analysis of papillary anatomy and the thickness of the layer of optical fibers. The elongation of the eyeball,

chorioretinal atrophy of the posterior pole, as well as frequent abnormalities of the vitreo-retinal interface and macular anatomy also falsify the analysis of the thickness of the macular ganglion cell complex. The demonstration of an evolutionary nature of the deficits during follow-up over time is a strong argument in favour of the presence of a glaucomatous neuropathy associated with myopia, even if an increase in axial length and worsening of myopia are possible at all ages in high-myopic subjects.

Analysis of the function by the visual field

The white-on-white visual field in static perimetry evaluates retinal sensitivity to contrast. This sensitivity is diminished in high-myopic subjects. As a consequence, changes in the eye fundus related to a high myopia can cause defects in the visual field imitating a glaucoma-induced deficit. It is worth recalling that the enlargement of the blind spot is not a sign of glaucoma, but merely the spatial consequence of a peripapillary atrophy. A frequent pitfall is to attribute a visual field deficit to a glaucoma rather than to a peripapillary atrophy. Once more longitudinal follow-up will provide information on the progression or not of this presumed glaucoma and help make a decision.

3. Management of glaucoma in myopic subjects

Decision to treat

As mentioned above, the different eye structure anomalies present in the case of myopia can sometimes make the diagnosis and follow-up of a glaucoma difficult and uncertain. In the case of visual field and optical nerve head anomalies without diagnostic certainty, it is probably preferable to treat as if it were a verified glaucoma, in particular by recourse to medical treatments that have a good tolerance profile in myopic subjects.

For a long time, it was recommended to systematically aim for a low target IOP in myopic subjects and threshold figures of 16 or 18 mmHg were sometimes suggested as maximum tolerable pressure.

Studies over the last decades have shown that high myopia was a risk factor for the conversion of hypertension to glaucoma, but on equal footing with other risk factors, such as IOP values, corneal thickness, age, family history, etc. It is therefore appropriate not to use the threshold figure, but to consider myopia in a subject with a high risk of glaucoma or glaucomatous subject as a risk factor that is taken into account together with other known risk factors when making treatment decisions then, where necessary, for the choice of treatment.

Medical treatment

Few studies are specifically concerned with the efficacy of IOP lowering drugs in high-myopic subjects. The IOP lowering effect of the 4 therapeutic classes appears nevertheless comparable to that obtained in emmetropic subjects, with the same order between the different classes and molecules (9). Prostaglandin analogues are the most effective and are often used as first-line treatment. Myotics should probably be ruled out for high-myopic subjects, because they can prevent a regular and thorough examination of the peripheral retina and according to some favor the onset of peripheral retinal tears.

Physical treatments

The effectiveness of laser trabeculoplasty in high-myopic subjects compared to the effect obtained in non-myopic subjects remains controversial. Most studies of predictive factors of the response to a trabeculoplasty (selective or argon laser) do not consider myopia, axial length or trabecular pigmentation to be factors influencing the response or pressure decrease after this procedure^(10,11). The techniques, precautions, risks and post-management after laser trabeculoplasty are not specific. Non-steroid inflammatory drugs must be preferred to limit the risk of steroid-induced hypertension.

Surgical treatments

Surgery can be envisaged in the case of progressive glaucoma under maximum medical treatment, risk of loss of the fixation point or intolerance to eye drops. Successful surgery is sometimes difficult because the usual anatomical references are often modified or absent in a high-myopic subject, in particular during deep non-perforating sclerectomy. In the case of post-operative hypertension, the risk of complications such as choroidal detachment or macular edema is significant in high-myopic subjects, probably due to lower ocular rigidities. Therefore, the choice of dosage and time of application of anti-mitotics must be safe. When the risks are higher (advanced glaucoma with major visual field alterations, single eye, complications from glaucoma surgery in fellow eyes) an alternative physical procedure such as diode laser or ultrasound cyclocoagulation can sometimes be considered. The new microinvasive surgical procedures have not so far been assessed specifically in the case of high myopia.

References

1. Shen L, Melles RB, Metlapally R, et al. The Association of Refractive Error with Glaucoma in a Multiethnic Population. *Ophthalmology* 2016; 123(1): 92-101.
2. Mitchell P, Hourihan F, Sandbach J, Wang JJ. The relationship between glaucoma and myopia: the Blue Mountains Eye Study. *Ophthalmology* 1999; 106(10): 2010-5.
3. Nomura H, Ando F, Niino N, et al. The relationship between intraocular pressure and refractive error adjusting for age and central corneal thickness. *Ophthalmic Physiol Opt* 2004; 24(1): 41-5.
4. Gordon MO, Beiser JA, Brandt JD, et al. The Ocular Hypertension Treatment Study: baseline factors that predict the onset of primary open-angle glaucoma. *Arch Ophthalmol* 2002; 120(6): 714-20; discussion 829-30.
5. Wong TY, Klein BE, Klein R, et al. Refractive errors, intraocular pressure, and glaucoma in a white population. *Ophthalmology* 2003; 110(1): 211-7.
6. Wu SY, Nemesure B, Leske MC. Glaucoma and myopia. *Ophthalmology* 2000; 107(6): 1026-7.
7. Jiang X, Varma R, Wu S, et al. Baseline risk factors that predict the development of open-angle glaucoma in a population: the Los Angeles Latino Eye Study. *Ophthalmology* 2012; 119(11): 2245-53.
8. Marcus MW, de Vries MM, Junoy Montolio FG, Jansonius NM. Myopia as a risk factor for open-angle glaucoma: a systematic review and meta-analysis. *Ophthalmology* 2011; 118(10): 1989-94 e2.
9. European Glaucoma Society Terminology and Guidelines for Glaucoma, 4th Edition - Chapter 3: Treatment principles and options Supported by the EGS Foundation: Part 1: Foreword; Introduction; Glossary; Chapter 3 Treatment principles and options. *Br J Ophthalmol* 2017; 101(6): 1-72.
10. Hodge WG, Damji KF, Rock W, et al. Baseline IOP predicts selective laser trabeculoplasty success at 1 year post-treatment: results from a randomised clinical trial. *Br J Ophthalmol* 2005; 89(9): 1157-60.
11. Tzimis V, Tze L, Ganesh J, et al. Laser trabeculoplasty: an investigation into factors that might influence outcomes. *Can J Ophthalmol* 2011; 46(4): 305-9.

Answer to the MCQ on page 125: A, B and D

Answer to the MCQ on page 127: A, C and D



11

Glaucoma as the final blow

Case report

Mr. W, 53-year-old is referred to the department for a recently diagnosed unilateral glaucoma in the left eye.

The Occupational Health Service of his company noted a loss of vision in the left eye and requested an ophthalmologic exam.

Refraction is as follows:

- Right: 20/20 with +1.5 (-1.0) 60°
- Left: 20/30 with + 1.00

The biomicroscopic examination of the right and left anterior segment appeared normal.

Intraocular pressure without treatment at this stage is measured:

- Right: 16 mmHg (pachymetry 540 μm)
- Left: 26 mmHg (pachymetry 550 μm)

Right and left gonioscopy is as follows (Figures 1 and 2).



Figure 1: Gonioscopic image of the right eye: inferior temporal quadrant.



Figure 2: Gonioscopic image of the left eye: temporal quadrant.

Multiple choice question

Gonioscopy performed on this patient help to conclude that (two correct answers):

- A. It is a Cogan-Reese type ICE syndrome in the left eye.
- B. It is a pigmentary dispersion syndrome.
- C. All the quadrants in both eyes must be examined.
- D. There is an angle recession in the left eye.
- E. Sampaolesi's line and exfoliative material found in the left eye.

Answer to the MCQ on page 141

The interview with the patient easily confirms the diagnosis of post-traumatic angle-recession glaucoma.

He reports that, a few year before, while opening a valve, a plastic tube under pressure hit him in the left hemiface. An ophthalmologic exam at the Emergency Ward was not performed despite the presence of a voluminous orbital hematoma around the left eye.

An examination of the visual field and optic disc as well as ganglion cell complex imaging confirms the diagnosis and quantifies the lesion (Figures 3 to 6).

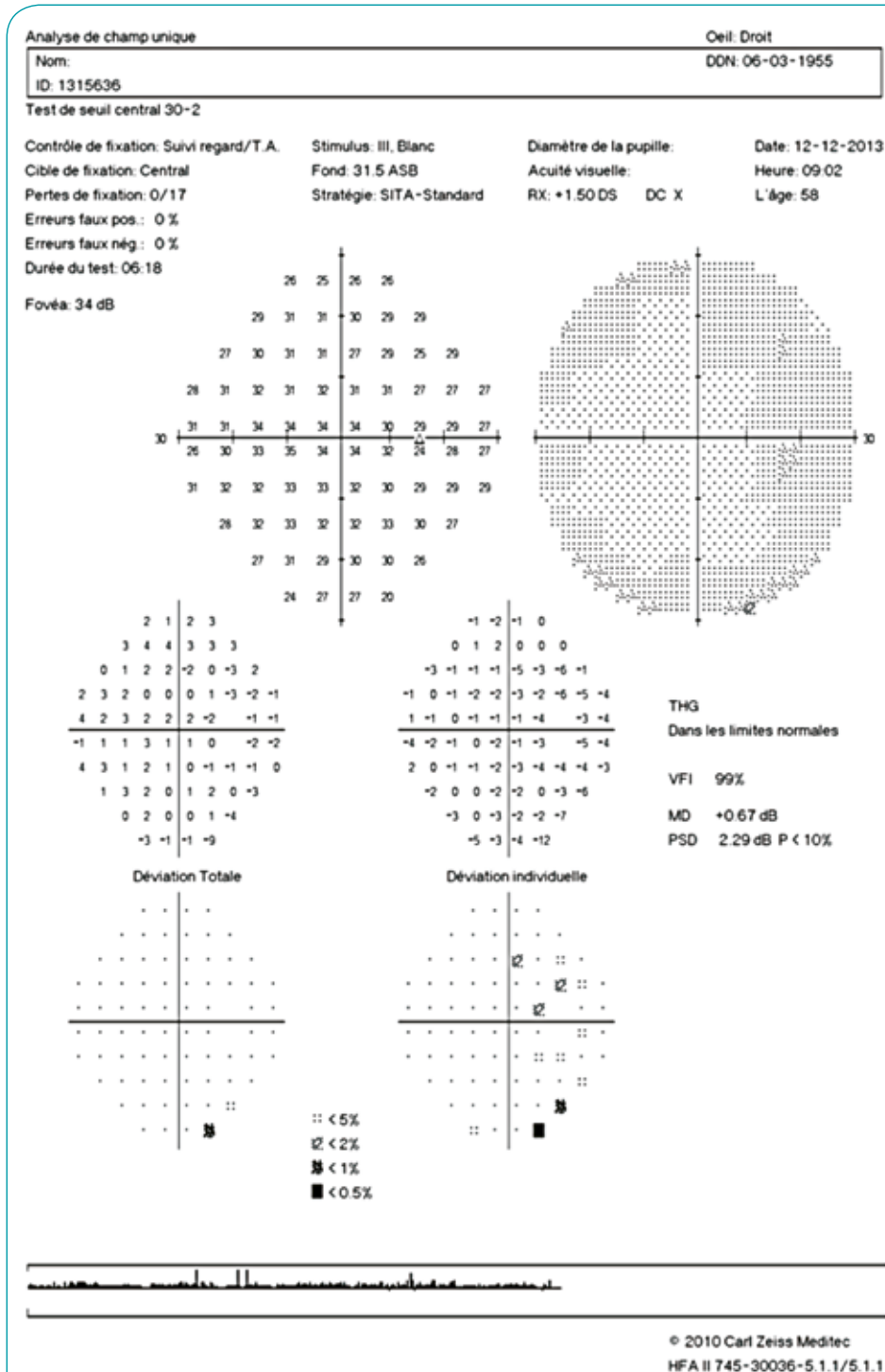


Figure 3: Normal standard visual field of right eye.

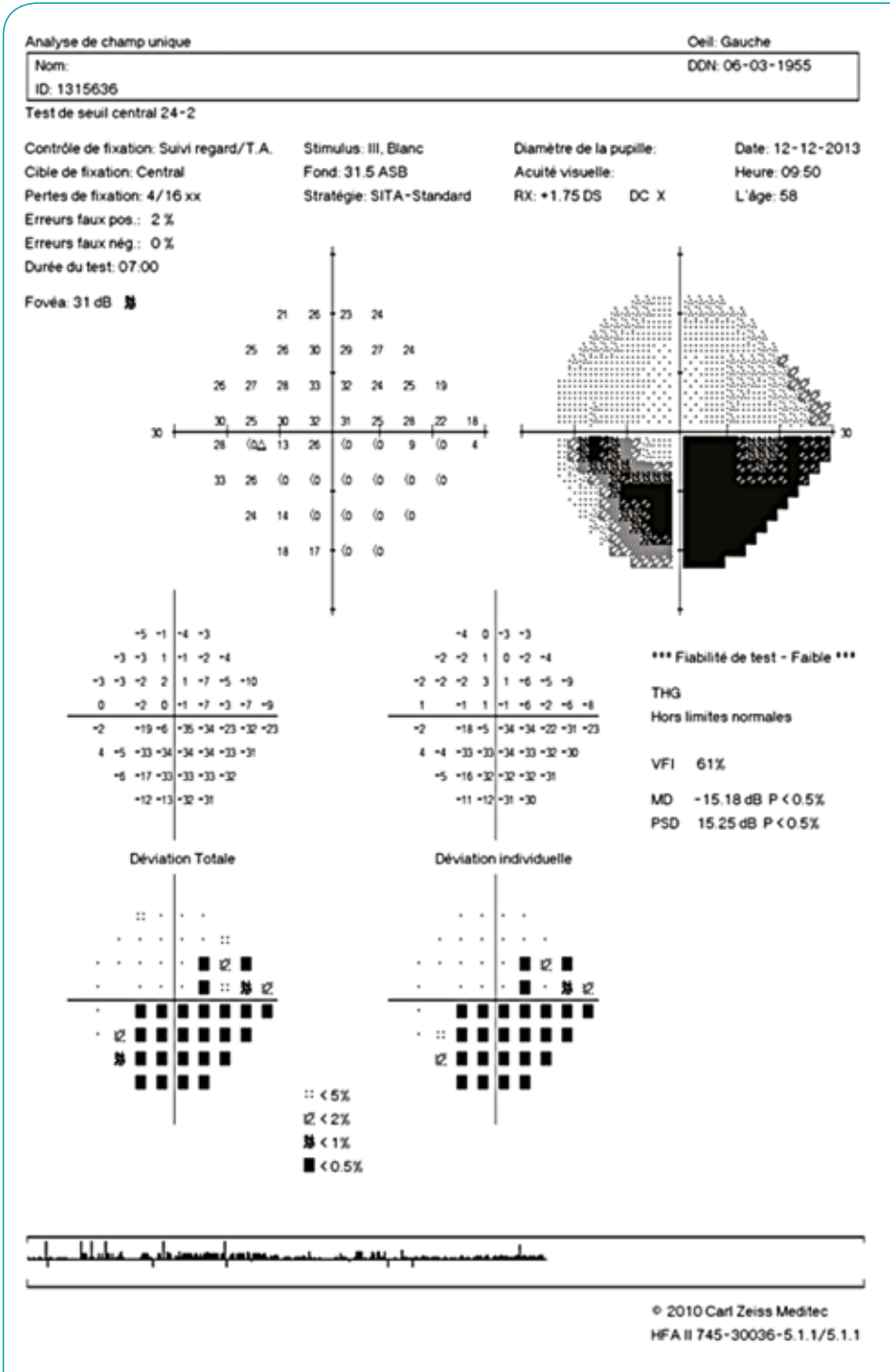


Figure 4: Standard visual field of left eye: severe lesion (MD - 15.15 dB).

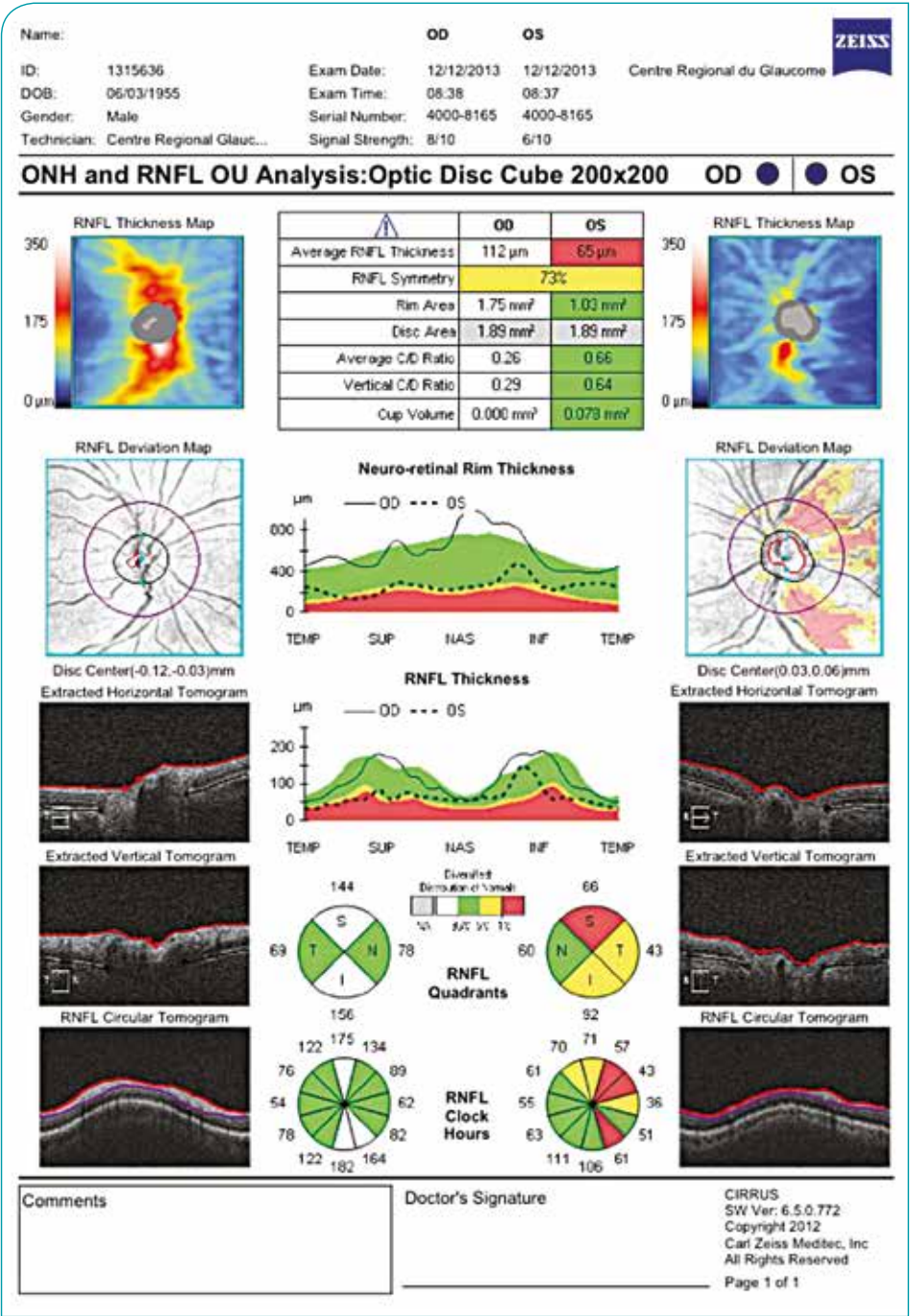


Figure 5: OCT examination of the RNFL: confirmation of left lesion.

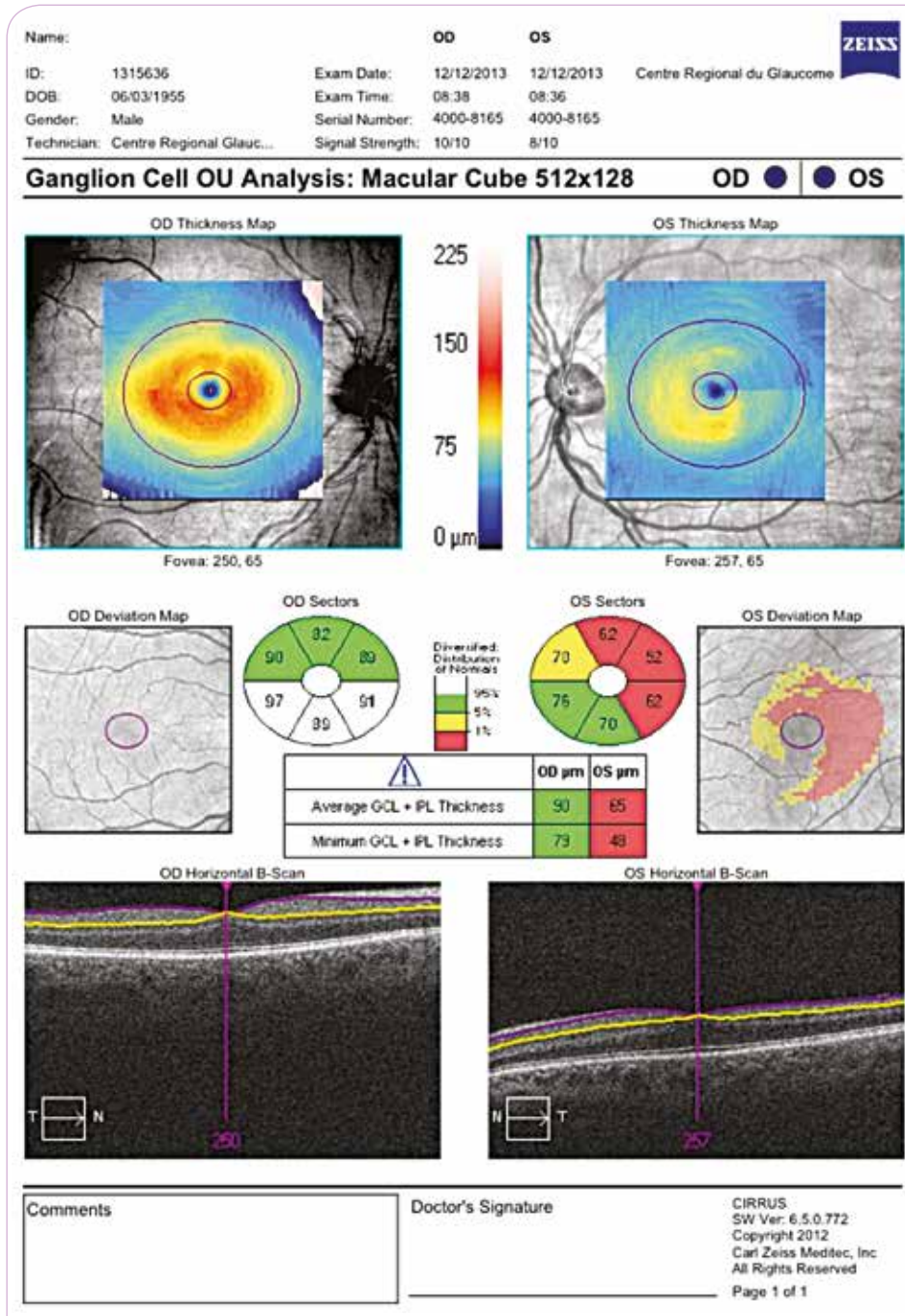


Figure 6: Examination of the ganglion cell complex: pronounced left deficit.

Summary of the topic discussed in the case

The diagnosis of post-traumatic angle-recession glaucoma is confirmed.

Medical treatment with prostaglandin analogue in monotherapy is started in the left eye, which lowers IOP to 14 mmHg after 6 weeks of treatment.

Post-contusive angle-recession glaucoma is a secondary glaucoma.

From 5 to 20% of angle recessions progress towards a glaucoma⁽¹⁾ and it can occur belatedly up to 50 year after the contusion⁽²⁾.

Hypertension of the aqueous humor on the iridocorneal angle will cause tears between the longitudinal and circular fibers of the ciliary muscle.

The lesions caused on the trabecular meshwork and on Schlemm's canal explain the initial hypertension, but secondary hypertension is the result of the scar and fibrosis of the trabecular meshwork and Schlemm's canal complex⁽³⁾.

Medical treatment is the first-line treatment that provides good results⁽⁴⁾.

Trabeculoplasty on the other hand is logically not very effective.

Surgery will be proposed given a medically uncontrolled progression. Results are identical to those expected in primary open-angle glaucoma surgery⁽⁶⁾.

References

1. Kaufman J, Tolpin D. Glaucoma after traumatic angle recession. *Am J Ophthalmol*. 1974; 78: 648-654.
2. Spaeth GL. Traumatic hyphema, angle recession, dexamethasone hypertension, and glaucoma. *Arch Ophthalmol*. 1967; 78: 714-721.
3. https://eyewiki.org/Angle_Recession_Glaucoma
4. EGS 4th Ed 2014
5. Robin AL, Pollack IP. Argon laser trabeculoplasty in secondary form of open angle glaucoma. *Arch Ophthalmol*. 1983; 101: 382-384.
6. Trabeculectomy with mitomycin C in the treatment of post-traumatic angle recession glaucoma T Manners, J F Salmon, A Barron, C Willies, A D N Murray *Br J Ophthalmol* 2001; 85: 159-163.

Answer to the MCQ on page 135: C and D



12

Frozen eye

Case report

A 63-year-old patient from North Africa consulted the Emergency Department for a decrease in visual acuity that occurred the day before with red eye and pain in the right eye.

He is regularly followed by an ophthalmologist and treated with a prostaglandin analogue for a glaucoma in the right eye. He says he lost his left eye 5 year before due to a retinal vein occlusion.

At the examination intraocular pressure is 40 mmHg in the right eye and 8 mmHg in the left. Visual acuity is 20/200 with his correction in the right eye and he has no perception of light in the left.

The examination of the anterior segment shows a moderate conjunctival hyperemia in the right and a significant corneal edema that prevents a detailed exam of the anterior chamber. It seems deep to you and the patient is phakic. The gonioscopic and eye fundus exam cannot be done due to the corneal edema.

He shows a report of his last ophthalmologic exam: visual acuity right eye 20/30 with +0.25, IOP 19 mmHg under latanoprost 1 drop in the evening, gonioscopy open angle grade 4 and densely pigmented, nuclear cataract, eye fundus optical nerve glaucomatous c/d 0.9, OCT RNFL 58 μ m. Left eye lost and not examined.

Multiple choice question

What are the two situations among the following that can explain the clinical picture of the right eye? (two correct answers)

- A. Acute angle closure crisis
- B. Neovascular glaucoma
- C. Plateau iris syndrome
- D. Exfoliative glaucoma
- E. Pigmentary dispersion syndrome

Answer to the MCQ on page 153

Complete case report and answer to the question

The examination of the left eye shows a rubeosis iridis probably old and a dense obturating cataract.

The patient is hospitalized and local and general IOP lowering drugs are initiated.

The next day IOP is 12 mmHg in the right eye, the corneal edema has regressed and the examination after pupillary dilation shows a pseudo-exfoliative syndrome with the presence of a white ring on the pupillary border and concentric deposits on the anterior surface of the lens.

The gonioscopic exam finds an open iridocorneal angle with dense trabecular meshwork pigmentation on Schwalbe's ring (Sampaolesi's line).

The right optic disc is deeply excavated with a vertical cup/disk ratio estimated at 0.9.

The visual field and OCT confirm advanced glaucomatous neuropathy.

A few days later successful pressure control is obtained with a prostaglandin and beta-blocker fixed-combination.

A daytime intraocular pressure curve done 3 months later shows high-frequency pressure fluctuations throughout the day (16 to 28 mmHg). Combined cataract surgery and placement of a "micro-drain" is proposed to the patient.

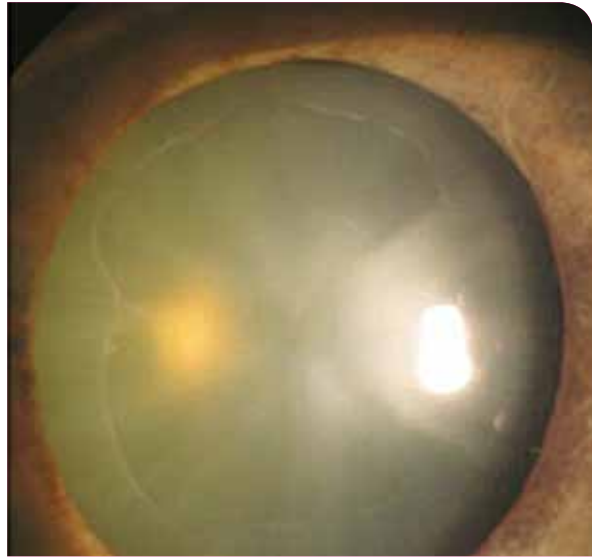
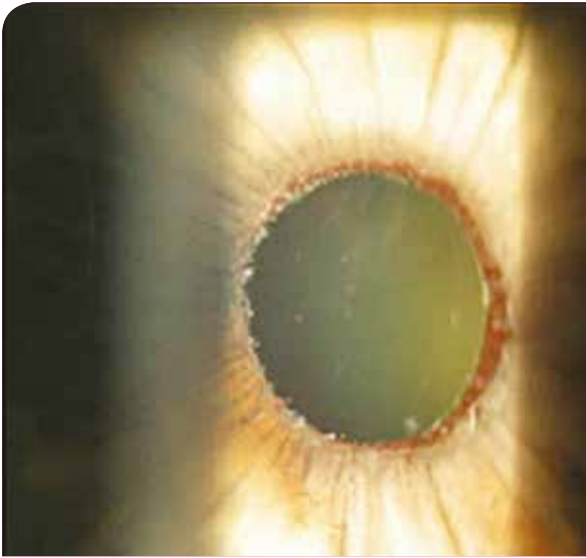


Figure 1: anterior segment of the right eye: deposits of exfoliative materials on the pupillary border and anterior crystalline membrane.

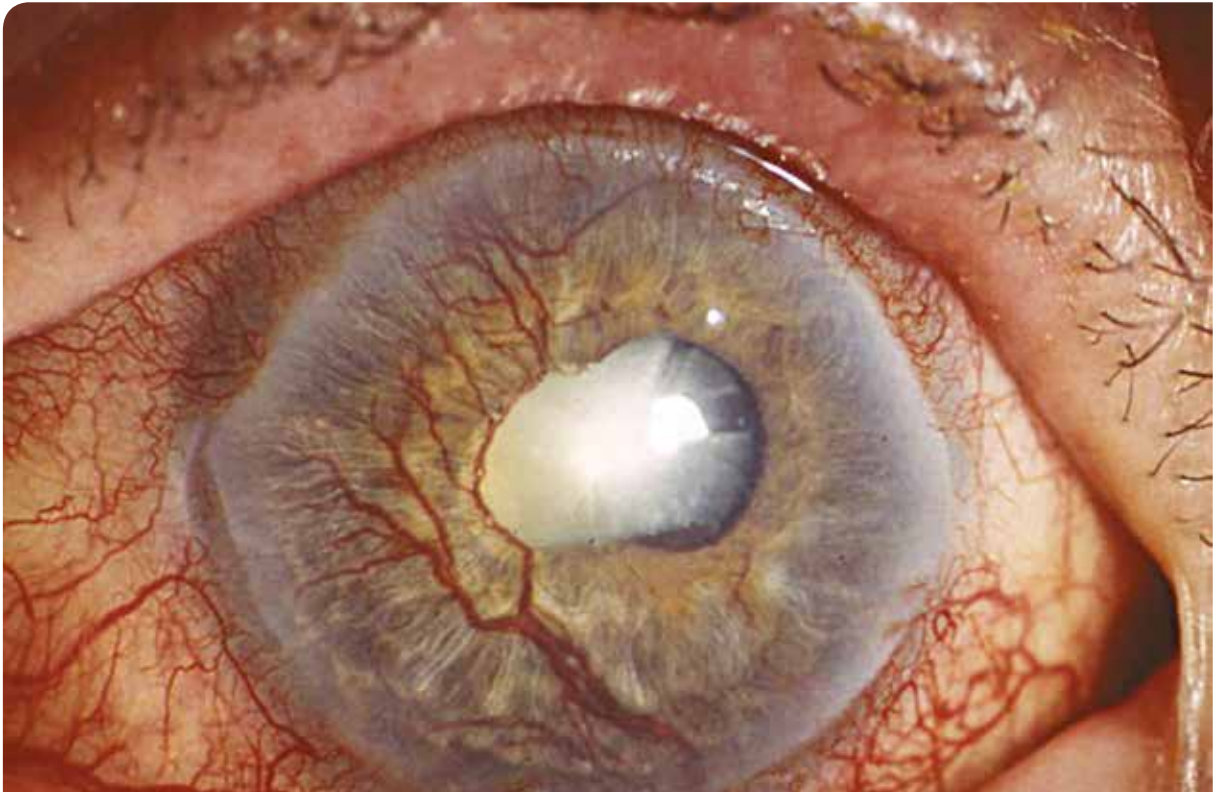


Figure 2: Anterior segment of the left eye: iris neovascularisation and obturating cataract.

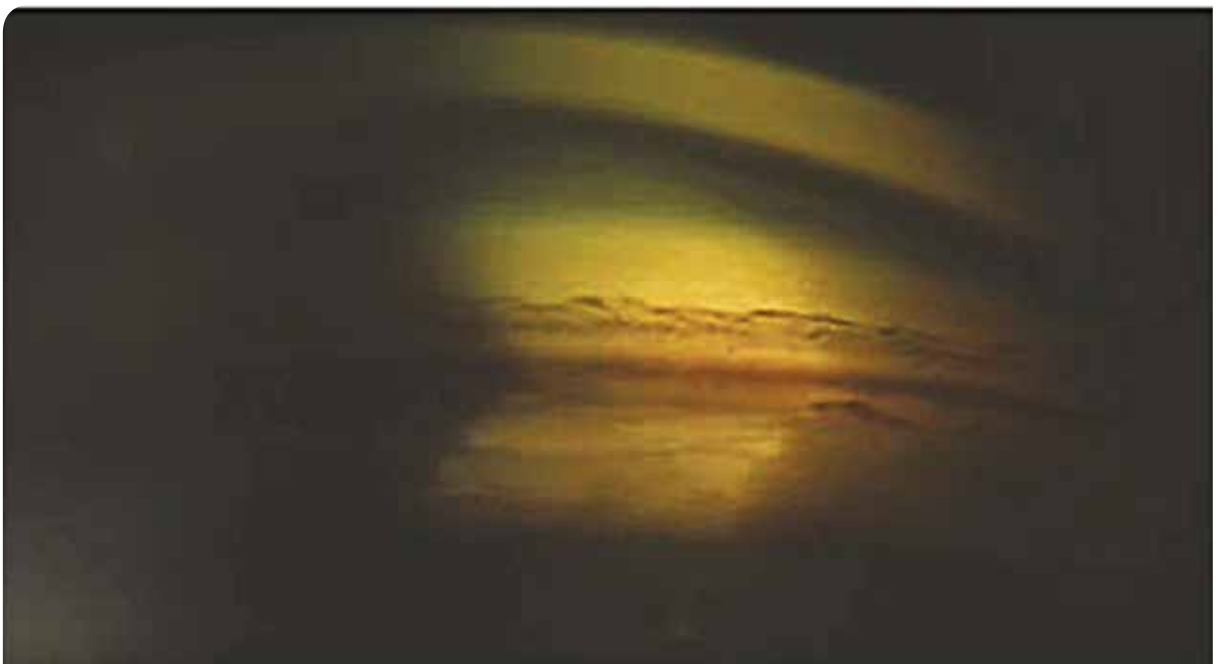

Figure 3: Gonioscopic exam of the right eye: finds an open iridocorneal angle, trabecular meshwork pigmentation, lines of pigment on Schwalbe's ring (Sampaolesi's line).

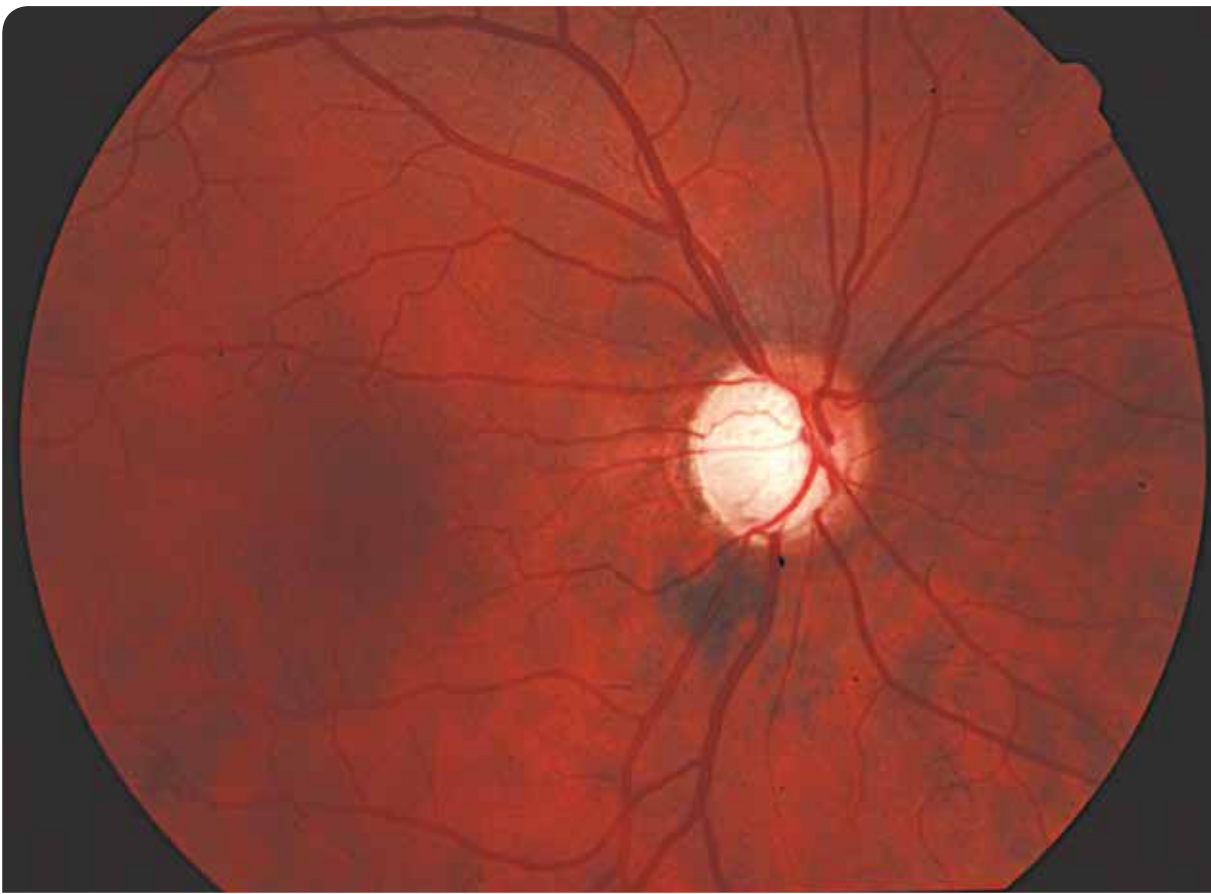


Figure 4: Right eye fundus.

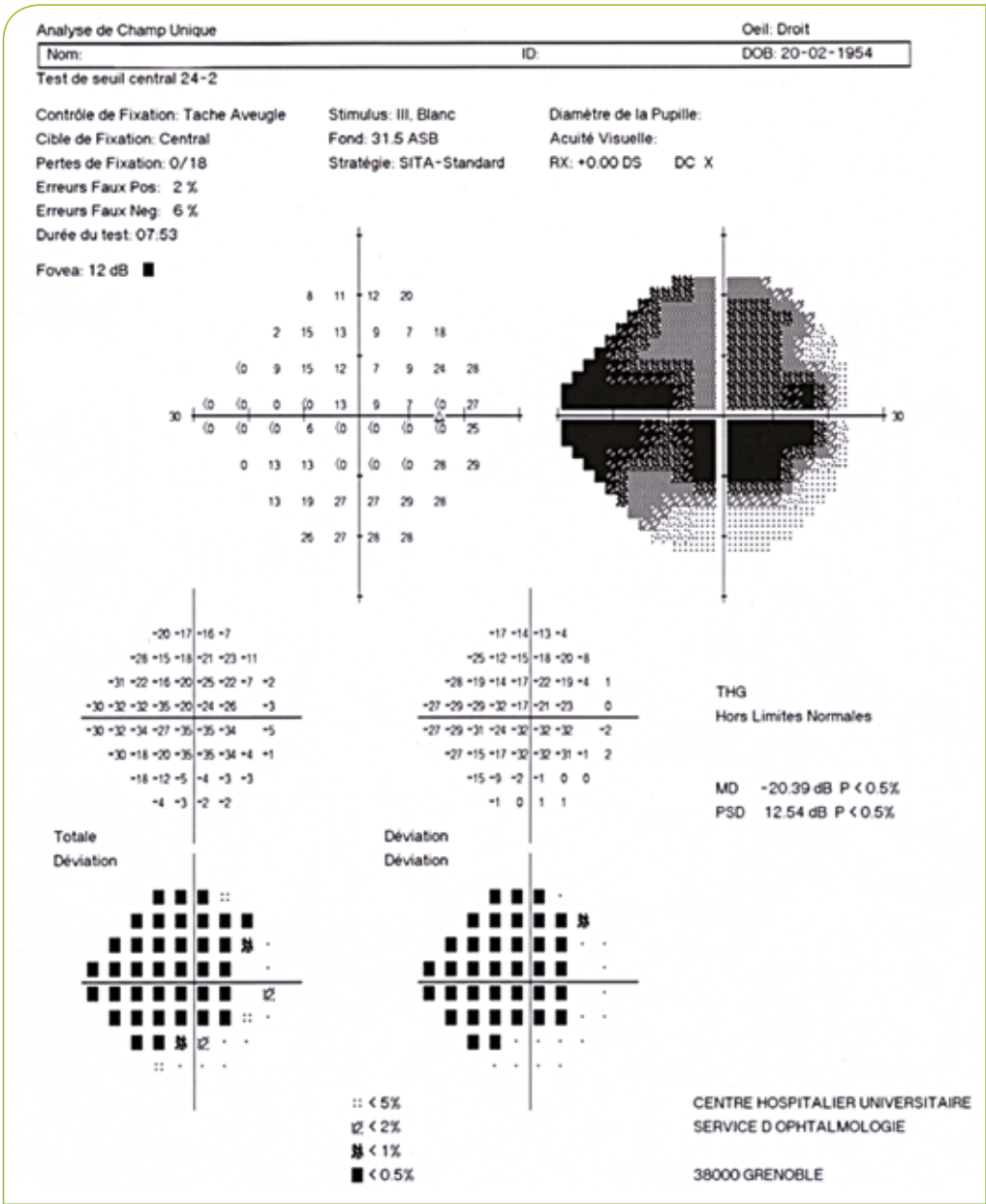


Figure 5: Right visual field.

Summary of the topic discussed in the case

Pathophysiology

Exfoliative syndrome is a systemic disease of the extracellular matrix, characterized by excessive production and progressive accumulation in the intra- and extra-ocular tissues of abnormal and insoluble fibrillated extracellular material (eye, brain, kidney, liver, striated muscles, cardiac muscle, etc.)⁽¹⁾.

Exfoliative syndrome is often hereditary and the presence of the gene of the LOXL1 enzyme increases the risk of exfoliative syndrome and exfoliative glaucoma (GXF)⁽¹⁻⁴⁾.

Diagnosis

The exfoliative syndrome is often unilateral.

Prevalence varies greatly depending on the subject's geographical origin with a high frequency in Scandinavia, Brittany, Savoy and along the southern rim of the Mediterranean.

Women are affected more often than men. The deposits of fibrillated deposits can be observed on different structures of the eye ⁽²⁻⁴⁾.

The lens is the site of the pathognomonic sign of exfoliative syndrome with whitish, translucent deposits with a frozen appearance arranged in a halo sign on the anterior crystalloid. The iris lesion is also characteristic with whitish, frozen deposits irregularly spread out on the iris ring. Corneal alterations are possible with deposits of exfoliative material as well as pigment granules on the endothelium. Endothelial cell density is often decreased. The iridocorneal angle is usually open with pronounced but irregular pigmentation that generously spreads onto and in front of Schwalbe's line forming the classic Sampaolesi line.

The exfoliative material can be seen on zonular fibers (Figure 6). They are sometimes fragile or even torn, explaining a possible phakodonesis and the possible complications during cataract surgery (subluxation or luxation of the capsular bag). Association with cerebrovascular and cardiac lesions has been described ⁽⁴⁾.

Evolution/prognosis

Some studies have reported an exfoliative syndrome to exfoliative glaucoma conversion rate of 30 to 50% in 10 year ⁽⁵⁾.

Exfoliative glaucoma often progresses more rapidly than primary open-angle glaucoma and often leads to blindness ⁽⁶⁾. It often reacts less well to medical treatment but often responds well to laser trabeculoplasty.

Management

Medical treatment

All therapeutic classes can be used.

It should be noted that the initial IOP is often high and recourse to bitherapy - if possible, in the form of fixed-combination - is often necessary to reach an IOP target that can prevent the worsening of perimetric deficits. The prescription of bitherapy from the outset of treatment can sometimes be envisaged, if IOP is very high and glaucomatous neuropathy advanced.

Laser trabeculoplasty

Pseudo-exfoliative syndromes complicated by hypertension or glaucoma are good indications for argon laser trabeculoplasty or selective trabeculoplasty often with a significant decrease in pressure. Trabeculoplasty can be followed by significant pressure spikes difficult to control that require regular follow-up and adaptation of energy level and number of impacts.

Filtration surgery

The use of surgery is common. The various routine techniques (trabeculectomy and deep sclerectomy) can be used. The peri- or post-operative application of antimetabolites is frequent.

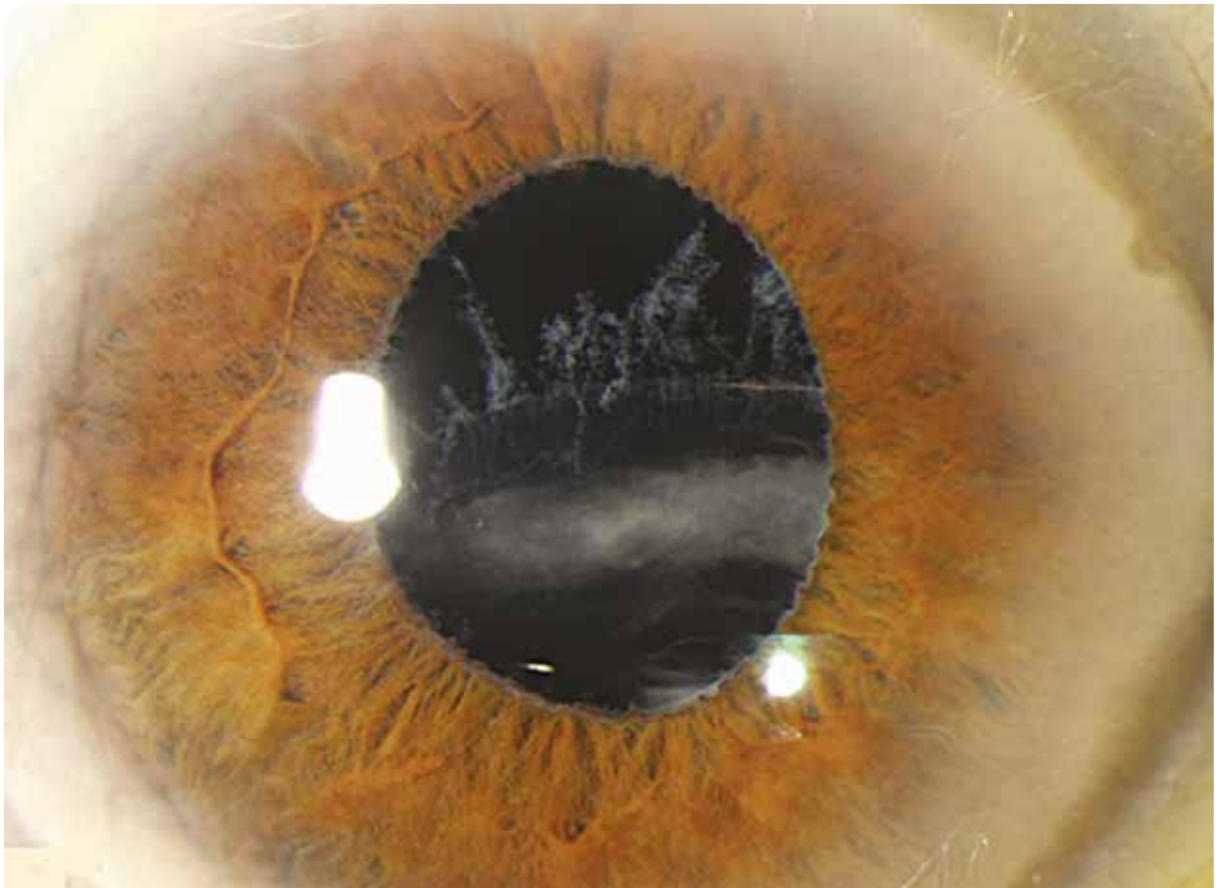


Figure 6: Deposits of exfoliative material on the zonules associated with lens subluxation.

References

1. Ritch R. Ocular Findings in Exfoliation Syndrome. *J Glaucoma*. 2018 Jul; 27 Suppl 1: S67-S71.
2. Chen HS, Hsiao CH, Chuang LH, Su WW. Clinicohistopathology of cataract associated with true exfoliation of the lens capsule. *J Cataract Refract Surg*. 2011 May; 37(5): 969-70.
3. Aboobakar IF, Johnson WM, Stamer WD, Hauser MA, Allingham RR. Major review: Exfoliation syndrome; advances in disease genetics, molecular biology, and epidemiology. *Exp Eye Res*. 2017 Jan; 154: 88-103.
4. Chung H, Arora S, Damji KF, Weis E. Association of pseudoexfoliation syndrome with cardiovascular and cerebrovascular disease: a systematic review and meta-analysis. *Can J Ophthalmol*. 2018 Aug; 53(4): 365-372.
5. Puska P. Unilateral exfoliation syndrome: conversion to bilateral exfoliation and to glaucoma : a prospective 10- year follow- up study. *J Glaucoma*. 2002; 11: 517-24.
6. Heijl A, Bengtsson B, Hyman L, et al. Natural history of open- angle glaucoma. *Ophthalmology*. 2009; 116 : 2271-6.

Answers to the MCQ on page 145: C and D



13

Did you say normal?

Case report

Ms D. 60-year-old is referred to the Regional Glaucoma Centre by her ophthalmologist for an opinion on her bilateral normal-tension glaucoma.

The diagnosis was based on the papillary lesion in the left eye. However, IOP measured three times never exceeded 12 mmHg.

The interview with the patient did not reveal any personal or family history.

Visual acuity is:

- Right : 20/20 with (+0.50) 110°
- Left: 20/20 with (+0.25)

Intraocular pressure is:

- Right : 12 mmHg (pachymetry 562 μm)
- Left : 10 mmHg (pachymetry 556 μm)

The gonioscopic exam notes a grade 4 open angle in all four quadrants with grade 2 pigmentation in both eyes.

Eye fundus is as follows (Figures 1 and 2).

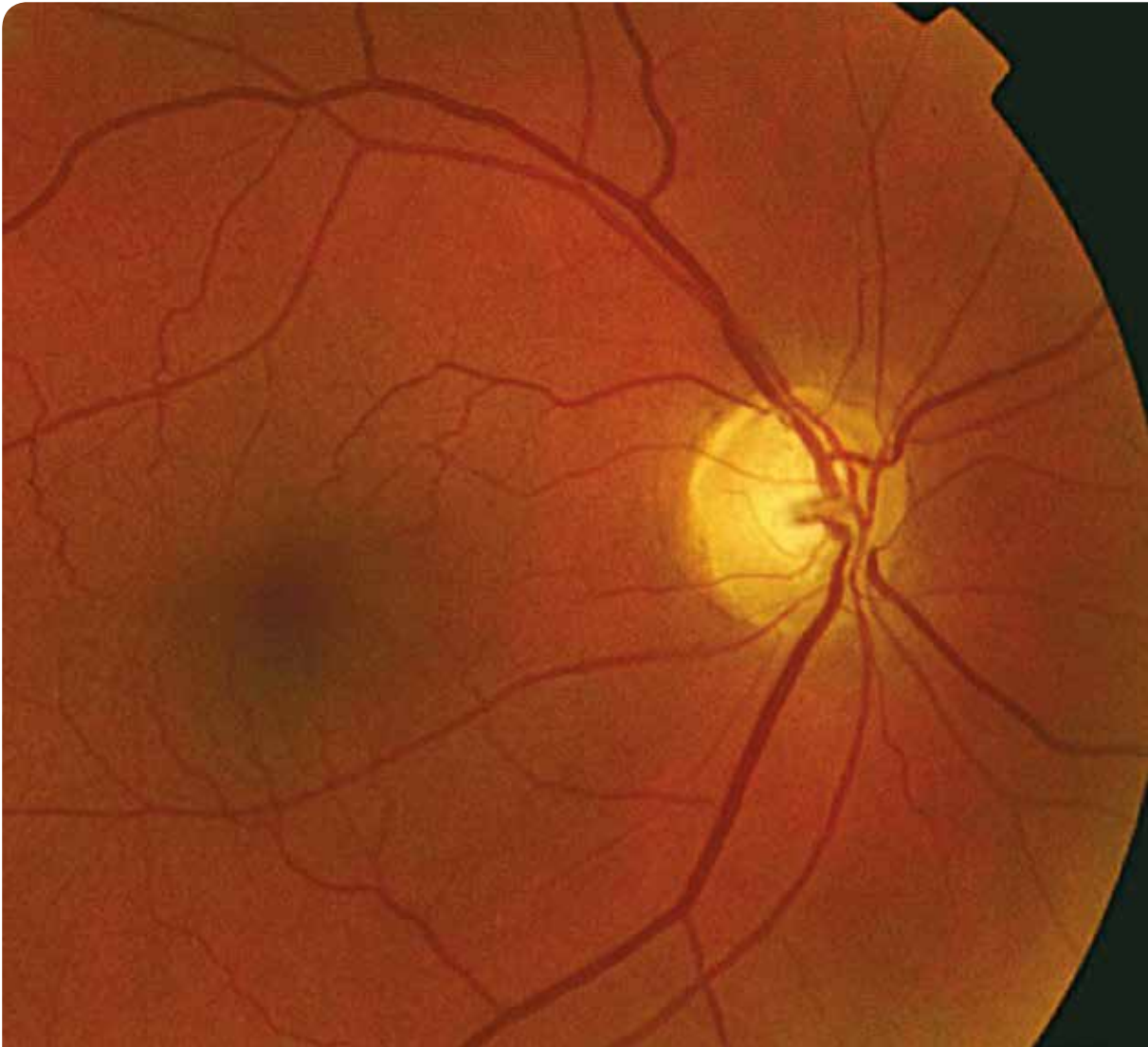


Figure 1: Retinal photograph of right eye fundus.

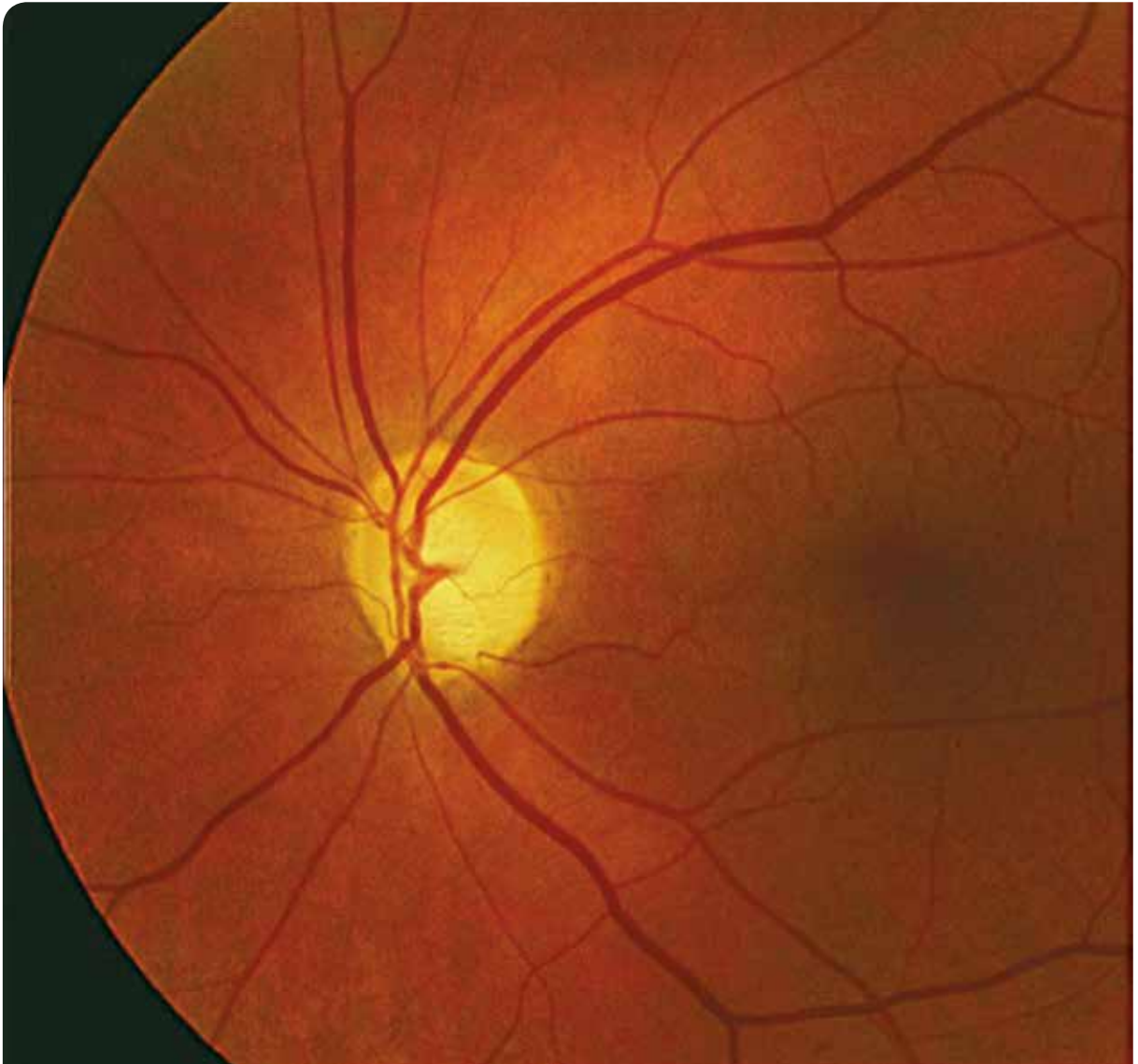

Figure 2: Retinal photograph of left eye fundus: thinning of inferior neuro-retinal ring and papillary pallor.

Visual fields are done (Figures 3 and 4):

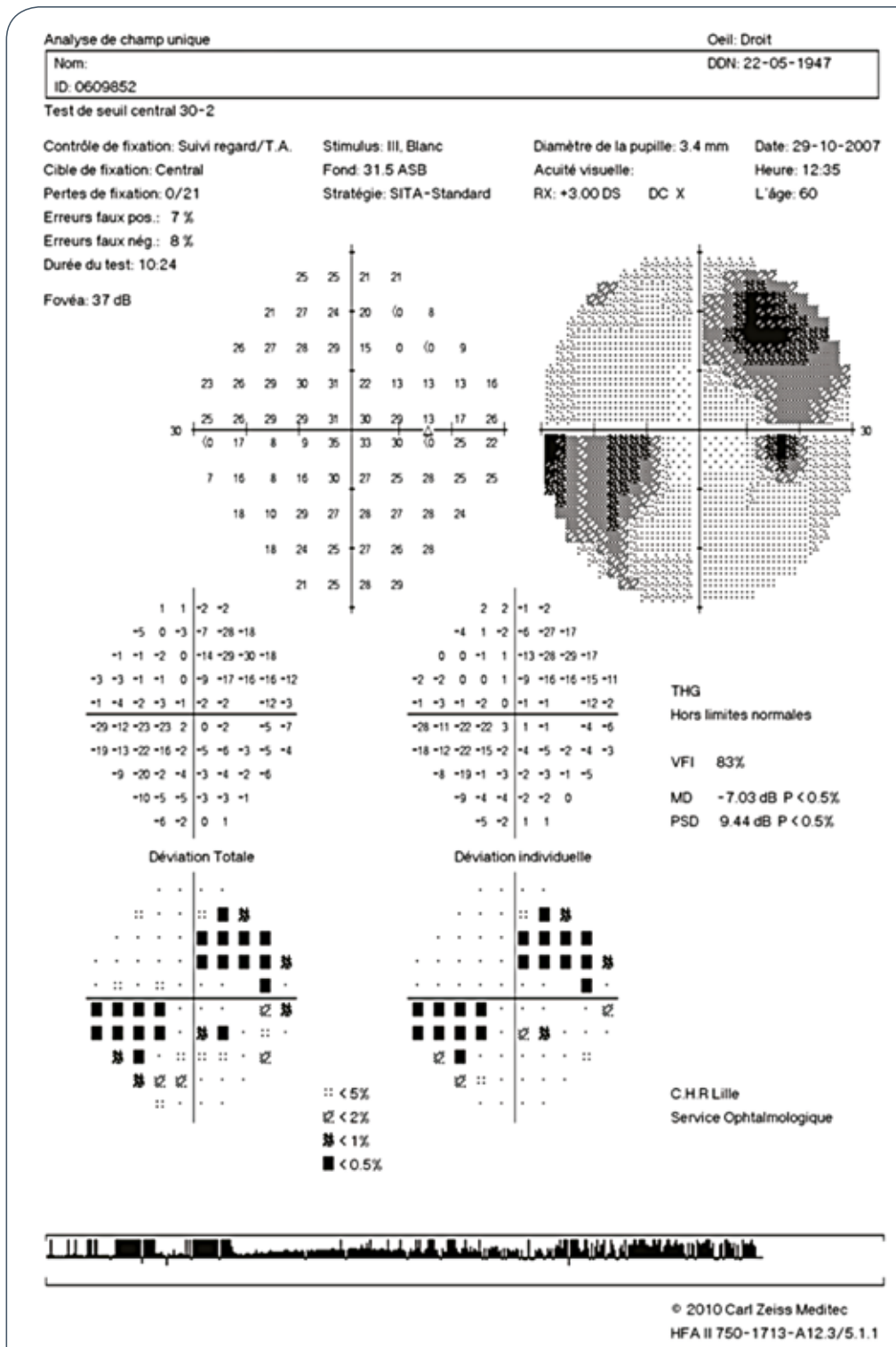


Figure 3: Standard right eye visual field examination.

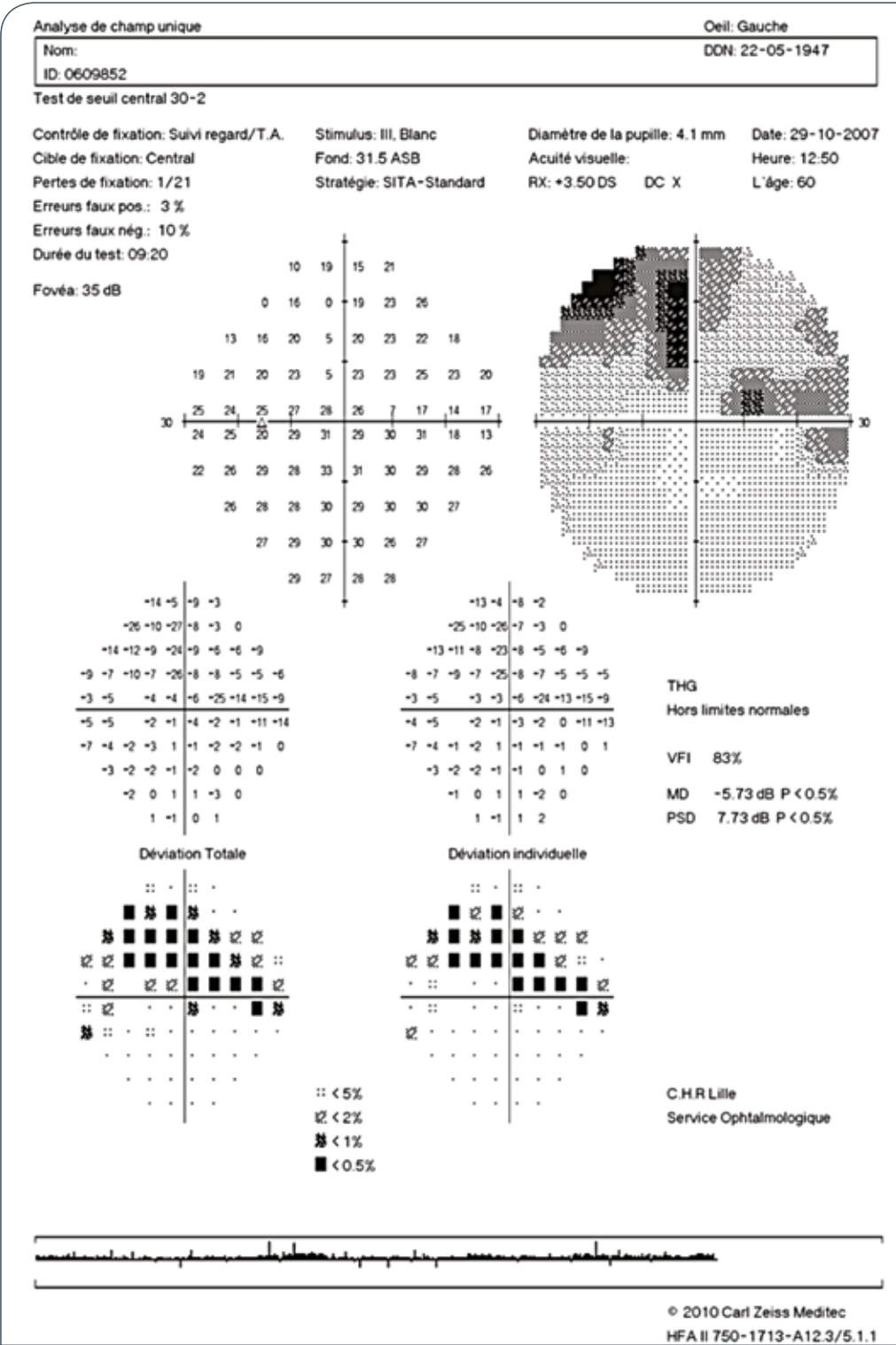


Figure 4: Standard visual field exam of the left eye.

Multiple choice question

What diagnosis do you suspect from this initial ophthalmologic exam? (one correct answer)

- A. A typical normal-tension glaucoma.
- B. A 24-hour IOP curve should be done.
- C. A primary open-angle glaucoma.
- D. The perimetric defects are not compatible with glaucoma.
- E. A bilateral post-traumatic glaucoma.

Answer to the MCQ on page 167

Given these defects of the two visual fields suggesting a superior bitemporal quadrantanopia, cerebral imaging is requested at the neuroradiology department. MRI reveals a PITUITARY MACROADENOMA (Figures 5 and 6).

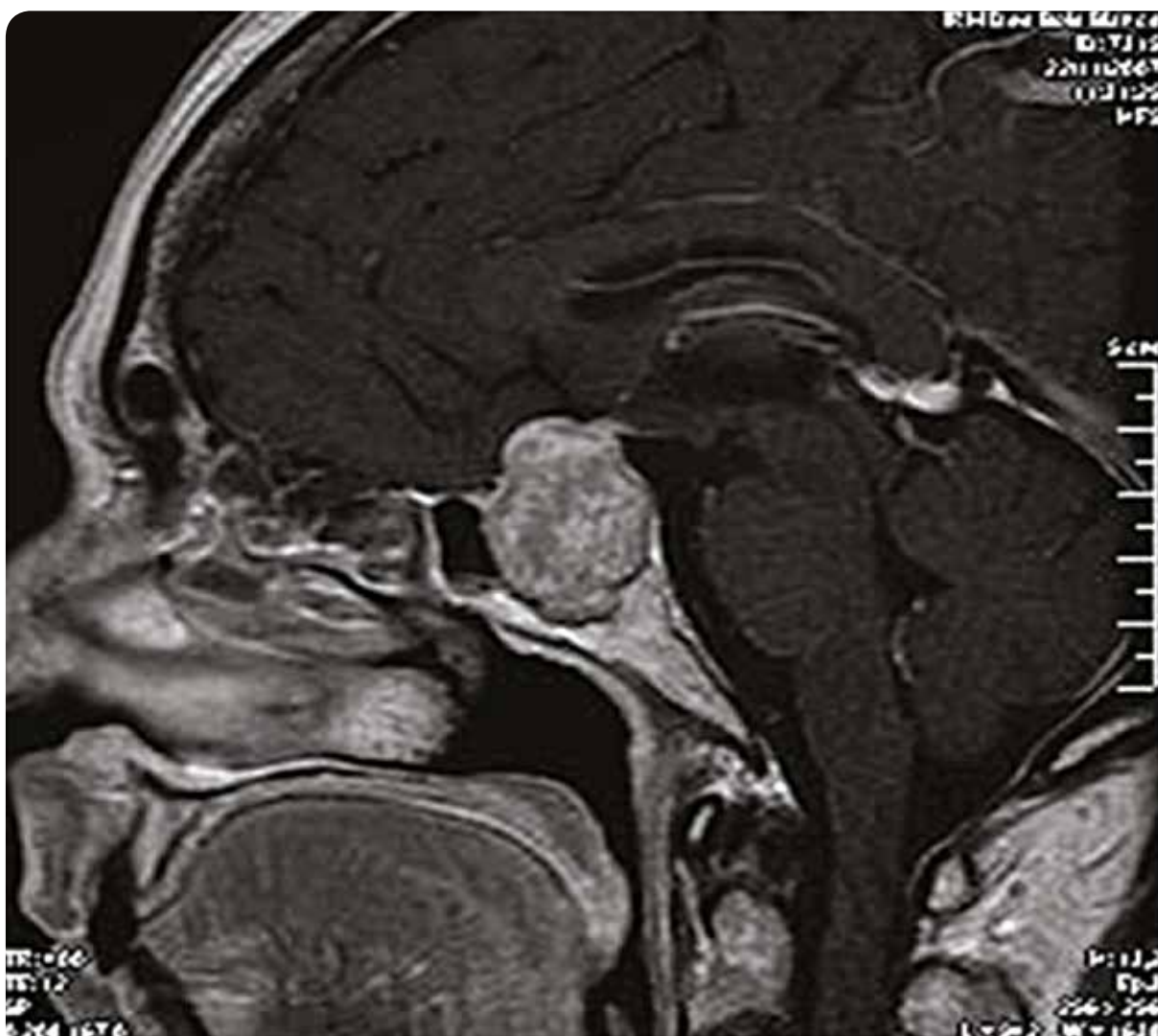

Figure 5: MRI (sagittal slice): pituitary macroadenoma

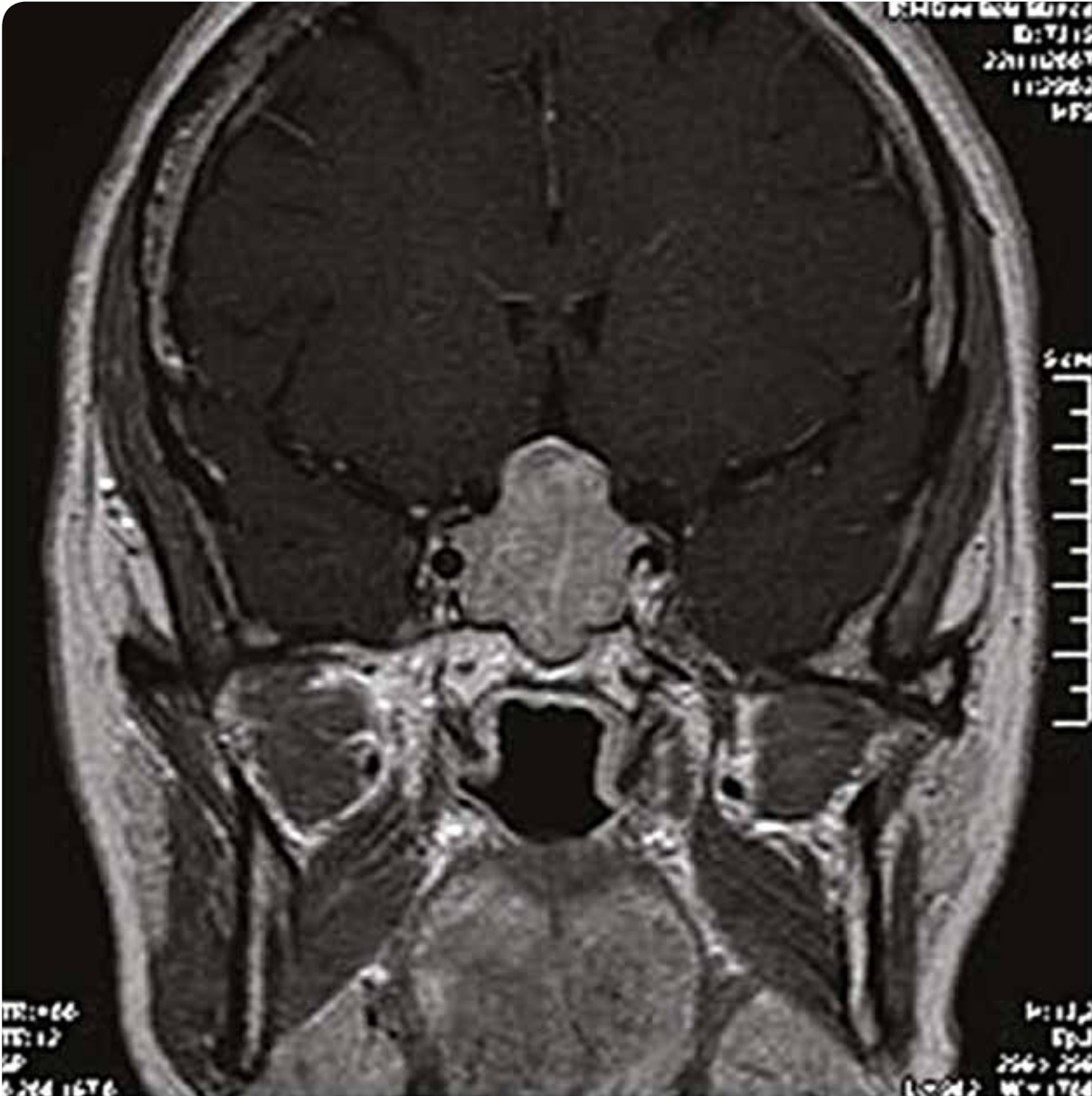


Figure 6: MRI (coronal slice): pituitary macroadenoma

The patient is immediately referred to neurosurgery for management.

He is then seen a few weeks later for a post-operative check-up.

The visual fields are done again (Figures 7 and 8).

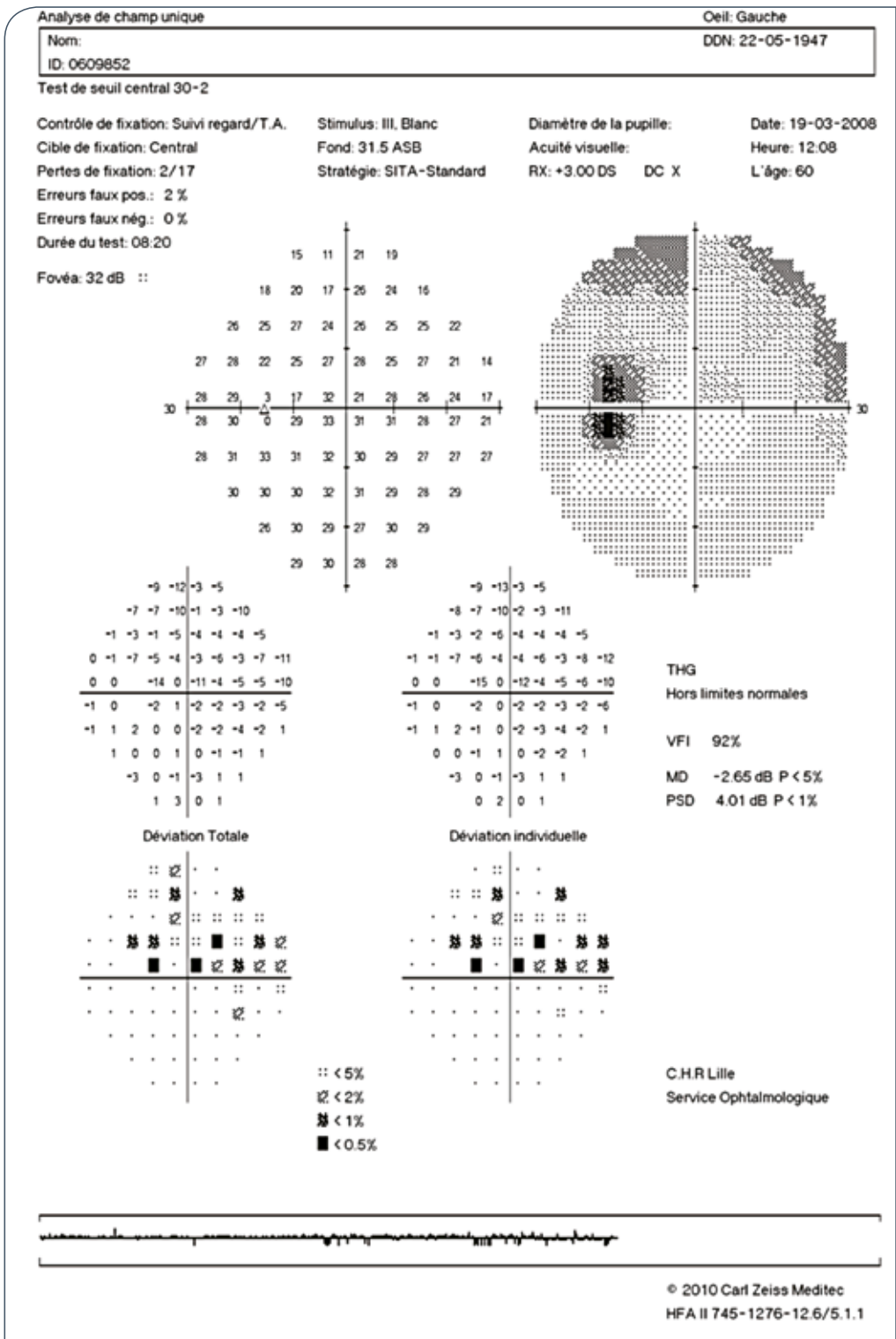


Figure 8: Visual field of the left eye.

Summary of the topic discussed in the case

The decompression of the optic tract has led to a reduction of visual field defects.

Given a discordance between the visual field anomalies and the diagnosis of high or low tension glaucoma, other possible damage of the optic tract should be considered away from the eye ⁽¹⁾.

The factors that suggest a differential diagnosis of normal-tension glaucoma:

- Age under 50 year ⁽²⁾
- Severe decrease of visual acuity ⁽²⁾
- Neuro-retinal ring pallor ⁽²⁾
- No correlation between perimetric deficits and papillary excavation ⁽³⁾

References

1. Greenfield DS., Siatkowski RM. ; Glaser JS. ; Schatz NJ. Parrish II RK.: the cupped disc who needs neuroimaging: Ophthalmology 1998; 105: 1866-1874.
2. L. Laloum : Reconnaître les pièges Les champs visuels pseudo-glaucomeux J. Fr. Ophtalmol., 2007, 30, 5, 3S22-3S30.
3. Ahmed II, Feldman F, Kucharczyk W, Trope GE. Neuroradiologic screening in normal-pressure glaucoma: study results and literature review. J Glaucoma, 2002; 11: 277-86.

Answer to the MCQ on page 161: D



14

Rare but intelligent

Case report

A 62-year-old patient is referred by an ophthalmologist colleague one month after bilateral cataract surgery.

She has a past history of moderate hypermetropia (approximately +2.00 diopters in both eyes).

The cataract surgery was successful with implantation in the capsular bag of a +28.00-diopter implant in the right and left eyes.

The first eye progressed favorably with 20/20 acuity with correction, IOP of 14 mmHg and a quiet and deep anterior chamber.

The second eye operated presents on the other hand a myopization with 20/25 acuity with -4.00 diopters. IOP is 26 mmHg without treatment. The examination of the anterior segment notes a less deep anterior chamber than that of the fellow eye (Figure 1).

The eye fundus examination appears uneventful.

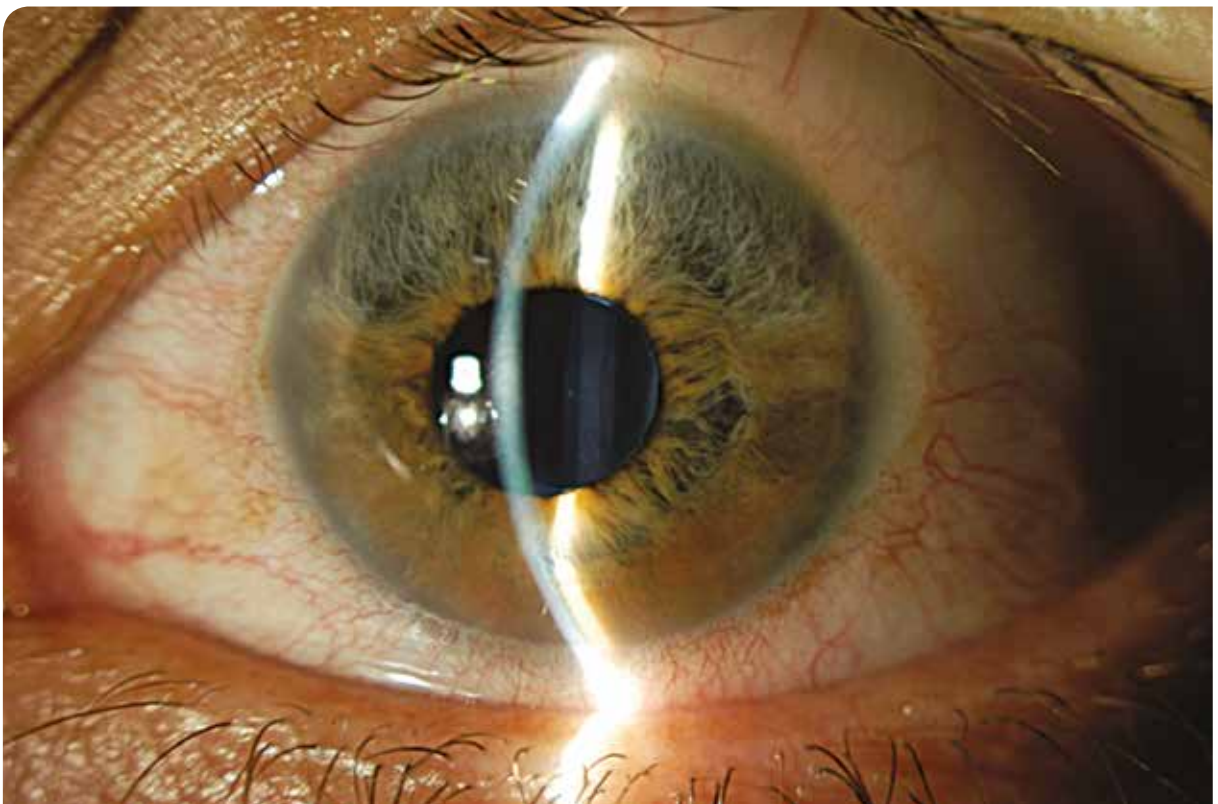


Figure 1: Biomicroscopic exam of the second operated eye.

Multiple choice question

What diagnosis? (one correct answer)

- A. Primary angle-closure glaucoma
- B. Neovascular glaucoma
- C. Malignant glaucoma
- D. Uveal effusion
- E. Acute angle closure crisis

Answer to the MCQ on page 177

Complete case report and answer to the question

Your examination confirms the visual acuity and IOP data.

The gonioscopic exam of the first eye operated reveals an open iridocorneal angle (grade 3 of 360°) but completely closed on the other eye without a marked reopening in dynamic gonioscopy.

An ultra-biomicroscopic exam of both eyes is done (Figures 2 and 3).

Imaging of the anterior segment of the second eye operated shows a forward movement of the entire iris-ciliary body block and implant, which explains the myopisation (implant overhang) and hypertension due to angle-closure, showing it is a mechanism of malignant glaucoma.

In first-line treatment, atropine is prescribed and a Nd: YAG laser capsulotomy scheduled.

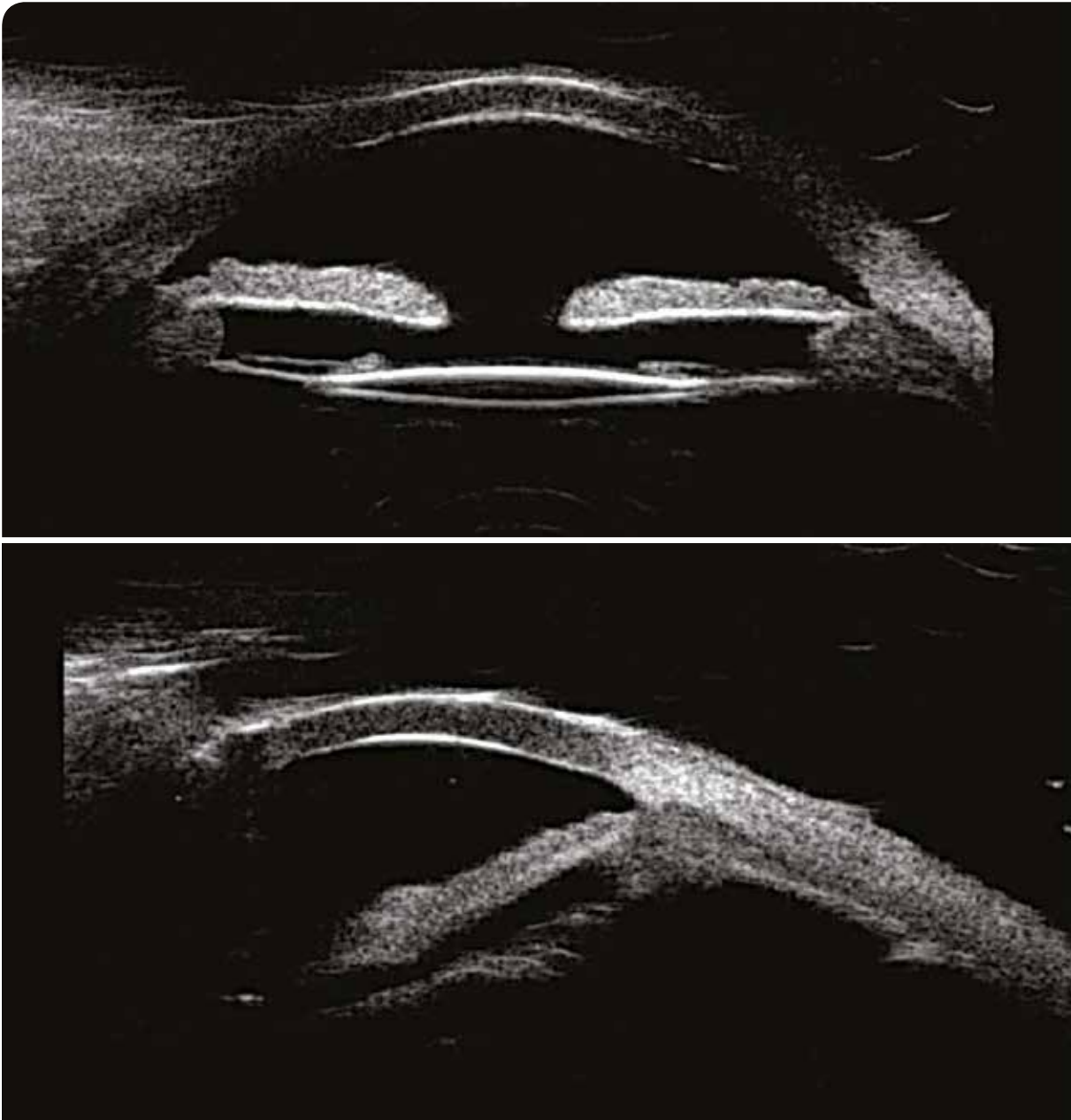

Figure 2: UBM of the first eye.

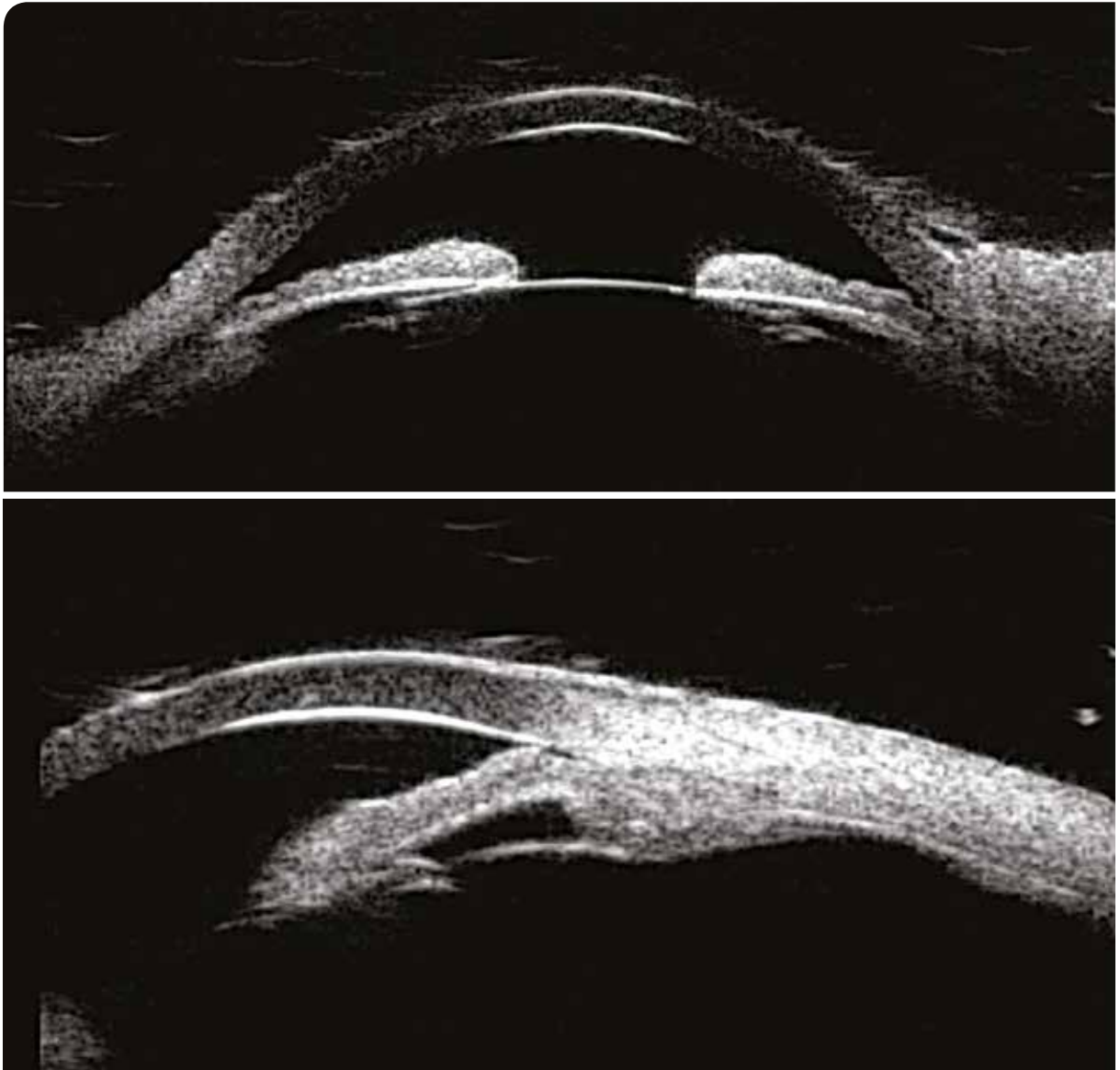


Figure 3: UBM of the second eye.

Summary of the topic discussed in the case

Definition and mechanisms of malignant glaucoma

Malignant glaucoma is an anatomico-clinical entity characterized by an acute or chronic forward displacement of the layer consisting of the iris, ciliary body, zonules and content of the capsular bag, which leads to a flattening of the anterior chamber despite patent iridotomy and iridocorneal angle-closure resulting in ocular hypertension ^(1,2).

The forward displacement of the structures of the anterior segment of the eye is not related to the presence of fluid or blood accumulation in the space between the choroid and the sclera (choroidal detachment, uveal effusion, choroidal hematoma).

It is more likely related to the secretion of aqueous humor in the vitreous through a permeable anterior hyaloid membrane, leading to an increase in volume of the vitreous then a forward displacement of all the structures of the anterior segment.

It is sometimes called cilio-lenticular or cilio-vitreous blockage or “aqueous misdirection” by English speakers.

Circumstances of onset

The onset of malignant glaucoma was initially described as being a complication after surgery for angle-closure glaucoma.

If hypermetropia is probably a risk factor, it appears that all surgery and laser procedures of the anterior segment can lead to the development of a malignant glaucoma^(3,4). Rare cases of drug-induced malignant glaucoma have also been described.

It can occur in phakic, pseudophakic or aphakic eyes. Rare cases of malignant glaucoma in emmetropic or myopic patients have been described.

Following filtration surgery, a post-operative transitory bleb leak appears to be a risk factor.

The risk factors are: hypermetropia, short axial length, female, cataract with narrow anterior chamber and narrow iridocorneal angle with the presence of peripheral anterior synechiae.

Clinical and paraclinical findings

Malignant glaucoma is often symptomatic with a rapid and significant increase in IOP responsible for a decrease in visual acuity and eye pain.

Abnormal asymptomatic or paucisymptomatic forms are nevertheless possible. Onset delay after the triggering procedure is variable.

The clinical examination reveals ocular hypertension, flattening of the anterior chamber, forward protrusion of the lens or intraocular implant (sometimes with subluxation or anterior luxation of these structures), and iridocorneal angle-closure sometimes associated with the presence of peripheral anterior synechiae. The presence of an iridotomy or patent iridectomy is normally indispensable for the diagnosis.

The fundus examination must not reveal any uveal effusion or choroidal hematomas. When filtration surgery is the triggering factor, the filtering bleb can be functional and must not show signs of bleb leak.

Management

A hypotensive medical treatment (local and/or systemic) is initiated to reduce IOP⁽⁵⁻⁸⁾. Treatment with cycloplegic (atropine) eye drops can often deepen the anterior chamber and improve the anatomy of the eye. Modification of the conformation of the ciliary body can help to restore a normal flow of aqueous humor to the posterior chamber then to the anterior chamber.

When medical treatment is not sufficient in a pseudophakic patient, Nd: YAG laser capsulotomy can also be performed to restore circulation of aqueous humor from the vitreous chamber to the anterior segment.

Lastly, in the case of drug-resistant malignant glaucoma, surgery can be envisaged.

Numerous techniques have been proposed. Vitrectomy as complete as possible eventually combined with lens extraction in a phakic patient appears to be the surgical technique most suitable for the pathophysiology of this disease.

Some authors have reported the efficacy of laser or ultrasound cyclo-coagulation, which can probably also reduce the volume of the ciliary body and modify the circulation of aqueous humor in the eye⁽⁹⁾.

References

1. Chandler PA, Simmons RJ, Grant MW. Malignant glaucoma, medical and surgical treatment. *Am J Ophthalmol*, 1968; 66: 495-502.
2. Epstein DL. The malignant glaucoma syndromes in Chandler and Grant's *Glaucoma* (4th edition) Williams et Wilkins 285-303.
3. Razeghinejad MR, Amini H. Lesser anterior chamber dimensions in women may be predisposing factor for malignant glaucoma. *Med hypotheses*, 2005; 64: 572-4.
4. Schwartz AL, Anderson DR. Malignant glaucoma in an eye with no antecedent operation or miotics. *Arch Ophthalmol*, 1975; 93: 379-81.
5. Tsai J, Barton KA, Michael M. et al. Surgical results in malignant glaucom refractory to medical or laser therapy. *Eye*, 1997; 11: 677-81.
6. Lynch M, Brown RH, Michels RG. et al. Surgical vitrectomy for pseudophakic malignant glaucoma *Am J Ophthalmol*, 1986; 102: 149-53.
7. Byrnes GA, Leen MM, Wong TP. et al. Vitroctomy for ciliary block (malignant) glaucoma. *Ophthalmology*, 1995; 102: 1308-11.
8. Bresson Dumont H, Ballereau L, Lehoux A, Santiago PY. Diode laser in "Malignant Glaucoma" treatment. *J Fr Ophtalmol*. 2006 May; 29 Spec No 2: 73-7.

Answer to the MCQ on page 171: C



15

An ice storm

Case report

Miss P, 19-year-old, is referred by her treating ophthalmologist.

She consulted him for the first time 3 months before for headaches and pain in the left eye.

At the interview, she reported episodes of paroxysmal hemicrania with aura.

At her first exam, visual acuity is 20/20 without correction in both eyes at both distance and near.

The biomicroscopic exam appears normal in both eyes.

Intraocular pressure (IOP) is measured at 12 mmHg in the right eye and 55 mmHg in the left.

The eye fundus appears normal in both eyes.

IOP lowering drugs combining alpha agonist and carbonic anhydrase inhibitors is initiated.

After 15 days IOP is 11 mmHg in the right eye and 15 mmHg in the left eye for a pachymetry of 560 μm in the right and 680 μm in the left.

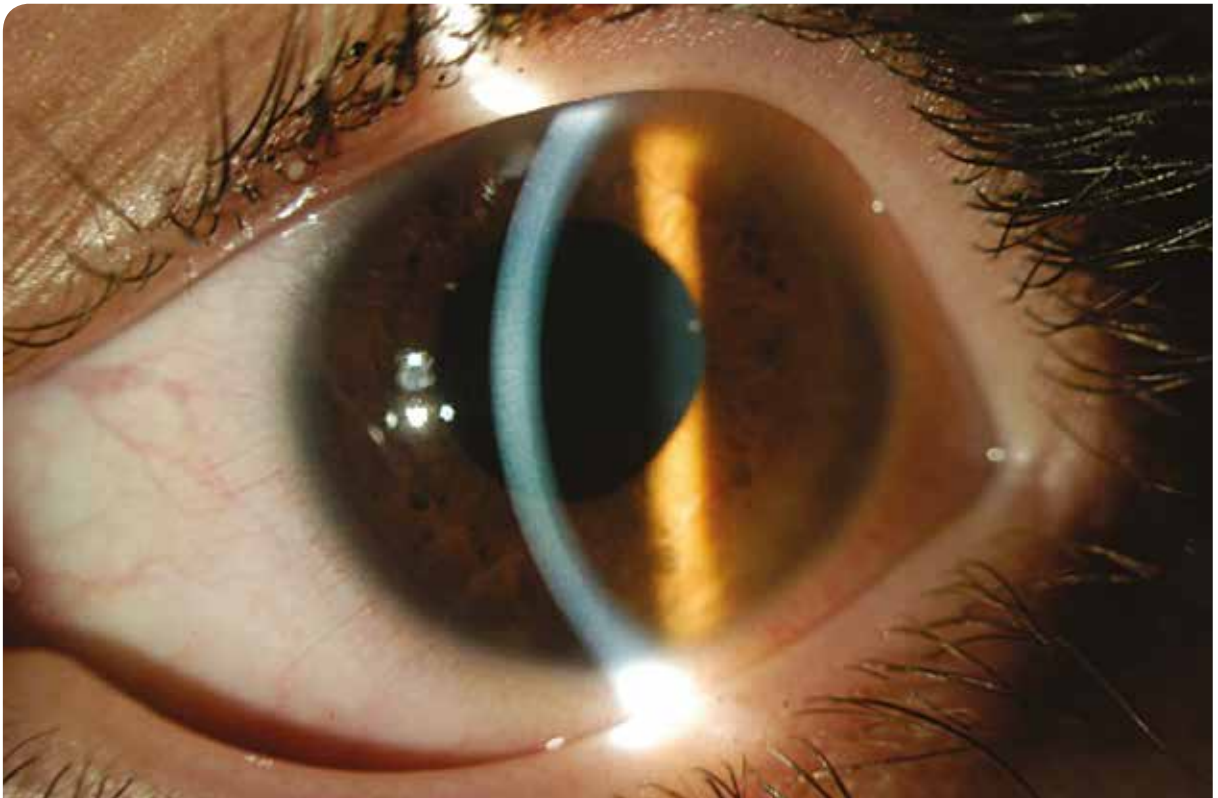


Figure 1: Left eye.

Multiple choice question

What situation can explain unilateral paroxysmal hypertension in this young patient? (one correct answer)

- A. Primary angle-closure glaucoma
- B. Acute anterior uveitis
- C. ICE Syndrome
- D. Juvenile glaucoma
- E. Plateau iris syndrome

Answer to the MCQ on page 193

Complete case report and answer to the question

Visual acuity in the left eye under IOP lowering drops is 20/20 without correction for distance and near vision.

The biomicroscopic exam reveals a discreet corneal opalescence (Figures 2 and 3) explaining the difference in measurement of corneal thickness: 560 μm vs 680 μm .

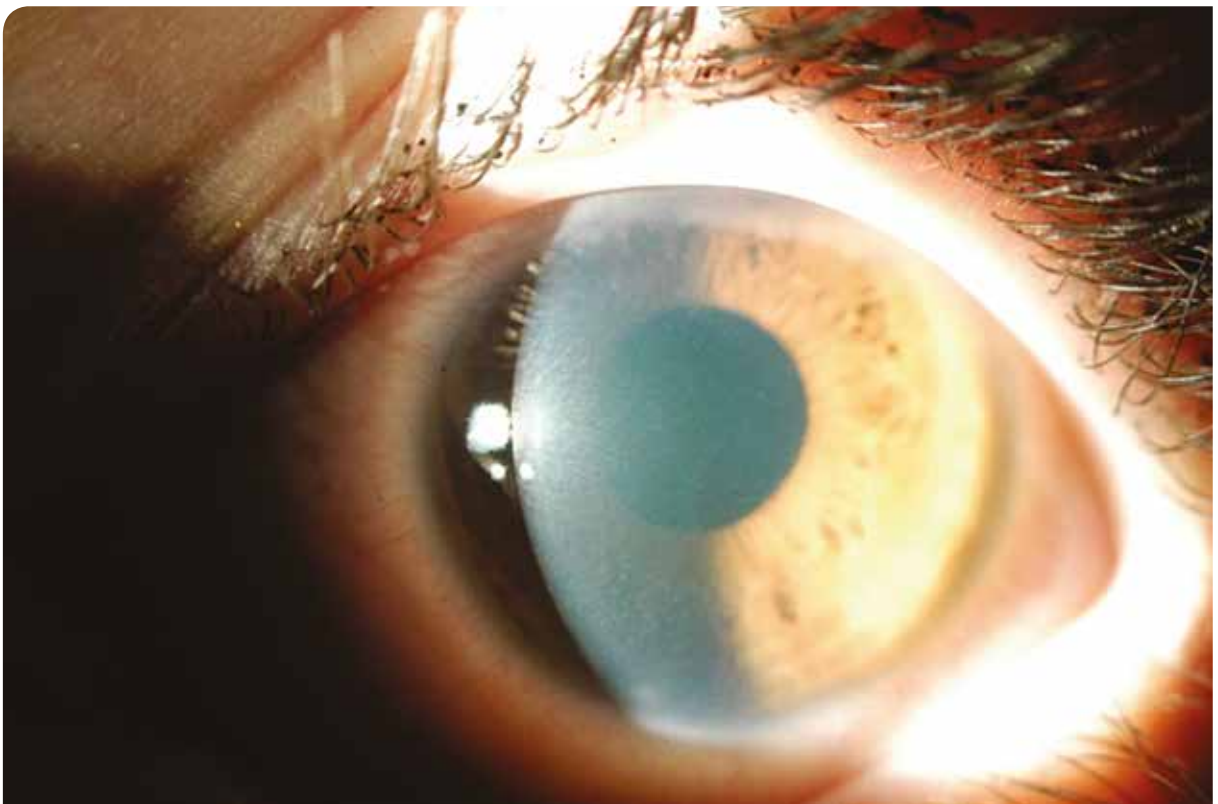


Figure 2: Left eye: moderate corneal edema.




Figure 3: Left eye: zoom on microcystic edema of the left cornea.

Gonioscopy is normal in the right but reveal peripheral anterior synechiae in the left (Figures 4 and 5).




Figure 4: Gonioscopy of the left eye: peripheral synechia.




Figure 5: Gonioscopy of the left eye: open-angle at a distance from the synechia.

The optic nerve head appears normal in both eyes (Figures 6 and 7).

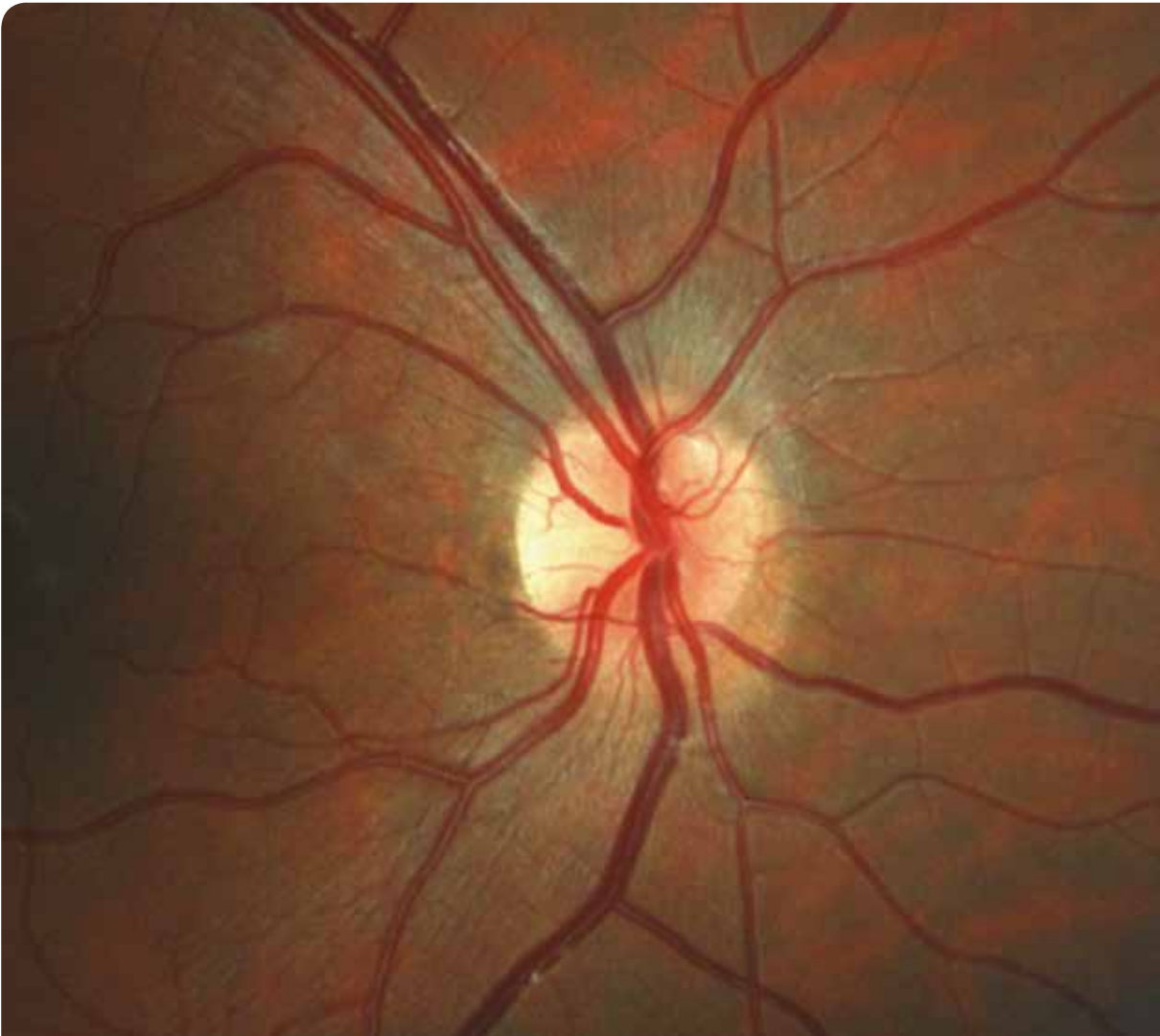

Figure 6: Normal right optic disc.

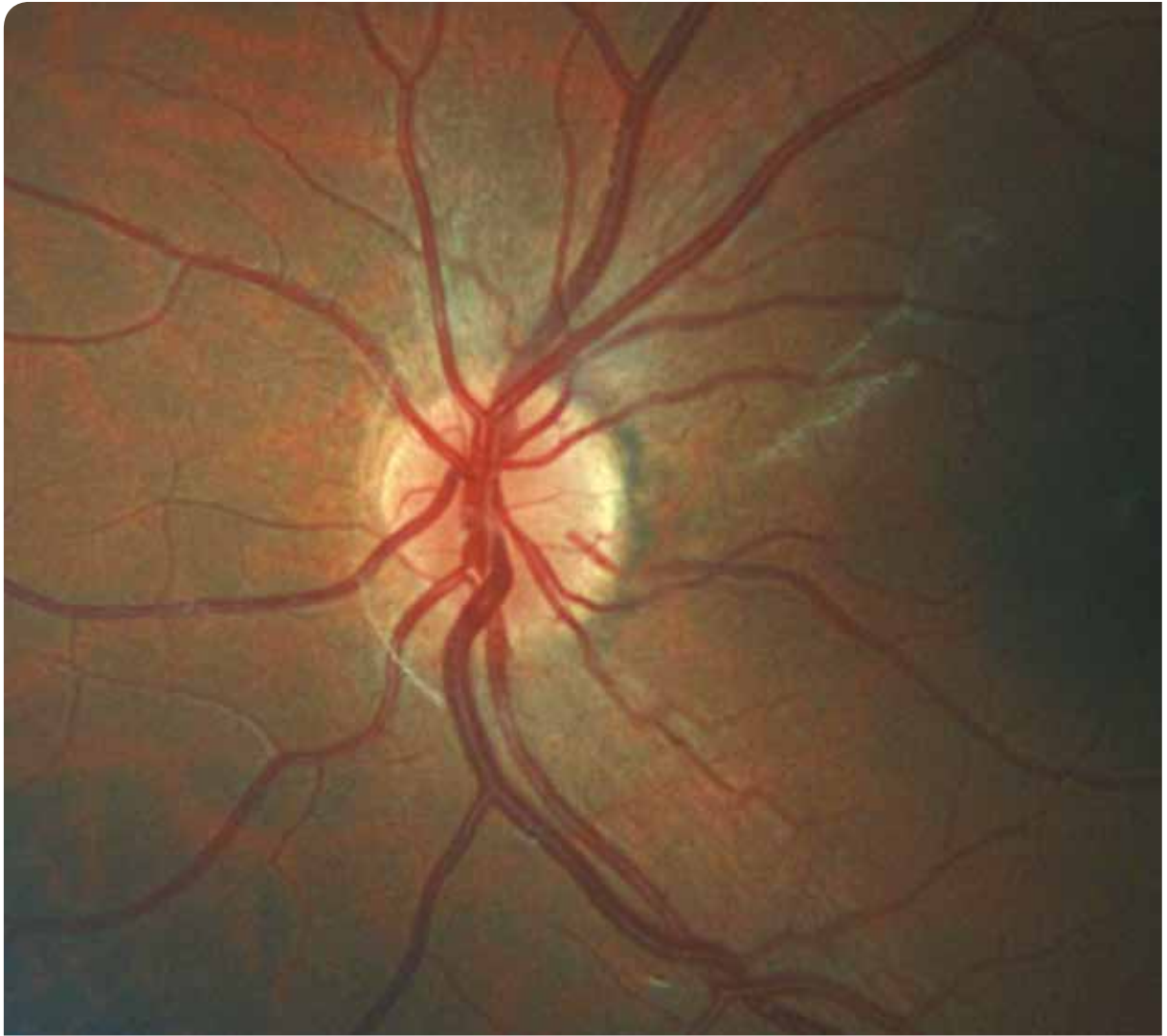

Figure 7: Normal left optic disc.

Visual fields are done (Figures 8 and 9):

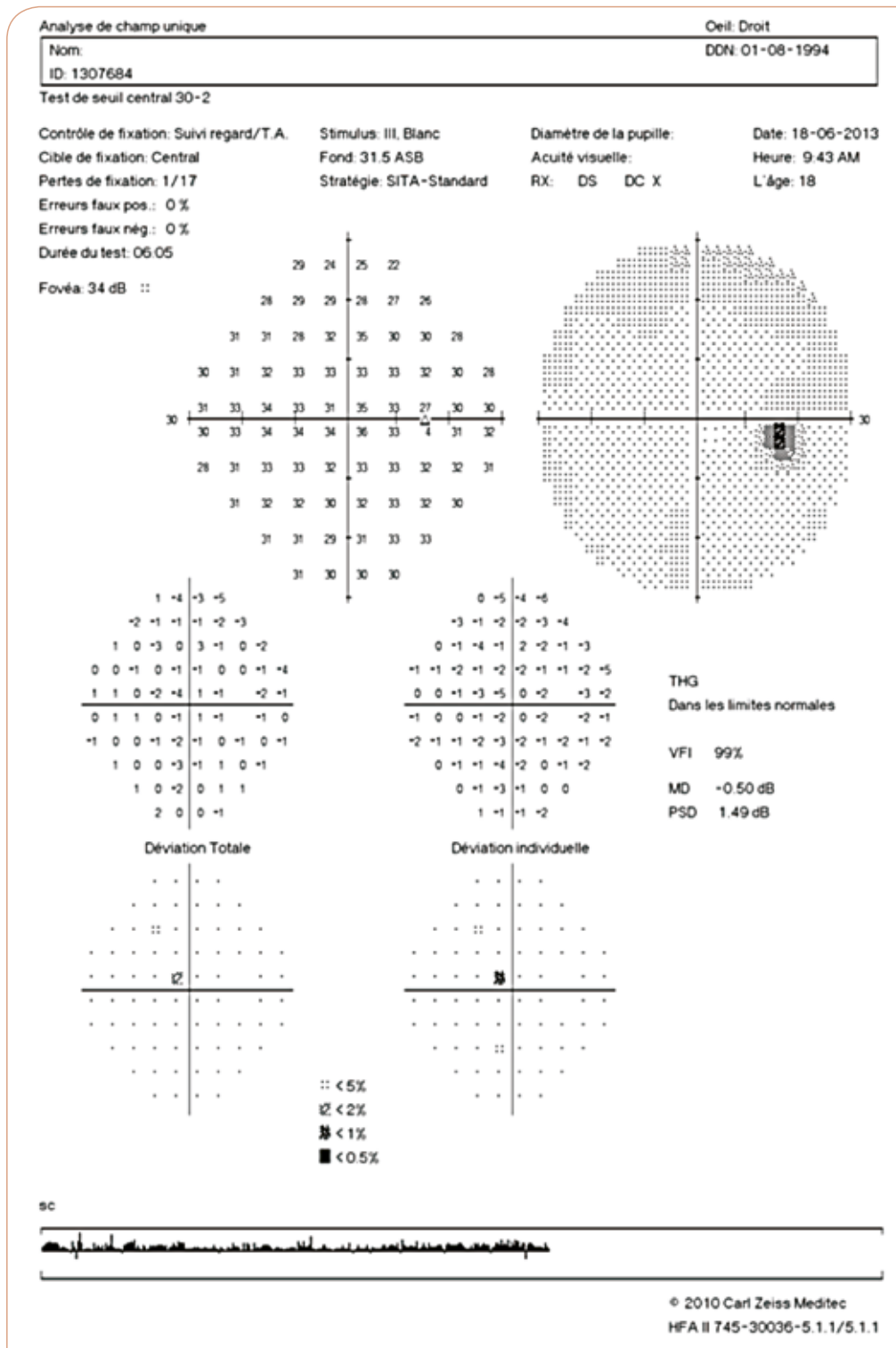


Figure 8: Normal right visual field.

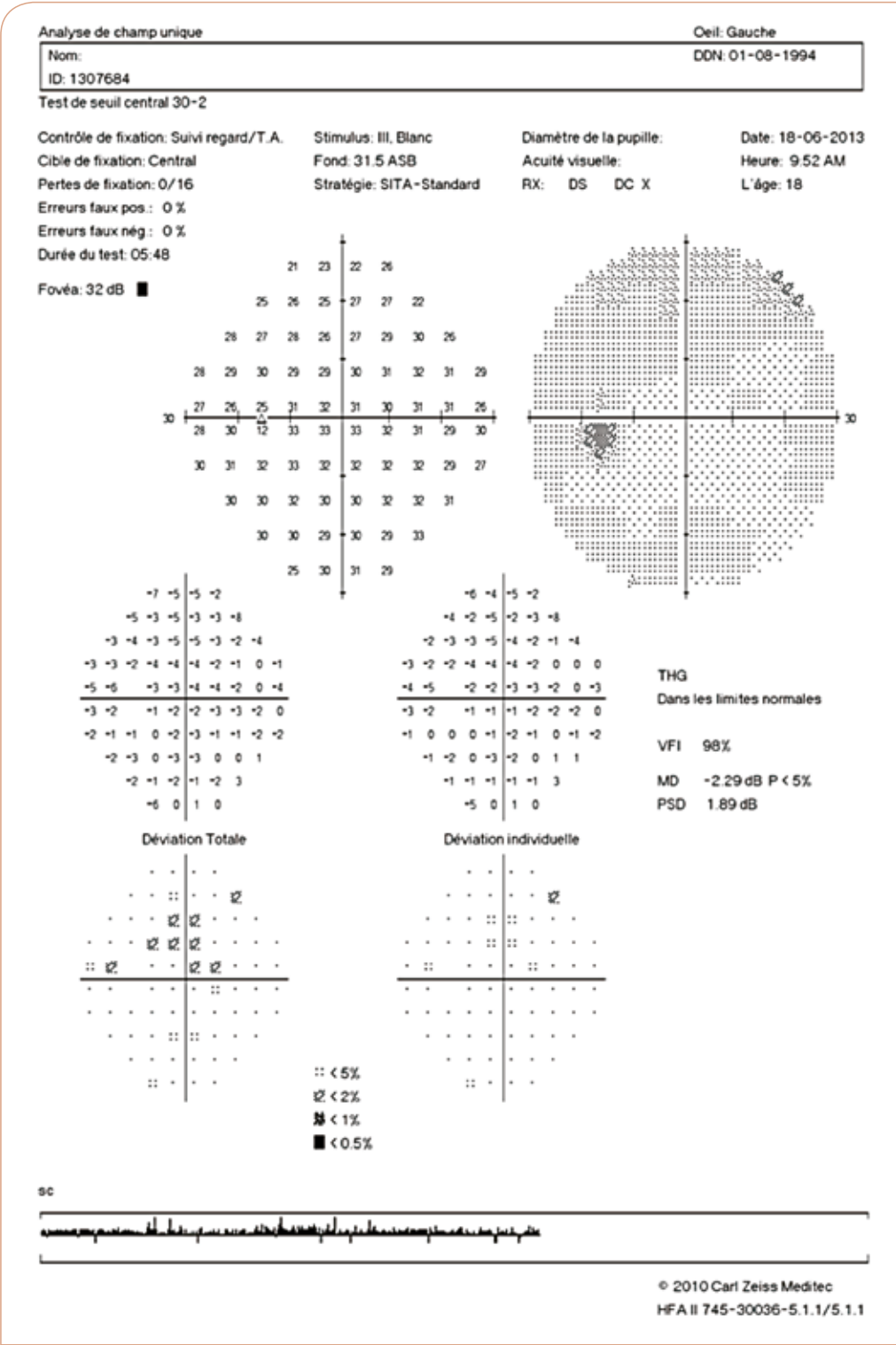


Figure 9: Normal left visual field.

Optical coherence tomography confirms the absence of damage in the structure of the left eye (Figures 10 and 11), on examination of the fibers as well as the ganglion cell complex.

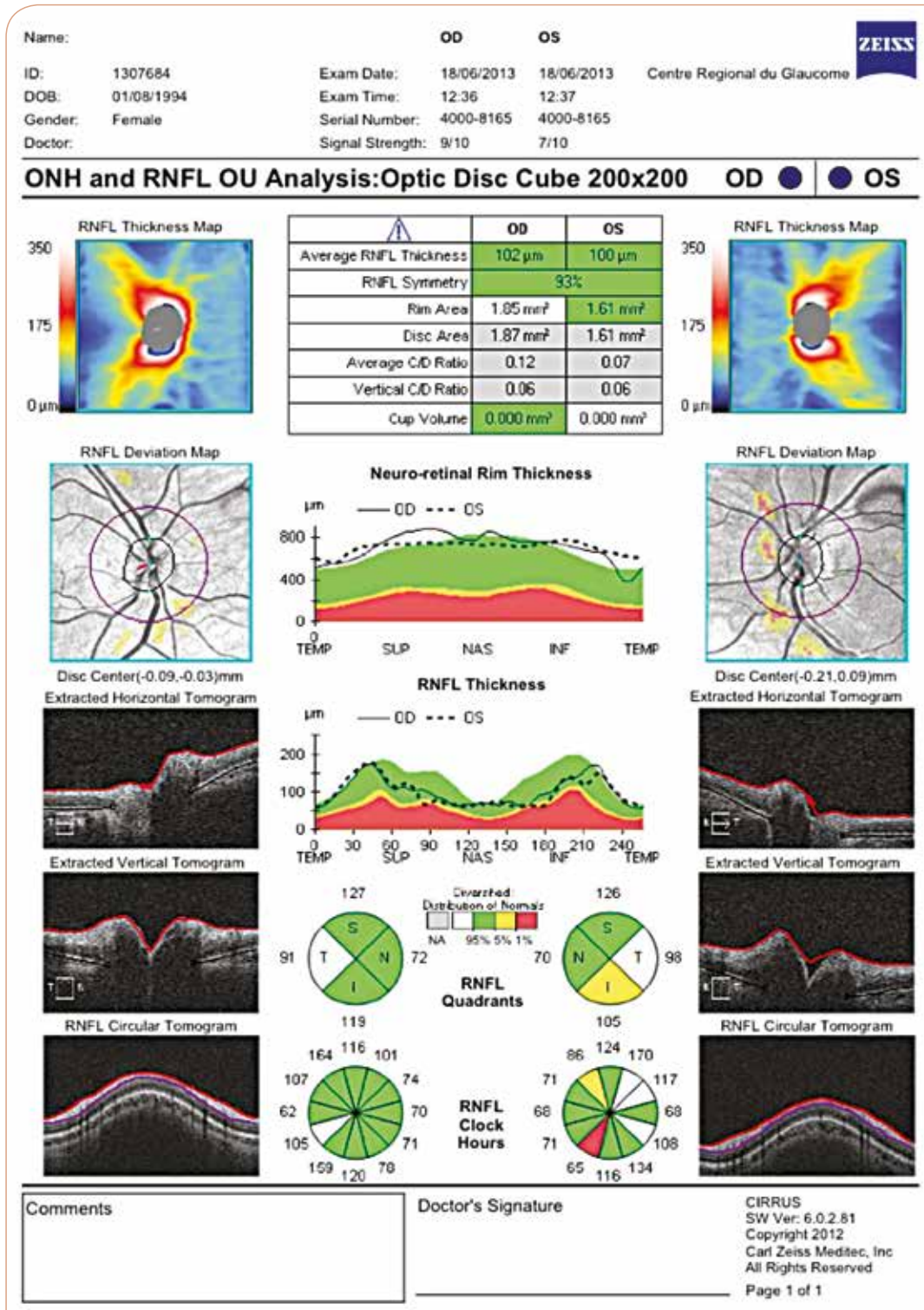


Figure 10: OCT RNFL normal in both eyes.

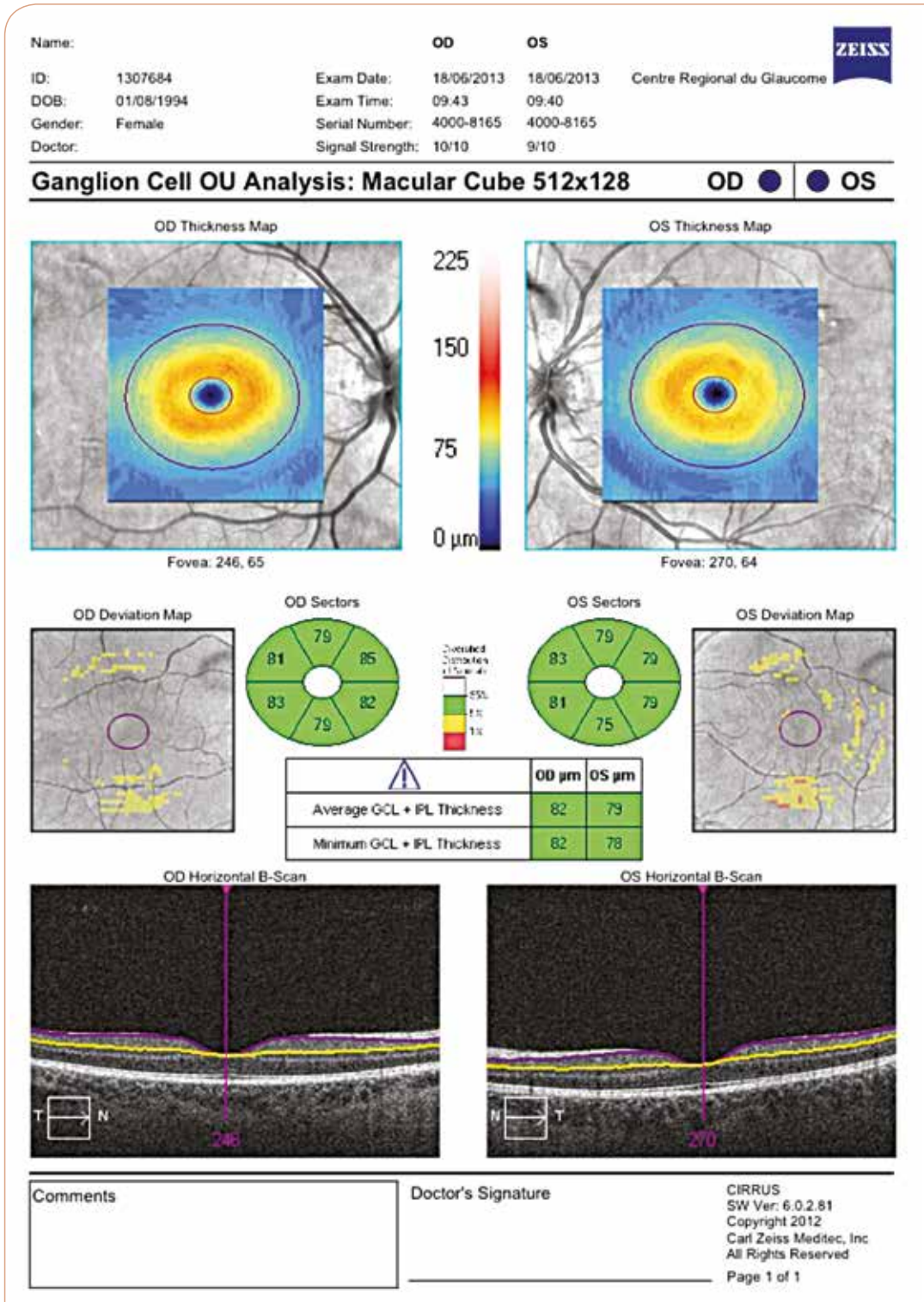


Figure 11: OCT GCC normal in both eyes.

Specular microscopy confirms the diagnosis in presence of an acute paroxysmal hypertension, unilateral corneal edema, angular synechiae outside any inflammatory context and a unilateral pseudo-epithelial appearance of corneal endothelial cells (Figures 12 and 13).

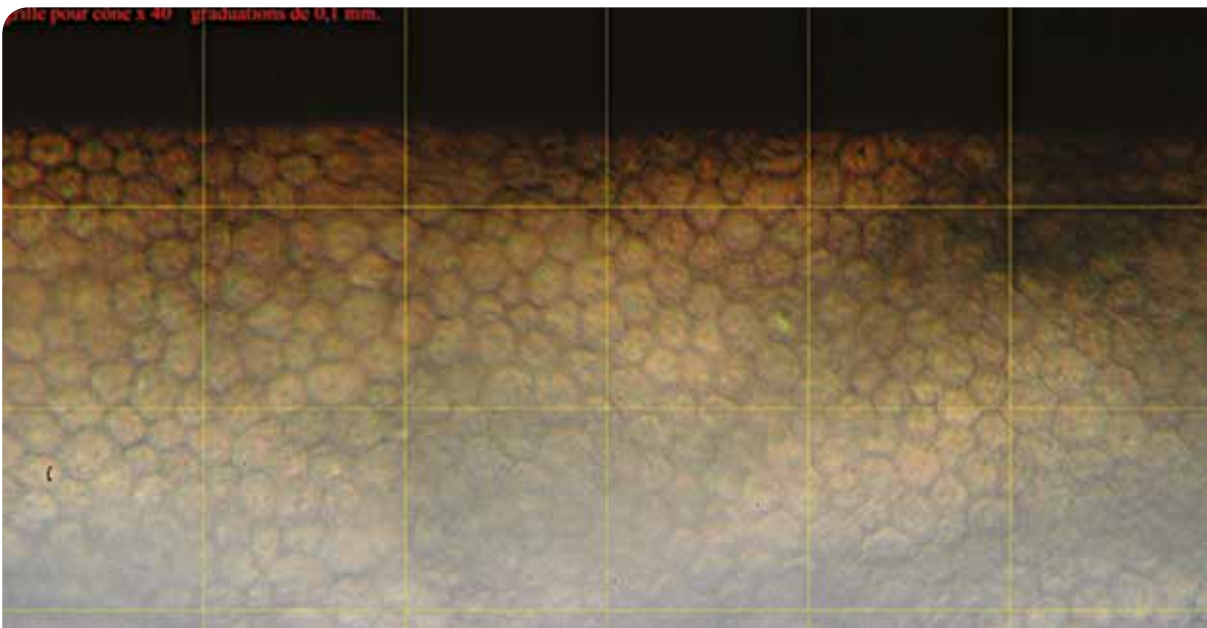


Figure 12: Normal right corneal endothelial cells.




Figure 13: Epithelial-like appearance of the left corneal endothelial cells.

Summary of the topic discussed in the case

Chandler's syndrome is confirmed by the exam.

Under unchanged medical treatment intraocular pressure is stable without damage to function and structure.

ICE syndrome or endothelial iridocorneal syndrome is a group of three different clinical expressions: Chandler's syndrome, Essential Iris Atrophy and Cogan-Reese syndrome or Iris Nevus ⁽¹⁾.

If the etiology of these diseases is still being discussed (Herpesvirus or Epstein-Bar viral infections), damage to the endothelium that is replaced by pseudo-epithelial with a migration capacity that will reach the angle explains the peripheral synechiae and trabecular meshwork damage responsible for ocular hypertension ⁽²⁾.

Among the differential diagnoses are polymorphous posterior dystrophy, Axenfeld Rieger syndrome and aniridia.

The treatment of ocular hypertension is first and foremost medical, filtration surgery with anti-metabolites or even valves gives modest long-term results. Cyclodestruction can be proposed for this often-unresponsive glaucoma ⁽³⁾.

References

1. Laganowski HC, Kerr Muir MG, Hitchings RA. Glaucoma and the iridocorneal endothelial syndrome. *Arch Ophthalmol*. 1992 Mar; 110(3): 346-50.
2. Levy SG, Kirkness CM, Moss J, Ficker L, McCartney AC. The histopathology of the iridocorneal-endothelial syndrome. *Cornea*. 1996 Jan; 15(1): 46-54.
3. Doe EA, Budenz DL, Gedde SJ, Imami NR. Long-term surgical outcomes of patients with glaucoma secondary to the iridocorneal endothelial syndrome. *Ophthalmology*. 2001 Oct; 108(10): 1789-95.
4. https://eyewiki.org/Iridocorneal_Endothelial_Syndrome_and_Secondary_Glaucoma

Answer to the MCQ on page 181: C



16

Trivial

Case report

A 62-year-old patient consults for episodes of right eye pain that occurs in the evening or sometimes at night.

She has no personal or family history and is not under treatment.

She had cataract surgery in the left eye 5 year before and has not been seen since.

She complains of episodes of eye pain occurring recurrently in the right eye, in the evening or even at night, for several year. She does not complain of vision loss.

At the examination IOP is 16 mmHg in the right eye and 13 mmHg in the left and acuity 20/25 in the right and 20/20 in the left with a mild astigmatism correction.

At the slit lamp test, she is indeed phakic in the right and pseudophakic in the left eye.

Gonioscopy is performed (Figure 2) as well as an eye fundus exam (Figure 3).




Figure 1: Gonioscopy of the right eye.

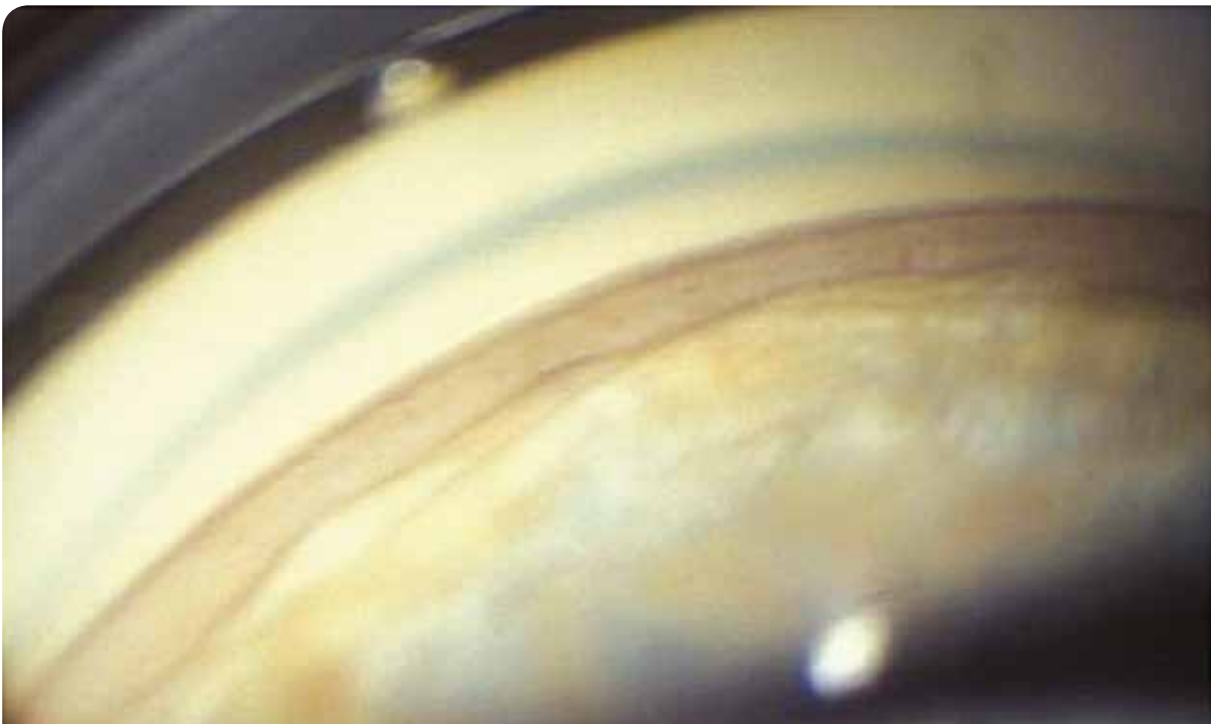


Figure 2: Gonioscopy of the left eye.

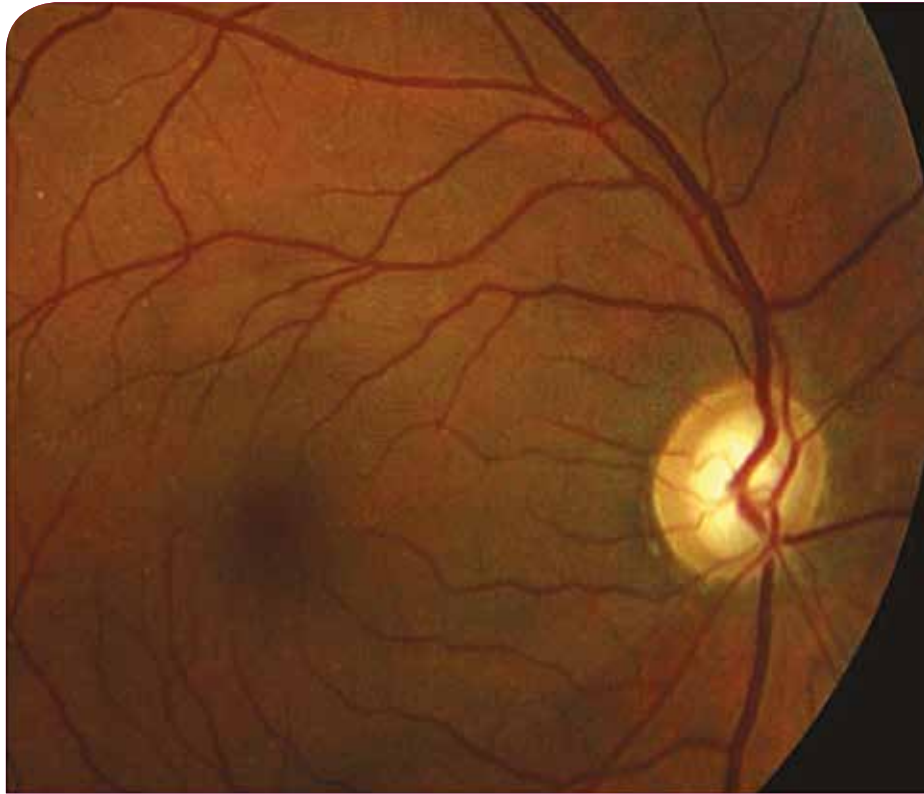


Figure 3: Right eye fundus.

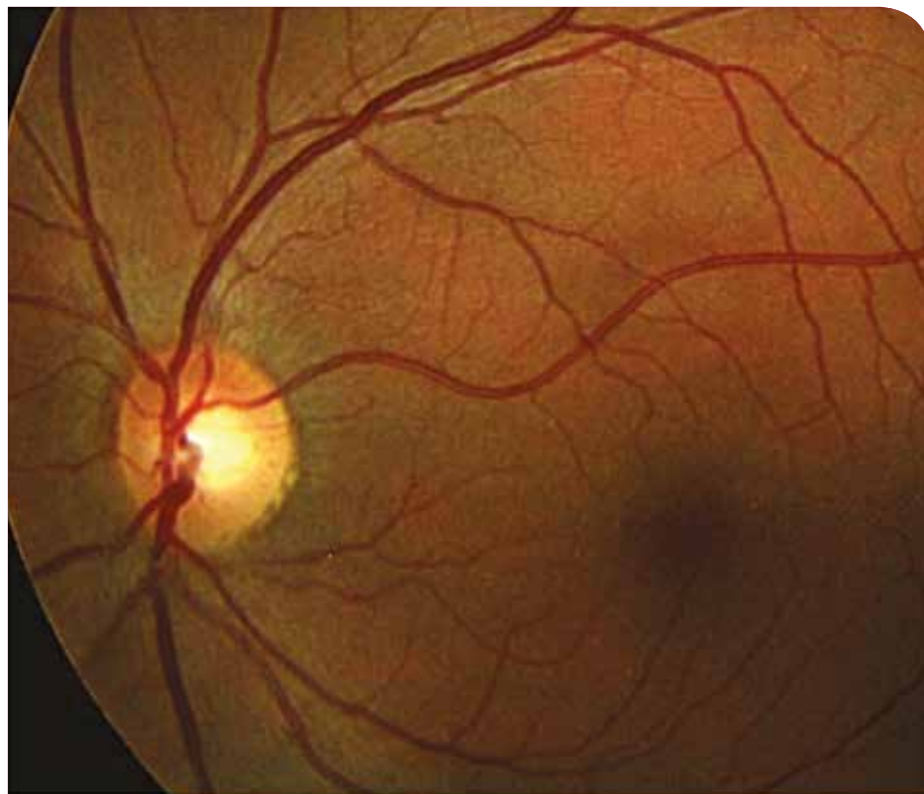


Figure 4: Left eye fundus.

Multiple choice questions

1 What is your diagnosis? (one correct answer)

- A. Mixed glaucoma
- B. Primary angle-closure glaucoma
- C. Angle recession
- D. Fuchs syndrome
- E. Plateau iris syndrome

2. What is your treatment of the right eye (one correct answer)

- A. Laser iridotomy
- B. Laser trabeculoplasty
- C. Cataract surgery
- D. Fixed-combination prostaglandin and beta blocker
- E. Filtration surgery

Answers to the MCQ on page 205

Complete case report and answer to the question

The gonioscopic exam finds a narrow iridocorneal angle in the right eye with Grade 1 visibility of Schwalbe's ring (grade 1) or of trabecular meshwork (grade 2).

The iris surface is convex, revealing a relative pupillary block. Dynamic gonioscopy finds an apposition of the iris on the trabecular meshwork over the majority of the angular circumference without the formation of synechiae. The exam of the left eye (pseudophakic) finds an open iridocorneal angle (Grade 4) and a flat iris.

The examination of optic disc at fundus and by OCT, as well as white-on-white visual field shows the existence of a glaucomatous neuropathy in the right eye. Function and structure exams are normal in the left eye.

Therefore, diagnosis of primary angle-closure glaucoma in the right eye is submitted. Right eye pain is probably due to episodes of angle-closure in obscurity, leading to a sudden and symptomatic increase of IOP.

Cataract surgery, performed in the left eye 5 year before, removed the relative pupillary block related to the increase in volume of the lens with age and prevented the development of an angle-closure in the left eye.

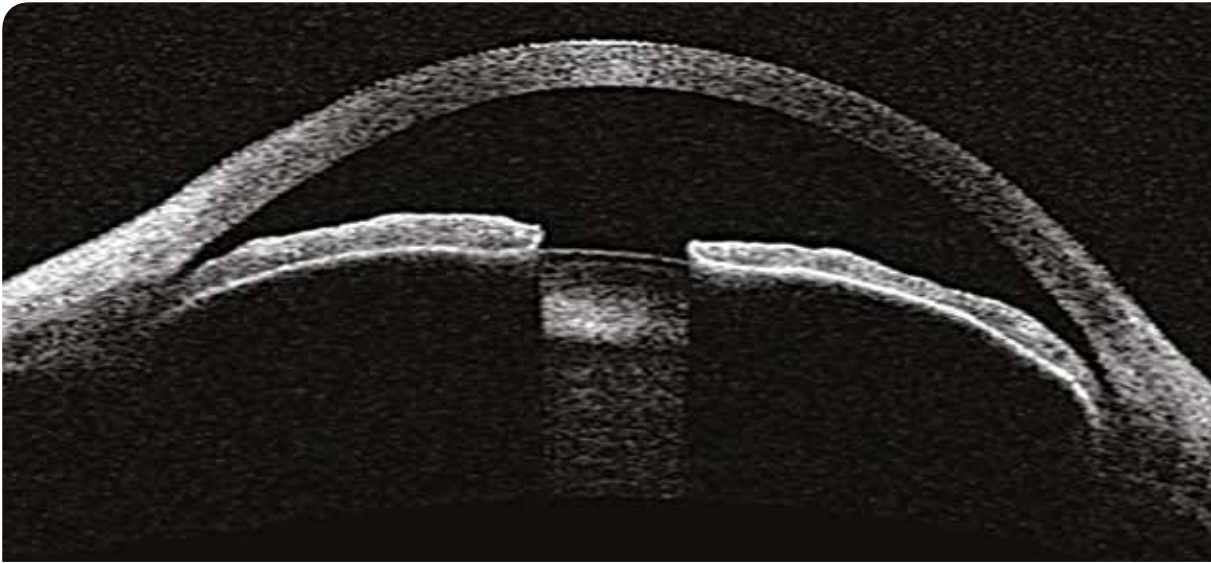


Figure 5: OCT of the anterior segment.

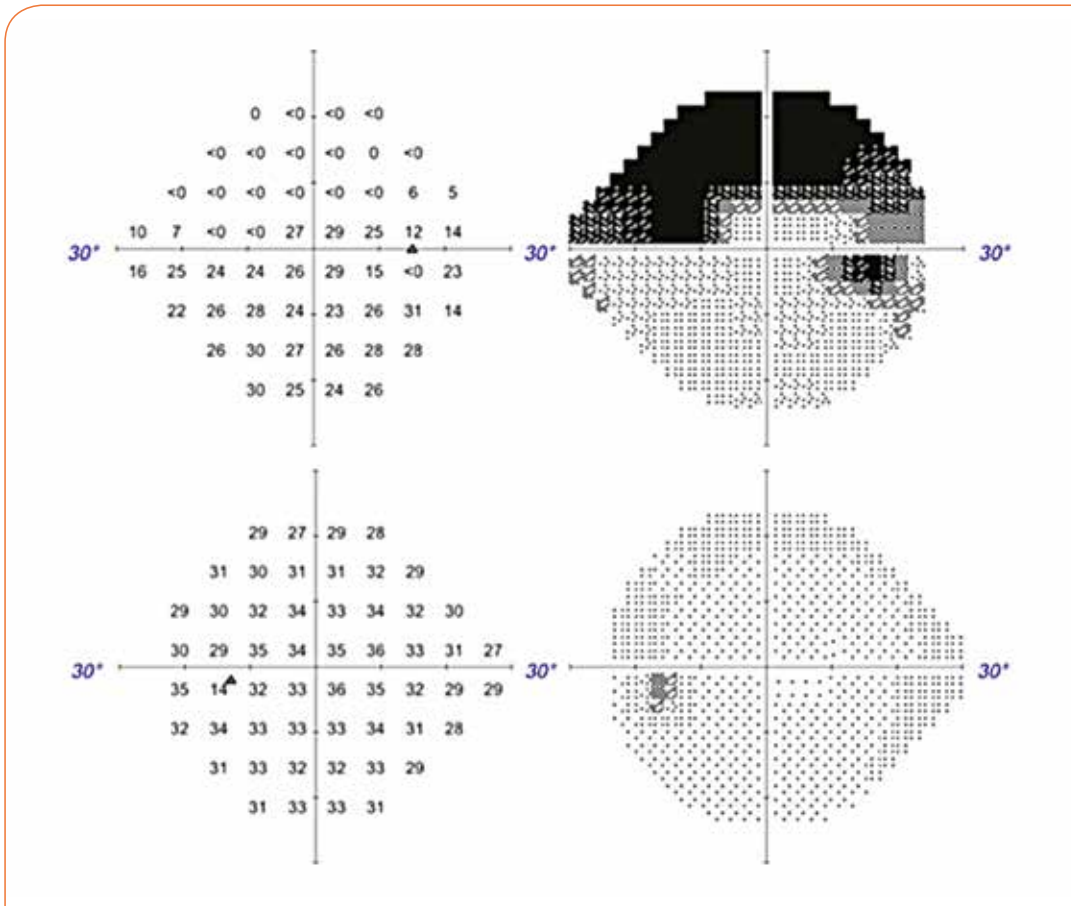


Figure 6 : 24-2 white-on-white visual field.

Summary of the topic discussed in the case

1. Mechanisms of angle-closure glaucoma

The relative pupillary block - proximity of the anterior surface of the lens and posterior surface of the iris leading to an increase of resistance to aqueous humor flow then a pressure gradient pushing the root of the iris towards the trabecular meshwork - is the main mechanism of angle-closure glaucoma. The pressure gradient pushes the root of the iris forward and partially or completely closes the iridocorneal angle, preventing drainage of the aqueous humor. Initially the apposition between the iris and trabecular meshwork is reversible (simple apposition).

Over time, apposition becomes irreversible, due to the formation of anterior synechiae. The increase of intraocular pressure by angle-closure can be chronic (chronic forms) or acute (acute forms), and eventually leads to optic neuropathy (acute or chronic primary angle-closure glaucoma).

The onset of a relative pupillary block is favored by certain anatomical characteristics such as short axial length, shallow depth of the anterior chamber, substantial lens thickness, anterior lens position, etc. In this regard, the increase of lens volume with age often plays an important role in the development of a pupillary block and angle closure.

Many recent studies have shown that anterior uveal anomalies - variations of iris volume during pupil dilation - and posterior - thickness and volume of the choroid - also participate in the genesis of iridocorneal angle closure and may explain that a small percentage of eyes presenting biometric predispositions develop an angle closure, whereas the majority do not develop one⁽¹⁾.

2. Epidemiology

Epidemiological studies have shown that angle-closure glaucomas represent approximately one-third of the total number of glaucomas worldwide.

In Europe and the USA, angle-closure glaucomas represent 10 to 20% of all forms of glaucoma (80 to 90% of POAG).

In Asia (China, South-East Asia, Mongolia, etc.), angle-closure glaucomas represent up to 50% of all forms of glaucoma (only 50% of PAOG). Thus, primary angle-closure glaucoma affects approximately 15 to 20 million people, among which 4 to 5 million suffer from bilateral blindness. This form of glaucoma can therefore be considered to be more severe than open-angle glaucoma, because it leads more frequently and earlier to loss of vision.

In Asia, chronic angle-closure glaucoma is much more frequent than acute and symptomatic angle-closure crisis. Therefore, a study reports an incidence of acute angle-closure crisis in Hong Kong of only 10 new cases per 100,000 inhabitants per year, far lower than the prevalence of angle-closure glaucoma in these countries (1 to 5% of the population) ⁽²⁾.

There are few similar studies in Europe, but it is likely that chronic angle-closure glaucoma is also more frequent than acute symptomatic crisis, even if the fact that they are often poorly diagnosed and identified mistakenly as open-angle glaucomas might suggest the contrary.

3. Management

Iridotomy

Peripheral laser iridotomy consists of perforating the root of the iris by focusing one or more laser beams on it in order to create an orifice large enough to enable the unobstructed drainage of aqueous humor from the posterior chamber to the anterior chamber, preventing or removing a permanent or definitive apposition of the iris to the trabecular meshwork (Figure 7).

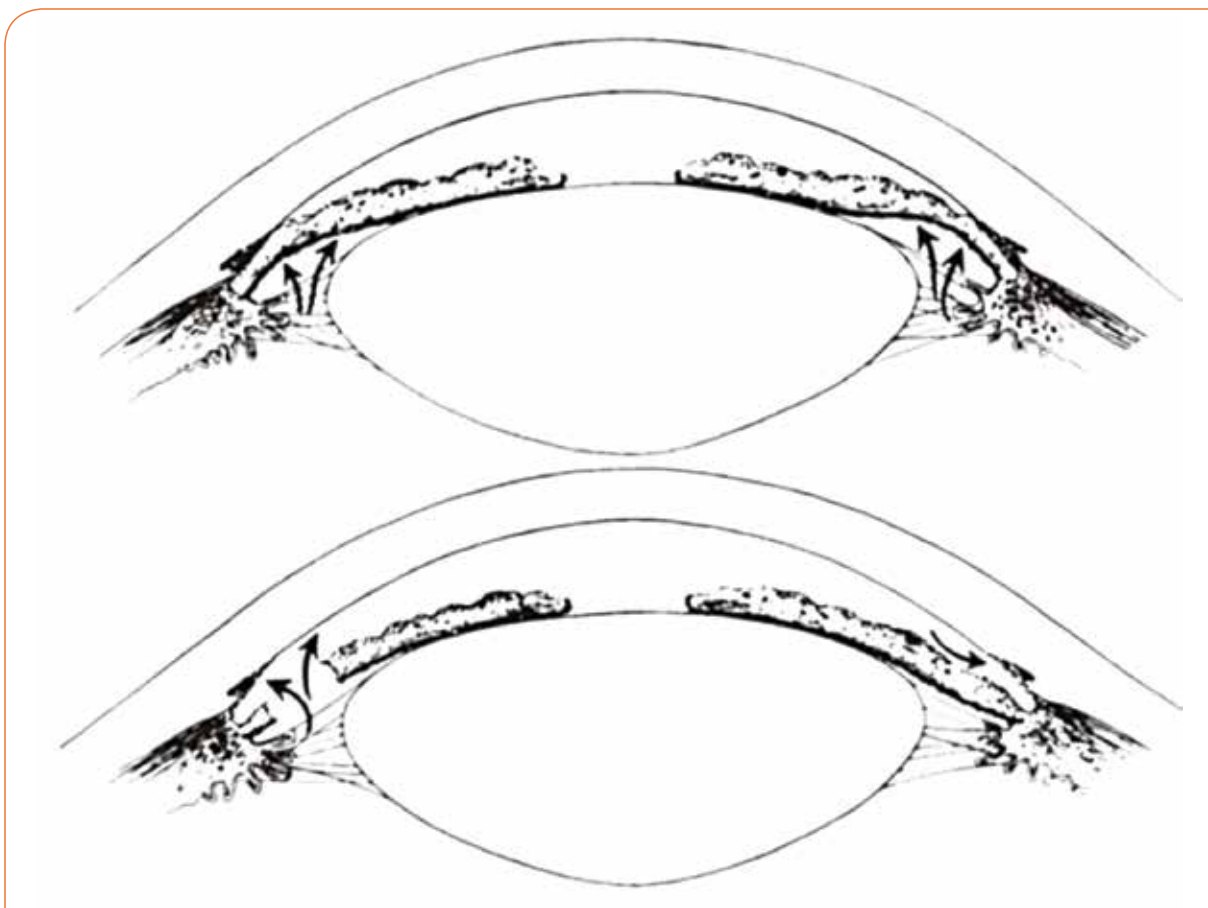


Figure 7: Mechanism of action of laser iridotomy in the event of pupillary block. According to Kolker AE⁽³⁾.

For a long time, laser iridotomy was considered as a procedure for first-line therapy for curative treatment of an acute angle-closure crisis, curative treatment for chronic angle-closure glaucoma and as preventive treatment in a subject at risk of angle closure.

Nevertheless, even if it is not a surgical procedure, the performance of laser iridotomy is not always a trivial procedure. Some thick irises can be difficult or sometimes even impossible to perforate.

Sometimes iridotomy only permits an incomplete or very partial reopening of the iridocorneal angle, in particular in the case of extensive peripheral anterior synechiae that are not removed by laser iridotomy. The release of pigments, bleeding or post-laser inflammation can even lead to a temporary pressure spike, or even the formation of anterior or posterior synechiae resulting in a definitive increase of IOP.

Lastly, laser iridotomy may speed up the development of a cataract.

Lens extraction

Many recent studies have demonstrated the possibility of proposing lens extraction as an alternative to laser iridotomy for first-line therapy ⁽⁴⁻¹⁰⁾.

This therapeutic option has several benefits. The ablation of a lens that is often voluminous completely removes the pupillary block and results in an angle opening often far greater than after iridotomy alone. The injection of viscoelastic products during the procedure pushes the iris away from the cornea and trabecular meshwork and can break the formation of peripheral anterior synechiae.

The ablation of a lens often presenting a cataract can improve visual acuity.

Lastly, due to advancements in cataract surgical techniques (reduction of the size of incisions, better handling of irrigation flow and pressure in the anterior chamber, etc.), this procedure is now relatively easy to perform, even in the case of a shallow anterior chamber, posterior pressure or risk of corneal edema.

Several large studies have evaluated the benefits and risks of the different management strategies of this form of glaucoma and shown that lens extraction could be a more effective and better tolerated alternative than laser iridotomy for acute forms of angle-closure crisis as well as for chronic forms of angle-closure glaucoma.

The international study Eagle has randomly compared laser iridotomy and lens extraction. All the parameters evaluated (quality of life score, IOP, number of anti-glaucomatous eye drops, percentage of patients without treatment, visual acuity) were in favour of lens extraction.

Therefore, this study supports this therapeutic strategy, particularly in subjects over 50 to 55 year old without accommodation and already presenting lens opacities.

References

1. Aptel F, Denis P. Optical coherence tomography quantitative analysis of iris volume changes after pharmacologic mydriasis. *Ophthalmology*. 2010 Jan; 117(1): 3-10.
2. Lai JS, Liu DT, Tham CC, Li RT, Lam DS. Epidemiology of acute primary angle-closure glaucoma in the Hong Kong Chinese population: prospective study. *Hong Kong Med J*. 2001 Jun; 7(2): 118-23.
3. Kolker AE, Hetherington J, eds. *Becker-Shaffer's Diagnosis and Therapy of the Glaucomas*. 5th ed. St Louis: Mosby; 1983.
4. Lam DS, Leung DY, Tham CC, Li FC, Kwong YY, Chiu TY, Fan DS. Randomized trial of early phacoemulsification versus peripheral iridotomy to prevent intraocular pressure rise after acute primary angle closure. *Ophthalmology*. 2008 Jul; 115(7): 1134-40.
5. Husain R, Gazzard G, Aung T, Chen Y, Padmanabhan V, Oen FT, Seah SK, Hoh ST. Initial management of acute primary angle closure: a randomized trial comparing phacoemulsification with laser peripheral iridotomy. *Ophthalmology*. 2012 Nov; 119(11): 2274-81.
6. Park HY1, Lee NY, Park CK, Kim MS. Long-term changes in endothelial cell counts after early phacoemulsification versus laser peripheral iridotomy using sequential argon:YAG laser technique in acute primary angle closure. *Graefes Arch Clin Exp Ophthalmol*. 2012 Nov; 250(11): 1673-80.
7. Kameda T, Inoue T, Inatani M, Tanihara H; Japanese Phaco-Goniosynechialysis Multicenter Study Group. Long-term efficacy of goniosynechialysis combined with phacoemulsification for primary angle closure. *Graefes Arch Clin Exp Ophthalmol*. 2013 Mar; 251(3): 825-30.
8. Shams PN, Foster PJ. Clinical outcomes after lens extraction for visually significant cataract in eyes with primary angle closure. *J Glaucoma*. 2012 Oct-Nov; 21(8): 545-50.
9. Zhuo YH, Wang M, Li Y, Hao YT, Lin MK, Fang M, Ge J. Phacoemulsification treatment of subjects with acute primary angle closure and chronic primary angle-closure glaucoma. *J Glaucoma*. 2009 Dec; 18(9): 646-51.
10. Lai JS, Tham CC, Lam DS. The efficacy and safety of combined phacoemulsification, intraocular lens implantation, and limited goniosynechialysis, followed by diode laser peripheral iridoplasty, in the treatment of cataract and chronic angle-closure glaucoma. *J Glaucoma*. 2001 Aug; 10(4): 309-15.
11. Teekhasaene C, Ritch R. Combined phacoemulsification and goniosynechialysis for uncontrolled chronic angle-closure glaucoma after acute angle-closure glaucoma. *Ophthalmology*. 1999 Apr; 106(4): 669-74; discussion 674-5.

Answers to the MCQ on page 199

Question 1 : B

Question 2 : C



17

So young

Case report

Young D., 11-year-old, is referred by his ophthalmologist for a decrease in visual acuity of the right eye in a context of very high ocular hypertension.

Ocular hypotensive treatment with prostaglandin analogues was begun immediately after the diagnosis.

The medical history does not reveal any complaint of function apart from the decrease in acuity.

He has no particular personal or family history.

The ophthalmologic examination is as follows:

- VA Right : 20/25 with -0.75D
- VA Left: 20 with -0.50D

Corneal diameter is normal, without edema or corneal abnormality.

The anterior chamber is deep (Figure 1).

Intraocular pressure measured with the Goldmann tonometer is 45 mmHg in both eyes (pachymetry 510 μ m) under hypotonic treatment with prostaglandin analogues for 8 weeks.

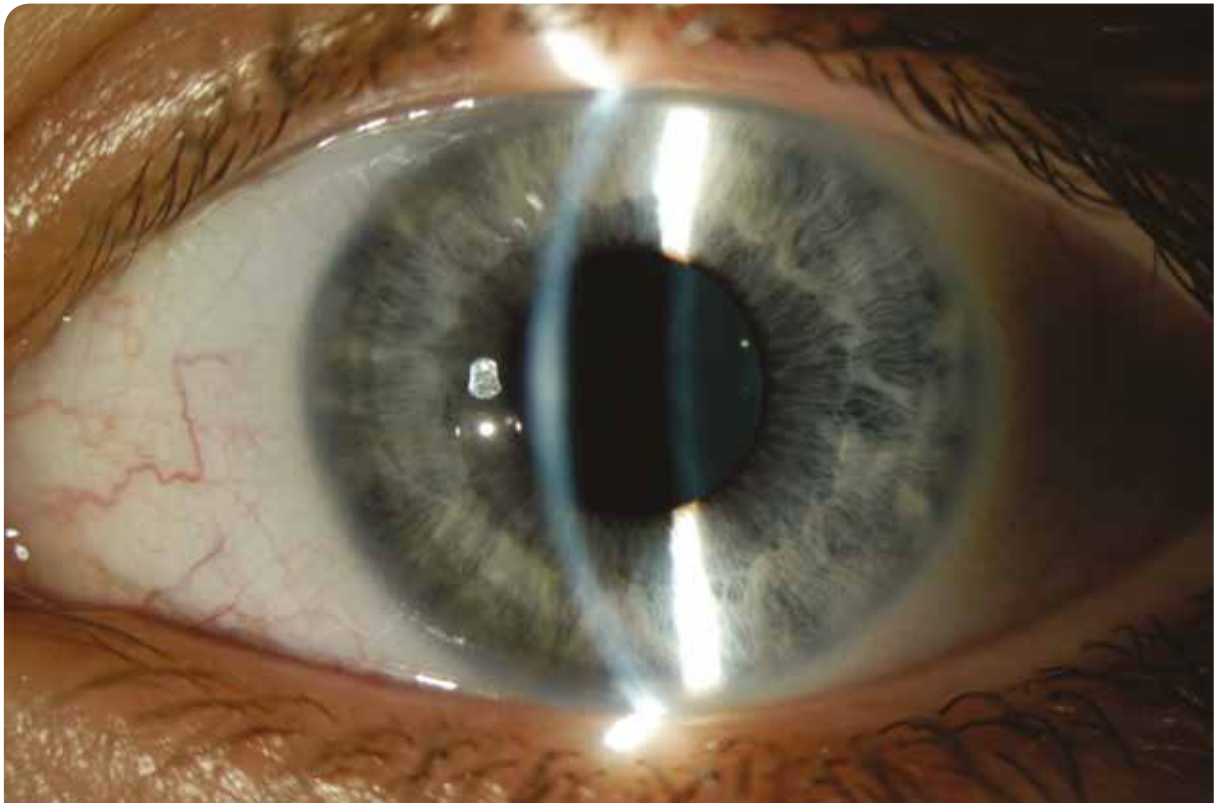


Figure 1: The anterior chamber is deep.

Multiple choice question

What diagnosis do you expect from this ophthalmologic exam?

- A. Congenital glaucoma
- B. Plateau iris glaucoma
- C. Primary juvenile glaucoma
- D. Steroid-induced glaucoma
- E. A bilateral post-traumatic glaucoma

Answer to the MCQ on page 221

Biomicroscopic exam is completed with bilateral gonioscopy.

The angle is wide with bridges of iris tissue that reach the trabecular meshwork (Figure 2).




Figure 2: In gonioscopy voluminous trabecular meshwork and iris (arrows) can be seen.

These anomalies of the iridocorneal angle can be found in both eyes and over 360° (Figure3).




Figure 3: Voluminous inferior bridges in right eye (arrows).

The optical tomography test of the angle shows a very wide angle with a pronounced concave iris. Insertion is unusual with an irido-trabecular bridge corresponding to the large trabeculae seen in gonioscopy (Figure 4).

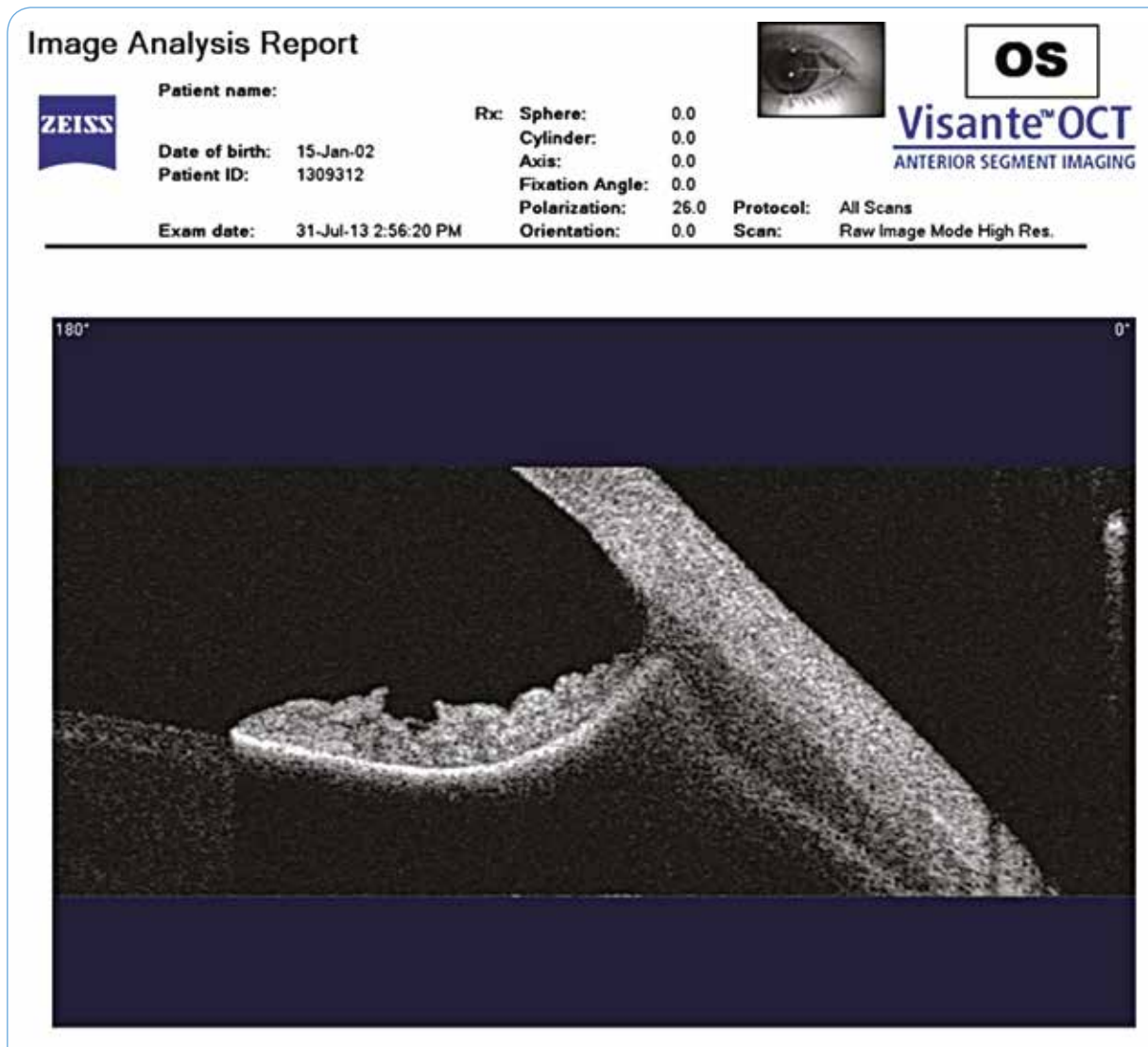

Figure 4: OCT of left eye angle at 3 o'clock.

The exam of the optic discs confirms severe glaucomatous damage (Figures 5 and 6) and unfortunately explains the decrease of visual acuity in the right eye.

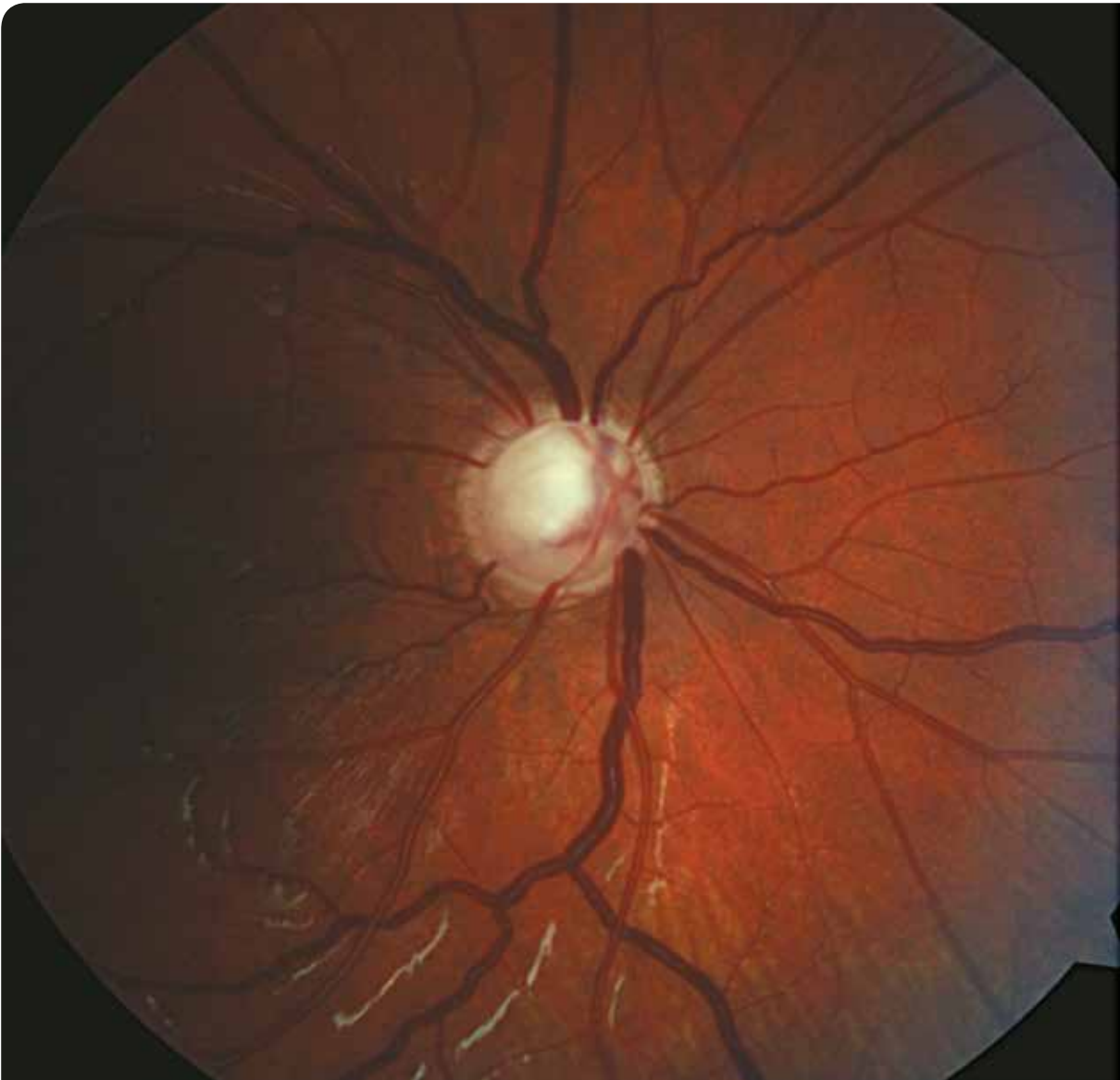


Figure 5: Right optic disc very excavated.

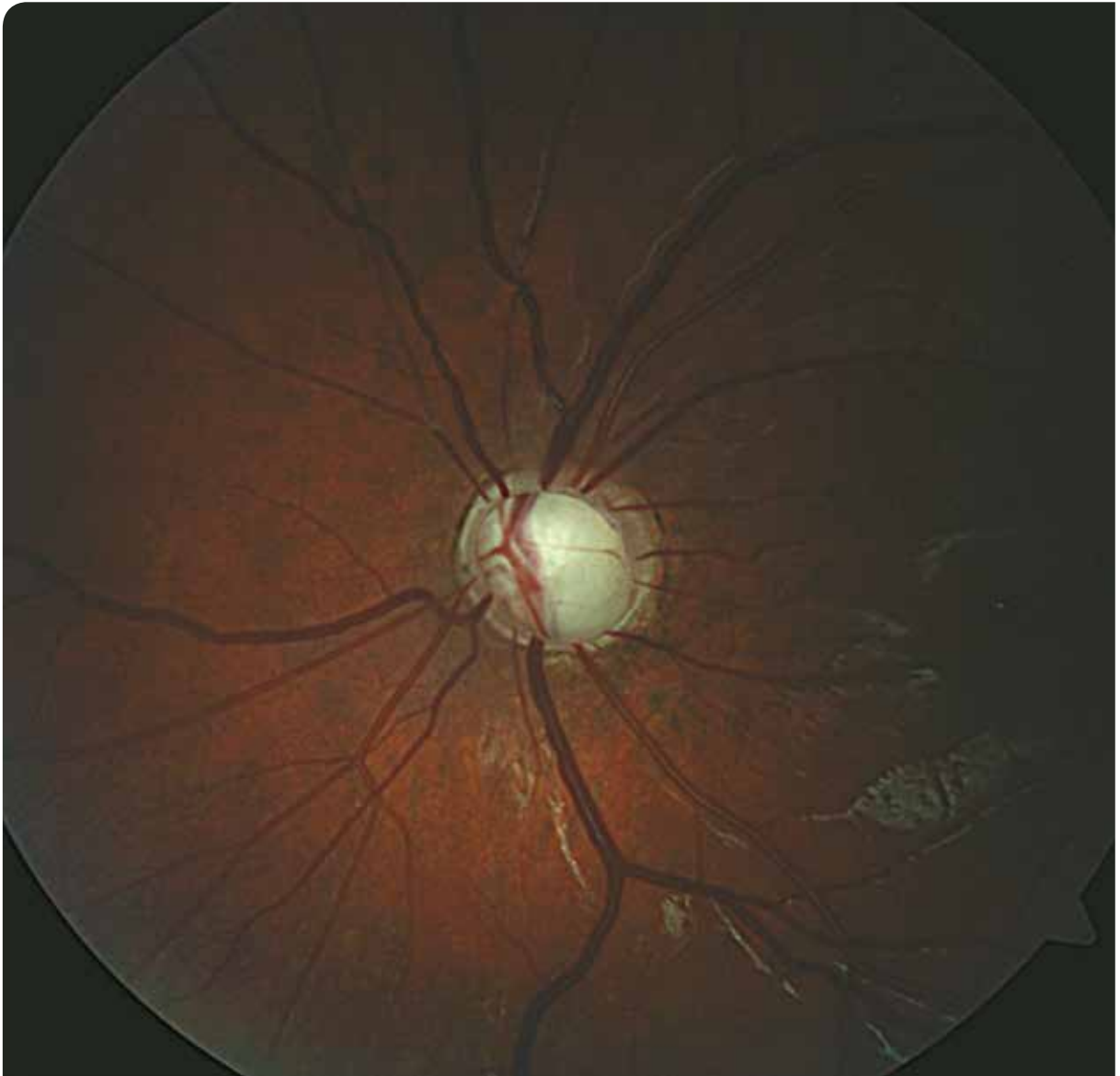

Figure 6: Deeper excavated left optic disc.

Measurements of the visual field are compatible with the structural damage noted in the eye fundus (Figures 7 and 8). Right eye VFI is at 40% with MD of -24 dB with a loss of the central visual field, indicating juvenile glaucoma.

The left visual field has a VFI of 49% and MD of -21 dB and also a loss of the central visual field.

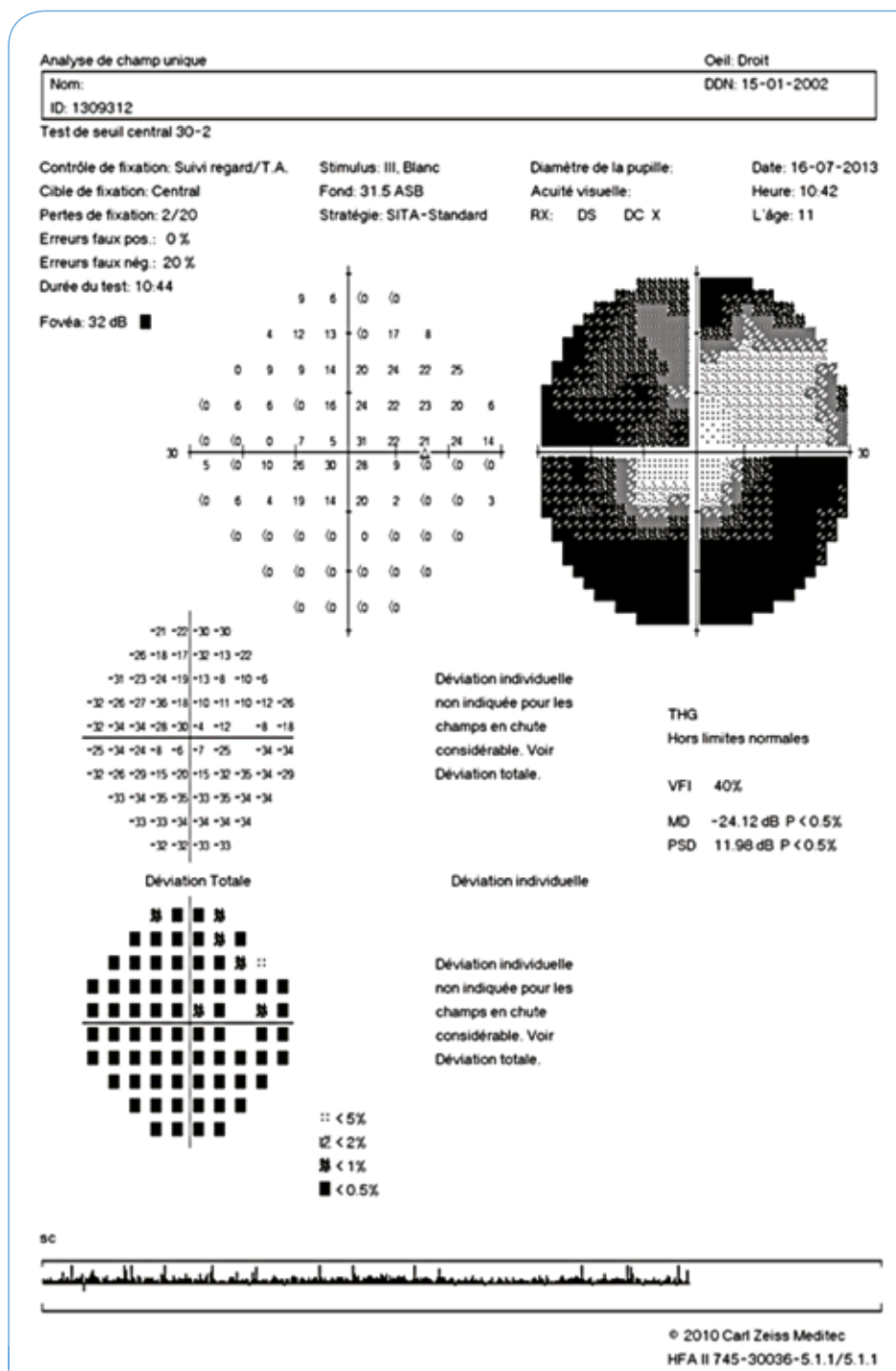


Figure 7: Standard right eye visual field examination.

Analyse de champ unique

Oeil: Gauche





Nom: ID: 1309312

DDN: 15-01-2002

Test de seuil central 30-2

Contrôle de fixation: Suivi regard/T.A. Stimulus: III, Blanc Diamètre de la pupille: Date: 16-07-2013
 Cible de fixation: Central Fond: 31.5 ASB Acuité visuelle: Heure: 10:55
 Pertes de fixation: 4/23 Stratégie: SITA-Standard RX: DS DC X L'âge: 11
 Erreurs faux pos.: 1 %
 Erreurs faux nég.: 0 %
 Durée du test: 11:00

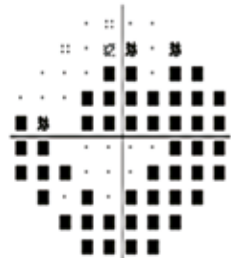

Fovéa: 35 dB ::



THG
 Hors limites normales
 VFI 49%
 MD -20.78 dB P < 0.5%
 PSD 13.72 dB P < 0.5%

Déviaton Totale

Déviaton individuelle



:: < 5%
 □ < 2%
 ■ < 1%
 ■ < 0.5%

sc



© 2010 Carl Zeiss Meditec
 HFA II 745-30036-5.1.1/5.1.1

Figure 8: Standard visual field exam of the left eye.

Ocular evaluation is completed with an exploration of the structure in OCT.

The RNFL exam, despite numerous artefacts shows important bilateral damage of the axonal fibers with a bilateral quasi-disappearance of the neuroretinal border (Figure 9). Note that the discs are large.

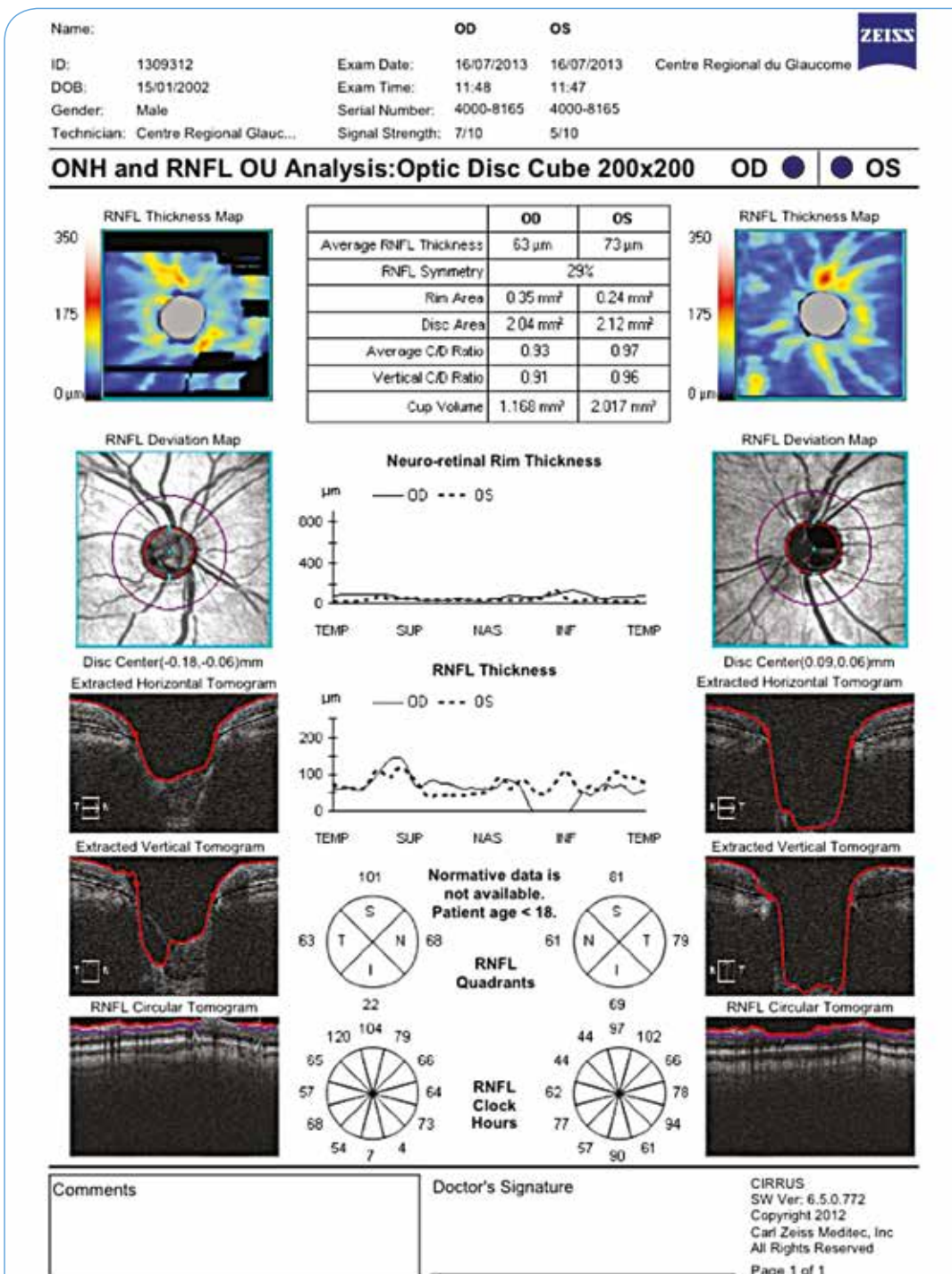


Figure 9: Bilateral RNFL damage.

The exploration of the ganglion cell complex (GCC) is also altered bilaterally (Figure 10).

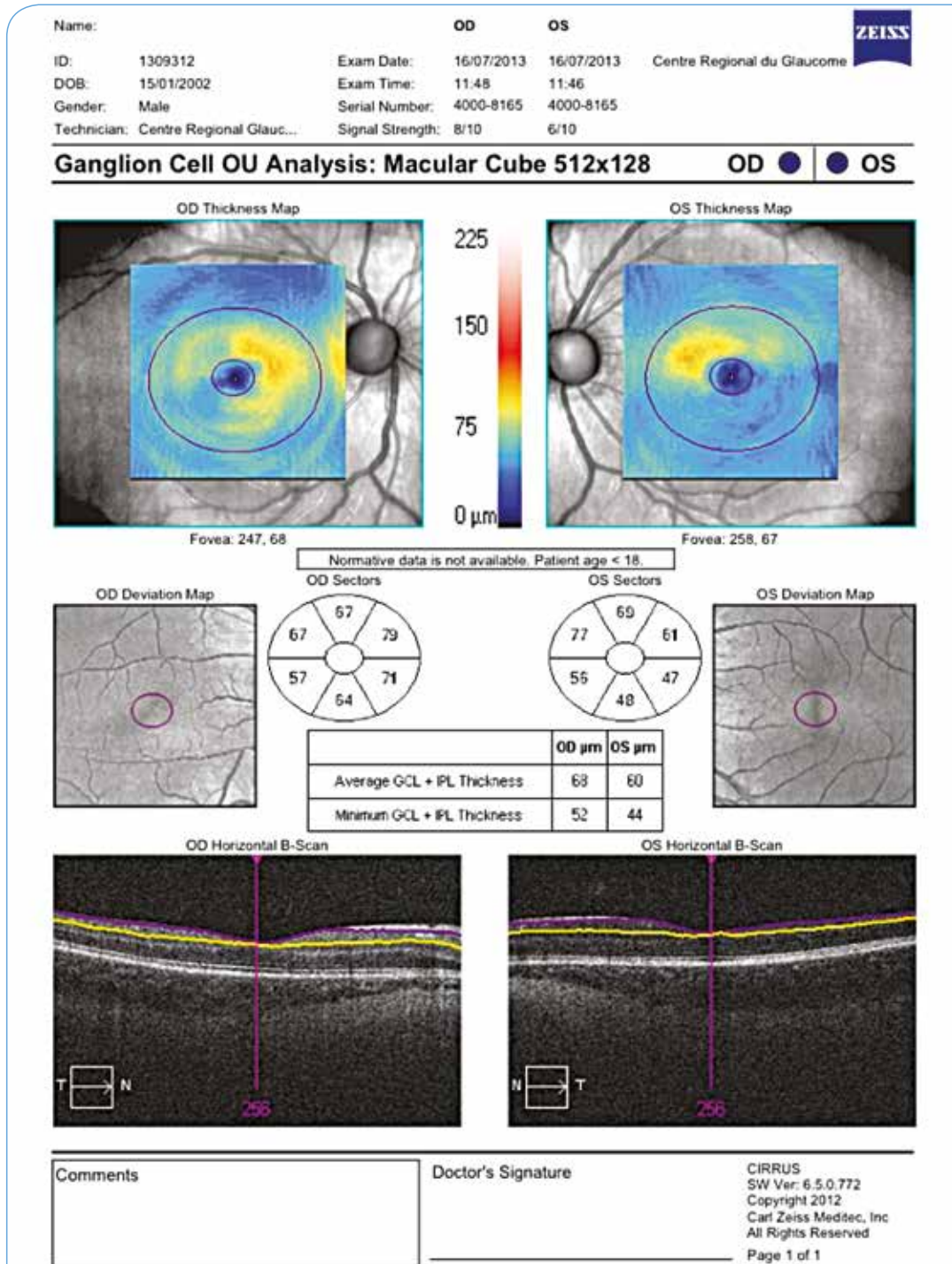


Figure 10: Bilateral GCC damage.

Given the importance of ocular hypertension and its impact in the case of juvenile glaucoma, filtration surgery is proposed to the child and his family.

A trabecular trabeculectomy without amethycine under general anesthesia is performed in the right eye.

Immediate postoperative recovery is normal and intraocular pressure measured on D1 is 6 mmHg without athalamia or choroidal detachment.

The deeply excavated right optic nerve presents microhaemorrhages from decompression and a spectacular regression of its excavation (Figure 11).

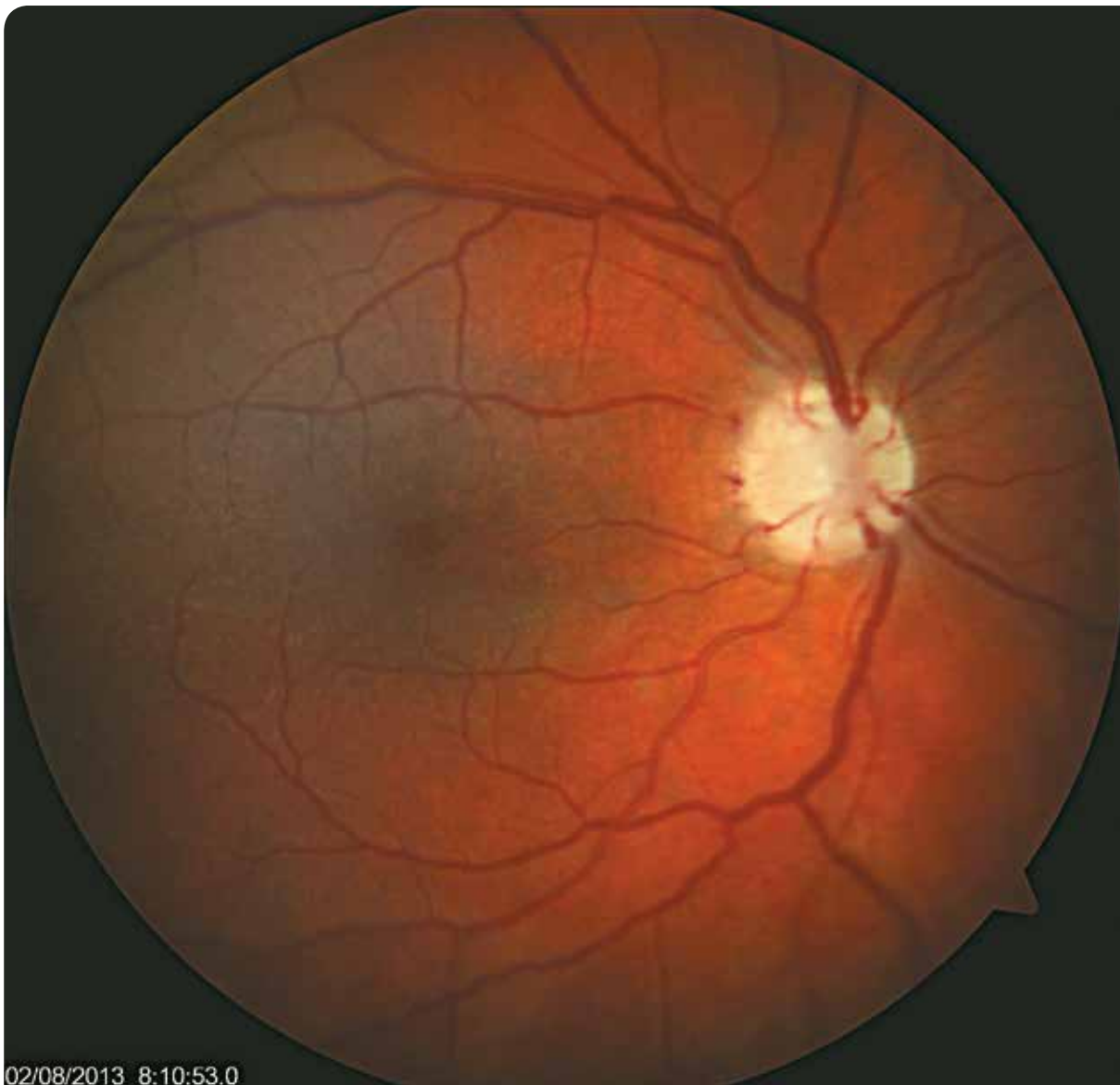


Figure 11: Right optic disc the day after trabeculectomy. Regression of the excavation and small hemorrhages along the papillary fringe. Surgery in the other eye is rapidly scheduled.

Primary juvenile glaucoma (PJG)⁽¹⁻²⁾

This primary open-angle glaucoma has the characteristic of developing in children.

Onset age is between 5 and 18 year for the majority of cases.

It is rare: less than 6% of primary open-angle glaucomas.

It results from an anomaly in the development of the iridocorneal angle, but to a lesser degree than that observed in primary congenital glaucoma.

Family history accounts for the majority of cases that are autosomal dominant with a high penetrance. However, several cases of recessive transmission have been reported, especially in consanguinity cases. There appears to be a 2:1 masculine predominance.

Very often asymptomatic, PJG will be discovered during a routine examination, ophthalmologic exam in a family with PJG or functional manifestations, such as headache and retro- or periocular pain or even decrease of visual acuity.

Therefore, the diagnosis is based, as in adults, on the measurement of intraocular pressure (IOP) that is often very high and its rapidly worsening impact on the optic nerve that is altered very quickly. It is always bilateral but can be asymmetric.

Myopia over 3 diopters is found in 73% of cases of PJG and over 6 diopters in 40%.

The examination of the iridocorneal angle by gonioscopy by the ophthalmologist sometimes finds anatomical anomalies, but the examination can appear normal without ruling out the diagnosis. Goniodysgenesis is sometimes present: very thick processes or iris trabeculae or high insertion (or anterior) of the root of the iris. An immature trabecular meshwork can be found with frosted glass appearance.

This diagnosis will be confirmed by the measurement of the visual field and the examination of the optic nerve like for primary open-angle glaucoma in adults.

Treatment is first and foremost surgery. Medical treatment can be initiated while waiting for surgery or at the post-operative stage given an unachieved target IOP. But it will not stabilize IOP permanently.

Glaucoma surgery in PJG is highly effective: in 80% of cases (with or without adjunctive medical treatment) whatever the technique used; trabeculotomy, trabeculectomy, goniotomy or even viscocanalostomy; intraocular pressure is controlled permanently.

These excellent pressure results obtained by filtration surgery are a particular characteristic of this juvenile form of primary open-angle glaucoma.

References

1. Rouland JF : Le Glaucome juvénile : in Glaucome Primitif à Angle Ouvert Rapport SFO 2014 Elsevier Masson 424-426.
2. Wong CY, Wen JC, Aref AA, Feng S : Juvenile open angle glaucoma. EyeWiki .org Juin 2018.

Answer to the MCQ on page 209: C

Collection Librairie Médicale Théa



Laboratoires Théa
12, rue Louis Blériot
63000 Clermont-Ferrand
Tel: +33 4 73 981 436